

# KARDİYOYASKÜLER AKADEMİ KONGRESİ

&

## INTERNATIONAL ACADEMY OF YOUNG CARDIOLOGISTS

Elexus Hotel Girne, K.K.T.C.

18-22 Eylül 2024

[www.kvakkongre.org](http://www.kvakkongre.org)



GENH  
KONGRE



# KARDİYOVASKÜLER AKADEMİ KONGRESİ

## & INTERNATIONAL ACADEMY OF YOUNG CARDIOLOGISTS

Elexus Hotel Girne, K.K.T.C.

18-22 Eylül 2024

### KURULLAR

**Kardiyovasküler Akademi Derneği Başkanı**

Prof. Dr. Ömer Kozan

**KVAK 2024 Kongre Başkanı**

Prof. Dr. Öner Özdoğan

**Kongre Bilim Kurulu Başkanları**

Prof. Dr. Mehdi Zoghi

Prof. Dr. Öner Özdoğan

**IAYC Kongre Başkanı**

Prof. Dr. Berkay Ekici

**KVAK 2024 Bilim Kurulu**

Prof. Dr. Rezzan Deniz Acar  
Prof. Dr. Ömer Akyürek  
Prof. Dr. İbrahim Altun  
Prof. Dr. Özlem Arıcan Özlük  
Doç. Dr. Beytullah Çakal  
Doç. Dr. Sinem Çakal  
Prof. Dr. Mesut Demir  
Prof. Dr. Berkay Ekici  
Prof. Dr. Oktay Ergene  
Prof. Dr. Bülent Görenek  
Uzm. Dr. Sefa Gül  
Doç. Dr. Tuncay Güzel

Prof. Dr. Nihan Kahya Eren  
Prof. Dr. Tarık Kıvrak  
Prof. Dr. Ömer Kozan  
Doç. Dr. Tolga Onuk  
Prof. Dr. Öner Özdoğan  
Prof. Dr. Selvi Öztaş  
Prof. Dr. Raşit Sayın  
Prof. Dr. Nihan Turhan Çağlar  
Prof. Dr. Pınar Türker Duyuler  
Doç. Dr. Barış Yaylak  
Prof. Dr. Mehdi Zoghi

\*Alfabetik olarak sıralanmıştır.

Ege Üniversitesi, Kardiyoloji ABD  
35100 Bornova / İzmir / Türkiye  
T: +90 232 - 39040001-5458

## KVAD YÖNETİM KURULU

### Başkan

Prof. Dr. Ömer Kozan

### Danışman Üyeler

Prof. Dr. A. Oktay Ergene  
Prof. Dr. Mesut Demir

### Başkan Yardımcıları

Prof. Dr. Bülent Görenek  
Prof. Dr. Berkay Ekici

### Genel Sekreter

Prof. Dr. Mehdi Zoghi

### Genel Sekreter Yardımcıları

Prof. Dr. Raşit Sayın  
Prof. Dr. Öner Özdoğan

### Veznedar

Prof. Dr. Nihan Turhan Çağlar

### Üyeler

Prof. Dr. Pınar Türker Duyuler  
Doç. Doç. Dr. Sinem Çakal  
Doç. Dr. Tuncay Güzel  
Uzm. Dr. Sefa Gül

### KVAK 2024 KONGRE BAŞKANI

Prof. Dr. Öner Özdoğan

### KONGRE BİLİM KURULU

#### BAŞKANLARI

Prof. Dr. Mehdi Zoghi  
Prof. Dr. Öner Özdoğan

### Kongre Düzenleme Kurulu

Prof. Dr. Rezzan Deniz Acar  
Prof. Dr. Ömer Akyürek  
Prof. Dr. İbrahim Altun  
Prof. Dr. Özlem Arıcan Özlük  
Doç. Dr. Beytullah Çakal  
Doç. Dr. Sinem Çakal  
Prof. Dr. Mesut Demir  
Prof. Dr. Berkay Ekici  
Prof. Dr. Oktay Ergene  
Prof. Dr. Bülent Görenek  
Uzm. Dr. Sefa Gül  
Doç. Dr. Tuncay Güzel  
Prof. Dr. Nihan Kahya Eren  
Prof. Dr. Tarık Kıvrak  
Prof. Dr. Ömer Kozan  
Doç. Dr. Tolga Onuk  
Prof. Dr. Öner Özdoğan  
Prof. Dr. Selvi Öztaş  
Prof. Dr. Raşit Sayın  
Prof. Dr. Nihan Turhan Çağlar  
Prof. Dr. Pınar Türker Duyuler  
Doç. Dr. Barış Yaylak  
Prof. Dr. Mehdi Zoghi

Prof. Dr. Ömer Kozan

Başkan



KARDİYOVASKÜLER  
AKADEMİ DERNEĞİ  
Kütük No: 30 - 046 - 064



# KARDİYOVASKÜLER AKADEMİ KONGRESİ

&

## INTERNATIONAL ACADEMY OF YOUNG CARDIOLOGISTS

Elexus Hotel Girne, K.K.T.C.

18-22 Eylül 2024



www.kvakkongre.org

### BİLİMSEL PROGRAM



# KARDİYOVASKÜLER AKADEMİ KONGRESİ

## & INTERNATIONAL ACADEMY OF YOUNG CARDIOLOGISTS

Elexus Hotel Girne, K.K.T.C.

18-22 Eylül 2024

18 EYLÜL 2024, Çarşamba

### Prof. Dr. VEDAT SANSOY Salonu

15:00-15:45 KURS-1

Eğitici Olgularla TEE

*Konuşmacı: Rezzan Deniz Acar*

15:45-16:45

**Kardiyak resenkronizasyon tedavisinde son gelişmeler**

*Oturum Başkanları: Aysen Ağaçdiken Ağır, Uğur Canpolat*

*Panelistler: Cengiz Şabanoglu, Emir Baskovski, Tuncay Güzel, Gurbet Özge Mert*

Kimlere biventriküler KRT, Tuncay Güzel

Kimlere sol dal pacing KRT, Gurbet Özge Mert

Kimlere sol dal optimize KRT, Emir Baskovski

16:45-17:30

**AÇILIŞ OTURUMU**

# KARDİYOVASKÜLER AKADEMİ KONGRESİ

## & INTERNATIONAL ACADEMY OF YOUNG CARDIOLOGISTS

Elexus Hotel Girne, K.K.T.C.

18-22 Eylül 2024

19 EYLÜL 2024, Perşembe

### Prof. Dr. VEDAT SANSOY Salonu

08:00-08:30

#### KURS-2

Eğitici Olgularla Kardiyak MR

**Konuşmacı:** İbrahim Altun

08:30-09:30

#### Kardiyo-onkoloji

**Oturum Başkanları:** Cafer Zorkun, Oğuzhan Çelik

**Panelistler:** Şahin Topuz, Serkan Asil, Fatih Kızkapan

Kemoterapi alan kardiyak ve non-kardiyak hastalarda takipte nelere dikkat etmeliyim? Dilek Cahide Haznedar Kırıcı

Radyoterapi alan kardiyak ve non-kardiyak hastalarda takipte nelere dikkat etmeliyim? Gülay Uzun

Kanser hastalarında primer ve sekonder korumada antiagregan-antikoagülan tedavide dikkat etmem gereken

durumlar nelerdir? Murat Gökhan Yerlikaya

09:30-10:00

#### KAHVE ARASI

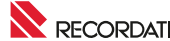10:00-10:30

#### UYDU SEMPOZYUM

**Kardiyovasküler Korumada 2 Etkin Güç: Pitavastatin ve Kolşisin**

**Moderatör:** Oktay Ergene

**Konuşmacılar:** Öner Özdoğan, Berkay Ekici



10:30-11:30

**Akut Koroner Sendrom sonrası DAPT Tedavisinde hangi ajan ne kadar süreyle: Kafalarımız hala karışık mı?**

**Oturum Başkanları:** Turgut Karabağ, Cenk Sarı

**Panelistler:** Murat Samsa, Mehmet Fatih Yılmaz, Ceyhan Yücel, Oğuzhan Birdal

Girişimsel tedavi yaptığım hastamda DAPT, Bahadır Kırılmaz

Medikal Tedavi ile takip kararı verdiğim hastamda DAPT, Mustafa Sarı

De-eskalasyon yaptığım hastalarımda DAPT, Mehmet Altunova

11:30-12:00

#### UYDU SEMPOZYUM

**HEDEFE GİDEN YENİ BİR YOL BULUNDU!**

**Hiperlipidemi tedavisinde güncel hedef değerler ve kombine tedavinin önemi nedir?**

**Hedef değerlere ulaşmanın kolay yolu "Ezetec Plus"**

**Moderatör:** Oktay Ergene

**Konuşmacılar:** Mehdi Zoghi, Ayşe Çolak



12:00-12:30

#### KAHVE ARASI

# KARDİYOVASKÜLER AKADEMİ KONGRESİ

## & INTERNATIONAL ACADEMY OF YOUNG CARDIOLOGISTS

Elexus Hotel Girne, K.K.T.C.

18-22 Eylül 2024

19 EYLÜL 2024, Perşembe

12:30-13:30 Avrupa Kardioloji Derneği 2024 Kılavuzlarının ve Pratiğimize yön verecek klinik araştırma özetleri

**Oturum Başkanları:** Pınar Türker Duyuler, Raşit Sayın

**Panelistler:** Mustafa Öztürk, Selim Kul, Halil İbrahim Biter, Hakkı Kaya

Kronik Koroner Sendrom, Ekrem Şahan

Atriyal Fibrilasyon, Saadet Aydın

Periferik arter ve Aort hastalıkları, Süleyman Kalaycı

Hotline seçmeleri, Nedret Ülvan

13:30-14:30 ÖĞLE YEMEĞİ

14:30-15:00 UYDU SEMPOZYUM

Jardiance ile Bütüncül & Güçlü Koruma

Kardiyovasküler hastalık yönetimde kardiyorenal koruma için bütüncül bakış açısı ve

Jardiance Empareg Sonuçları

**Konuşmacı:** Rezzan Deniz Acar

EF'den bağımsız KY tedavisinde Jardiance ile bütüncül koruma

**Konuşmacı:** Hakan Altay

Soru-Cevap



15:00-15:30 KAHVE ARASI

15:30-16:30 SALON KONUŞSUN-1

Gebe kalp hastasının yönetimi (Olgu örnekleri ile)

**Oturum Başkanları:** Çetin Erol, Özlem Arıcan

**Olgu örnekleri:** Ahmet Özdeyrya

# KARDİYOVASKÜLER AKADEMİ KONGRESİ

## & INTERNATIONAL ACADEMY OF YOUNG CARDIOLOGISTS

Elexus Hotel Girne, K.K.T.C.

18-22 Eylül 2024

20 EYLÜL 2024, Cuma

### Prof. Dr. VEDAT SANSOY Salonu

08:00-08:30

**KURS 3**

**Sol Dal Pacing KRT**

**Moderatör:** Ahmet Vural

**Konuşmacı:** Muhammet Dural, Burak Hünük

08:30-09:30

**İskemik inmeye kardiyak yaklaşım**

**Oturum Başkanları:** Levent Şahiner, Erdal Belen

**Panelistler:** Belma Kalaycı, Gürkan İş, Mehmet Kaplan, Faruk Aktürk

İskemik inmeli hastayı kardiyak açıdan nasıl değerlendirelim? Ayça Gümüşdağ

İskemik inmeli hastada PFO saptadık, kapatalım mı? Sinem Çakal

Sol atriyal apendiks kapatılması (Sol atriyal apendiks değerlendirme, LAA ka-patma endikasyonları ve işlemin teknik detayları) Ersan Oflar

09:30-10:00

**KAHVE ARASI**

10:00-10:30

**UYDU SEMPOZYUM**

**PKG'de Hız ve Güvenin Kesişim Noktası: Kangrelor**

**Moderatör:** Oktay Ergene

**Konuşmacı:** Öner Özdoğan

 **Chiesi**

10:30-11:30

**(KVAK & IAYC joint session)**

**Revisiting Chronic Heart Failure**

**Oturum Başkanları:** Oktay Ergene, Larisa Dizdarevic

Fantastic 5: Ablation in heart failure patients with atrial fibrillation, Lorenzo Constantini

Interventional new devices for HF patients, Arash Hashemi

11:30-12:00

**UYDU SEMPOZYUM**

**Repatha ile dislipidemi tedavisi: kardiyovasküler olay riskini azaltın!**

**Moderatör:** Lale Tokgözoğlu

**Kılavuzlar eşliğinde PCSK9i tedavisi**

**Konuşmacı:** Meral Kayıkçıoğlu

 **AMGEN**

12:00-12:30

**KAHVE ARASI**



# KARDİYOVASKÜLER AKADEMİ KONGRESİ

## & INTERNATIONAL ACADEMY OF YOUNG CARDIOLOGISTS

Elexus Hotel Girne, K.K.T.C.

18-22 Eylül 2024

20 EYLÜL 2024, Cuma

12:30-13:30

**Aterosklerotik plak: Güncel kavramlar ve gelecek perspektif**

**Oturum Başkanları:** Lale Tokgözoğlu, Öner Özdoğan

**Panelistler:** Emrah Erdoğan, Fatih Aytemiz, Çağlar Emre Çağlıyan, Zeynep Kumral, Halenur Sarbaş

Hassas plak tanımında değişen kavramlar, Öner Özdoğan

Primer ve sekonder KV koruma çalışmalarında plak görüntülenmesinin yeri, Özcan Başaran

Aterosklerotik plağın sistemik tedavisi: LDL kolesterol düşürücü tedavi ve ötesi, Barış Güngör

13:30-14:30

**ÖĞLE YEMEĞİ**

14:30-15:00

**UYDU SEMPOZYUM**

**Hipertansiyon Tedaavisine Güç Katacak KKB: Benitide**

**Moderatör:** Oktay Ergene

**Konuşmacılar:** Ülver Derici, Berkay Ekici



**ABDİİBRAHİM**

15:00-15:30

**KAHVE ARASI**

15:30-16:30

**KARŞIT GÖRÜŞ**

**İnstant Restenoza Yaklaşım**

**Oturum Başkanları:** Barış Kılıçaslan, Ceyhan Ceyhan

**Panelistler:** Emrah Erdoğan, Hilal Erken, İsmail Gürbak, Kürşat Akbuğa, Elnur Alizade

İlaç kaplı Balon tercih edilmelidir, Serkan Duyuler

Debulking ve DES tercih edilmelidir, Ahmet Güner

# KARDİYOVASKÜLER AKADEMİ KONGRESİ

## & INTERNATIONAL ACADEMY OF YOUNG CARDIOLOGISTS

Elexus Hotel Girne, K.K.T.C.

18-22 Eylül 2024

21 EYLÜL 2024, *Cumartesi*

### Prof. Dr. VEDAT SANSOY Salonu

08:00-08:30 KURS-4

**Karotis stentleme**

**Moderatör:** Ömer Kozan, Ahmet Arif Yalçın

**Konuşmacı:** Turhan Turan

08:30-09:30 **Yapısal Kalp Kapak Hastalıklarında Transkateter Girişimler**

**Oturum Başkanı:** Mehmet Vefik Yazıcıoğlu, Can Yücel Karabay

**Panelistler:** Sinan İnci, İlker Avcı, Yunus Çalapkulu, Gönül Zeren, Hüseyin Ayhan

Aort Kapak Girişimleri, Veysel Özgür Barış

Mitral Kapak Girişimleri, Regayip Zehir

Sağ Kalp Kapak Hastalıklarında Girişimsel Tedavi, Beytullah Çakal

09:30-10:00 **KAHVE ARASI**

10:00-10:30 **UYDU SEMPOZYUM**

**DEF-KY kılavuzlarında güncellemeler: RAAS blokajında ilk seçenek ARNI**

**Oktay Ergene, Berkay Ekici**

**aris**  
ali raif ilaç sanayi

10:30-11:30 **Vakalarla komplikasyonlar oturumu**

**Oturum Başkanları:** Ömer Kozan, İbrahim Halil Kurt

**Panelistler:** Muhammed Cihat Çelik, Ali Kemal Çabuk, Sefa Gül, Mehmet Kış

PKG esnasında gelişen aortkoroner diseksiyon, Ziya Apaydın

Koroner rüptür vakası, Sefa Gül

Stent Sıyılması vakası, Mehmet Kış

TAVI esnasında gelişen koroner oklüzyon vakası, Ersin İbişoğlu

Longitudinal stent deformasyonu (Akordiyon), Orhan Karayığit

Guidewire kopması, Murat Gök

Rotablator sıkışması (entrapment), Ali Kemal Çabuk

11:30-12:00 **UYDU SEMPOZYUM**

**Güncel verilerle ATTR-KM ve Tafamidis tedavisi**

**Moderatör:** Mehdi Zoghi

**Konuşmacılar:** Rezzan Deniz Acar, Işık Tekin

**Pfizer**

12:00-12:15 **KAHVE ARASI**

# KARDİYOVASKÜLER AKADEMİ KONGRESİ

## & INTERNATIONAL ACADEMY OF YOUNG CARDIOLOGISTS

Elexus Hotel Girne, K.K.T.C.

18-22 Eylül 2024

21 EYLÜL 2024, *Cumartesi*

12:15-12:45

### UYDU SEMPOZYUM

**Kronik Koroner Sendromların Tedavisinde Ranolazinin Yeri ve Türkiye Tercihleri: Anjina-TR Sonuçları**

**Konuşmacılar:** Mehdi Zoghi, Abdullah Arslan



12:45-13:45

### (KVAK & IAYC joint session)

#### Advanced Heart Failure

**Chairpersons:** Berkay Ekici, Ahmet Karagöz

Updated definition and prognostic stratification, İlah Aghaeva

Management of Obstructive Sleep Apnea, Ahmed Mascdi

Mechanical circulatory support devices, Arash Hashemi

13:45-14:30

### ÖĞLE YEMEĞİ

14:30-15:30

### UZLAŞI RAPORU

**Diüretik Dirençli Kalp Yetersizliği Hastalarında Ultrafiltrasyon Tedavisi: Kardiyovasküler Akademi Derneği ve Türk Hipertansiyon ve Böbrek Hastalıkları Derneği'nin Uzlaşma Raporu**

**Oturum Başkanları:** Ömer Kozan, Yunus Erdem

**Konuşmacılar:** Tolga Yıldırım, Mehdi Zoghi

15:30-15:45

### KAHVE ARASI

15:45-16:15

### SALON KONUŞSUN-2

**ACC/AHA AF kılavuzunun olgu örnekleri ile tartışılması**

**Moderatör:** Dursun Aras, Mesut Demir

**Olgu Örnekleri:** Semi Öztürk

# KARDİYOVASKÜLER AKADEMİ KONGRESİ

## & INTERNATIONAL ACADEMY OF YOUNG CARDIOLOGISTS

Elexus Hotel Girne, K.K.T.C.

18-22 Eylül 2024

22 EYLÜL 2024, Pazar

### Prof. Dr. VEDAT SANSOY Salonu

09:00-09:45

**Diyabette kardiyovasküler komplikasyonların önlenmesi, tanı ve tedavisi**

**Oturum Başkanları:** Rahmi Yılmaz, Nihan Turhan Çağlar

**Panelistler:** Önder Öztürk

Asemptomatik diyabetik hastalarda makrovasküler komplikasyonları nasıl tarayalım? Selvi Öztaş

Diyabetik hastalarda ek kardiyovasküler risk faktörlerinin değerlendirilmesi ve yönetimi

(Hipertansiyon, dislipidemi) Yunus Emre Özbebek

Diyabet kardiyovasküler hastalık risk eş değeri midir? Diyabette hızlanmış ateroskleroz, Hatice Solmaz

09:45-10:00

**KAHVE ARASI**

10:00-10:45

**Zorlu İkili: Tedavi Yönetimi Nasıl olmalı?**

**Oturum Başkanları:** Aylin Yıldırım, Nihan Kahya Eren

**Panelistler:** Suzan Şahan, Abdurrahman Oğuzhan, Hacı Ali Kürklü

Koroner Arter Hastalığı ve Aort Darlığı Birlikteliği, Sefa Gül

HCM ve AF, Ömer Akyürek

DEFKY ve KBY, Ayşe Çolak

10:45-11:00

**KAHVE ARASI**

11:00-11:45

**2024 de yayınlanan günlük pratiğimizi etkileyen en önemli 3 çalışma**

**Oturum Başkanları:** Murat Sucu

**Panelistler:** Mert Evlice, Veyysel Ozan Tanık

Kardiyovasküler hastalıklarla ilgili 2024'de yayımlanan en önemli 3 çalışma, Serkan Karahan

Kalp kapak hastalıklarıyla ilgili 2024'de yayımlanan en önemli 3 çalışma, Hicaz Zencirkıran Ağuş

Kalp yetersizliğiyle ilgili 2024'de yayımlanan en önemli 3 çalışma, Selçuk Öztürk

11:45-12:30

**AKILCI İLAÇ OTURUMU**

**Oturum Başkanı:** Ömer Kuru

12:30-13:00

**KAPANIŞ OTURUMU**

# CARDIOVASCULAR ACADEMY CONGRESS

## & INTERNATIONAL ACADEMY OF YOUNG CARDIOLOGISTS

Elexus Hotel Kyrenia, North Cyprus  
18-22 September 2024



[www.kvakkongre.org](http://www.kvakkongre.org)

## SCIENTIFIC PROGRAM





# CARDIOVASCULAR ACADEMY CONGRESS

## & INTERNATIONAL ACADEMY OF YOUNG CARDIOLOGISTS

Elexus Hotel Kyrenia, North Cyprus

18–22 September 2024

19 SEPTEMBER 2024, Thursday

Prof. Dr. ALAIN CRIBIER Hall

### 09:00-09:30 Congress Opening Speeches

Ömer Kozan (President of CVA Association)  
Mehdi Zoghi (General Secretary)  
Berkay Ekici (Congress President)  
Sinem Çakal (IAYC Coordinator)  
Arash Hashemi (Scientific Program President)

### 09:30-10:45 Abstract Session 1

**Chairpersons:** Selçuk Öztürk, İlah Aghaeva

- OP-01** A case of acute coronary syndrome due to unnecessary use of non-steroidal anti-inflammatory drugs  
*Betül Balaban Koças, Gökhan Çetinkal, Tuğçe Kaya*
- OP-02** Coronary Perforation and Its Management  
*Ali Yaşar Kılınç, Mehmet Kara, Mustafa Sarı*
- OP-03** Clinical And Demographic Characteristics Of Patients With Acute Coronary Syndromes According To Presentation Type  
*Ömer Işık, Mete Kağan Polat, Elton Soydan, Berkay Ekici, Mehdi Zoghi, Nedret Ülvan*
- OP-04** Prognosis and Mortality in Patients with Group 1 and Group 4 Pulmonary Hypertension  
*Saadet Aydın*
- OP-05** Possible Differences in Neutrophil/Lymphocyte Ratio, Echocardiography, and Catheterization Parameters in Patients with Group 1 and Group 4 Pulmonary Hypertension  
*Saadet Aydın*
- OP-06** Evaluation of Triglyceride-glucose Index in Three Generation Beta-adrenoceptor Blockers  
*Demet Erciyes*
- OP-07** jail tail fracture and longitudinal stent deformation associated with deep catheter engagement during left main stem stenting  
*Betül Balaban Koças, Gökhan Çetinkal, Süleyman Atalay*
- OP-08** To evaluate left ventricular function with strain echocardiography in patients with or without treatment with a diagnosis of coronary slow flow  
*Saadet Aydın, Ecem Gurses*

10:45-11:00 COFFEE BREAK / E-Poster Presentation / PP-01 – PP-03

# CARDIOVASCULAR ACADEMY CONGRESS

## & INTERNATIONAL ACADEMY OF YOUNG CARDIOLOGISTS

Elexus Hotel Kyrenia, North Cyprus

18-22 September 2024

19 SEPTEMBER 2024, *Thursday*

Prof. Dr. ALAIN CRIBIER Hall

11:00-12:15 **Abstract Session 2**

**Chairpersons:** *Sinem Çakal*

- OP-09** High Osaka Prognostic Score Is Associated With Increased Thrombus Burden In Patients With ST Elevation Myocardial Infarction  
*Nail Burak Özbeyaz, Engin Algül, Haluk Furkan Şahan, Gürkan Iş, Gürkan Iş*
- OP-10** A case of infective endocarditis presenting with coronary embolism  
*Fatma Esin, Gökhan Akkan, Bahadır Akar, Uğur Kocabaş, Bahadır Akar*
- OP-11** Usability of Neutrophil Percentage to Albumin Ratio in Predicting New Onset Atrial Fibrillation in ST Elevation Myocardial Infarction Patients  
*Ahmet Özderya, Yahya Dağcan Bıçakçı, Muhammet Raşit Sayın, Yahya Dağcan Bıçakçı*
- OP-12** The Relationship Between Echocardiographically Determined Systolic Pulmonary Arterial Pressure and Blood Lipid Levels  
*Hafize Corut Güzel, Nedret Ülvan*
- OP-15** Association Between Uric Acid Albumin Ratio in Cardiac Patients Undergoing Cardiac Rehabilitation  
*Nazmiye Ozbilgin, Basak Bilir Kaya, Koray Kalenderoglu*
- OP-16** Predictive capability of modified Bedside shock index in patients with ST segment elevation myocardial infarction  
*Bektaş Murat, Fatih Enes Durmaz, Fatih Aydın, Selda Murat, Cihat Çalışkan*

12:15-14:00 **LUNCH**

# CARDIOVASCULAR ACADEMY CONGRESS

## & INTERNATIONAL ACADEMY OF YOUNG CARDIOLOGISTS

Elexus Hotel Kyrenia, North Cyprus

18–22 September 2024

19 SEPTEMBER 2024, *Thursday*

Prof. Dr. ALAIN CRIBIER Hall

14:00-15:15 **Abstract Session 3**

**Chairpersons:** *M. Raşit Sayın*

- OP-17** Coronary Slow Flow is Associated with Anxiety and Depression but not Adverse Childhood Experiences and Alexithymia  
*Hayriye Mihrimah Ozturk, Ibrahim Halil Inanç, Mehmet Cilingiroglu, Yasar Turan, Huseyin Kandemir, Selçuk Ozturk*
- OP-18** Importance of the Triglyceride High-Density Lipoprotein Ratio for Assessing Multivessel Disease in Hypertensive Patients Undergoing Coronary Computed Tomographic Angiography  
*Oğuzhan Birdal, Ferih Özcanlı, Sıdar Şiyar Aydın*
- OP-19** Floating stent in the aorta, thought to be jailed after being stripped  
*Mustafa Karakurt, Selçuk Öztürk, Hüseyin Kandemir*
- OP-20** The Role of New Inflammatory Markers in Determining The Development of Contrast-Induced Nephropathy in Patients Undergoing Percutaneous Coronary Angiography Due to STEMI  
*Zeki Çetinkaya*
- OP-21** Investigation of Serum Raftlin (RFTN1) Level in Disseminated Coronary Artery Disease  
*Ünal Öztürk, Ali Eren Onuş*
- OP-22** Treatment of Persistent Thrombus with Stent-Retriever Thrombectomy in Acute Myocardial Infarction: A Case Report  
*Aylin Şafak Arslanhan, Halil Ibrahim Kardaş, Abdullah Orçun Öner, Umut Baran Yılmaz*
- OP-23** The Role of Systemic Inflammation Response Index (SIRI) in Predicting Stent Restenosis  
*Orhan Karayigit*
- OP-24** Long-Term Results in Patients Operated Due to Cardiac Mass: Tertiary Center Experience  
*Samet Sevinc, Mehmet Altunova*

15:15-15:30 **COFFEE BREAK / E-Poster Presentation / PP-04 – PP-06**

# CARDIOVASCULAR ACADEMY CONGRESS

## & INTERNATIONAL ACADEMY OF YOUNG CARDIOLOGISTS

Elexus Hotel Kyrenia, North Cyprus

18-22 September 2024

19 SEPTEMBER 2024, *Thursday*

Prof. Dr. ALAIN CRIBIER Hall

15:30-16:15 **Abstract Session 4**

**Chairpersons:** *Pınar Türker Duyuler*

- OP-25** The Effect of the Demographic and Clinical Characteristics of the Patients with Supraventricular Tachycardia on the Procedure Times in the Electrophysiology Study  
*Osman Can Yontar, Rustem Yilmaz*
- OP-26** Diagnostic accuracy of computed tomography coronary angiography in different coronary arteries  
*Fatih Koca*
- OP-27** Successful management of stuck rotablator that developed during rotational atherectomy of the calcified left anterior descending artery  
*Kudret Keskin, Sinan Şahin, Murat Kelbaş*
- OP-28** Relationship Between FIB-4 Index and Interatrial Block Detected on 12-lead Electrocardiography in Non-alcoholic Population  
*Ali Gökhan Özyıldız, Afag Özyıldız*
- OP-29** A Rare Case: Ablation of Focal Atrial Tachycardia from the Non-Coronary Aortic Cusp  
*Hallı Siner, İbrahim Etem Dural, Cem Korucu*
- OP-30** SYNTAX-II Score and LDL-C / HDL-C Ratio In Non- STEMI patients  
*Onder Ozturk, Çansu Ozturk*
- OP-31** The relationship between in-hospital mortality and systemic immune inflammation index in patients hospitalized with ST elevation and developing heart failure  
*Kamuran Kalkan, Mehmet Erdoğan, Burak Kardeşler, Hafize Corut Güzel, Serdal Baştuğ, Nedret Ülvan*
- OP-32** Caught in the Current: A Case of Free Floating Thrombus in Right Heart  
*Halenur Sarbaş*

16:15-16:30 **COFFEE BREAK / E-Poster Presentation / PP-07 – PP-09**

# CARDIOVASCULAR ACADEMY CONGRESS

## & INTERNATIONAL ACADEMY OF YOUNG CARDIOLOGISTS

Elexus Hotel Kyrenia, North Cyprus

18-22 September 2024

19 SEPTEMBER 2024, *Thursday*

Prof. Dr. ALAIN CRIBIER Hall

16:30-17:45 **Abstract Session 5**

**Chairpersons:** *Yasemin Kılavuz Doğan*

- OP-35** Successful Management of Coexisting Acute Coronary Syndrome and Pulmonary Embolism with High Mortality Risk  
*Nil Özyüncü, İrem Müge Akbulut Koyuncu, Kerim Esenboğa, Nur Aydınalp, Seyhmus Atan*
- OP-36** Shock index is an indicator of subclinical cardiotoxicity in patients receiving anthracycline chemotherapy  
*Muhammet Dural, Furkan Yetmiş, Cihat Çalışkan*
- OP-37** Bidirectional Ventricular Tachycardia in Fulminant Myocarditis: A Rare Presentation  
*Ahmet Can Çakmak, Direnç Yılmaz, Emre Eynel*
- OP-38** Cardioprotective effects of Dapagliflozin Against Radiotherapy Induced Cardiac Damage  
*Mehmet Hakan Uzun, Aziz Erden, Sebahat Ullusan, Seda Nur Aydoğdu, Elif Özkan, Alper Özseven, Kanat Gülle, Selim Sert, Hüseyin Emre Cebeci, Muhammet Ali Ekiz, Adnan Karabrahimoğlu, Mevlüt Serdar Kuyumcu*
- OP-39** Hematological and Biochemical Parameters Predictive of Mortality in Heart Failure with Preserved Ejection Fraction (HFpEF) Patients  
*Selim Aydemir, Sıdar Şiyar Aydın*
- OP-40** Predicting Mortality in Complicated Infective Endocarditis Using the RISK-E Score  
*Arzu Neslihan Akgün, Senem Has Hasırcı, Ezgi Polat Ocaklı*



# CARDIOVASCULAR ACADEMY CONGRESS

## & INTERNATIONAL ACADEMY OF YOUNG CARDIOLOGISTS

Elexus Hotel Kyrenia, North Cyprus

18-22 September 2024

19 SEPTEMBER 2024, *Thursday*

### ABSTRACT Hall

16:30-17:45 **Abstract Session 6**

**Chairpersons:** *Mesut Demir*

- OP-41** Effect of dapagliflozin on the no-reflow phenomenon in patients with acute myocardial infarction and type II diabetes mellitus  
*Nur Selin Nacar, Ömer Genç, Abdullah Yıldırım, Gökhan Alici, Çağlar Emre Çağlıyan, Ala Quisi*
- OP-42** Impact Of Hemodialysis On Left Atrial Functions  
*Bilge Naz Ateş, Cansin Tulunay Kaya, Muge Akbulut*
- OP-43** A case Report: All in One:Challenges and Innovations in TAVI and PBV Procedures  
*Yakup Alsancak, Ahmet Seyfettin Gürbüz, Mehmet Akif Düzenli, Muhammed Fatih Kaleli*
- OP-44** Primer LAD PCI Sırasında Koroner Arter Perforasyonu Gelişen Hastanın Yönetimi  
*Mehmet Kış, Çisem Oktay*
- OP-45** Successful Treatment of Coronary Perforation Following Percutaneous Intervention Due to STEMI Caused by Early LIMA-LAD Anastomatic Stenosis: A Case Report  
*Mustafa Umut Somuncu, Berk Mutlu*
- OP-46** The relationship between wrist circumferences and coronary artery diameters  
*Çağlar Alp, Mehmet Tolga Doğru, Rukiye Gönen Özdemir*
- OP-47** Value of ACEF Score in Predicting Postoperative Atrial Fibrillation  
*Atilla Koyuncu, Ersan Oflar*
- OP-48** p.R220L is a Pathogenic Novel GLA Gene Mutation Responsible for a Cardiac Phenotype of Fabry Disease  
*İpek Aydın*
- OP-87** Duke treadmill score predicts significancy of erectile dysfunction in patients with coronary slow flow  
*Dogac Oksen, Muzaffer Aslan, Hadeil Alhashmi, Gürsu Demirci*

# CARDIOVASCULAR ACADEMY CONGRESS

## & INTERNATIONAL ACADEMY OF YOUNG CARDIOLOGISTS

Elexus Hotel Kyrenia, North Cyprus

18-22 September 2024

20 SEPTEMBER 2024, *Friday*

Prof. Dr. ALAIN CRIBIER Hall

09:15-10:15 **Abstract Session 7**

**Chairperson:** *Berkay Ekici*

- OP-49** Systemic Immune-Inflammatory Index as a Predictor of Long-Term Mortality in Patients with Permanent Pacemakers  
*Mert Ilker Hayirođlu, Tufan Çınar, Gökse Çinier, Gizem Yüksel, Kıvanç Keskin, Cahit Coşkun, Gökçem Ayan, Vedat Çiçek, Ahmet Çağdaş Yumurtaş, Ahmet Ilker Tekkeşin, Levent Pay*
- OP-50** Exercise Sensitivity, Physical Activity and Kinesiophobia in Patients with Chronic Coronary Syndrome: A Cross Sectional Study  
*İrem Huzmeli, Oğuz Akkuş, Nihan Katayırıcı, İsmail Kara, Ramazan Yasdıbaş*
- OP-51** Cardiac magnetic resonance evaluation of myocardial fibrosis in type 2 diabetes mellitus patients with preserved left ventricular systolic function and its correlation with HbA1c level and diabetes duration  
*Sibel Catalkaya, Ayşe Füsün Bekircavuşođlu, Ahmet Yıldırım, Can Özkan, Selvi Öztaş*
- OP-52** Evaluation of right ventricular function in patients with subacute thyroiditis  
*Naci Şenkal, Alpay Medetalibeyođlu, Tufan Tükek, Gazi Çapar*
- OP-53** Performing sympathetic renal denervation procedure for the patient with persistent resistant hypertension following aortic coarctation intervention  
*Cem Dođan, Süleyman Çağan Efe, Anıl Avcı, Gülümser Sevgin Halil, Regayip Zehir, Ravza Betül Akbaş*

10:15-10:45 **COFFEE BREAK / E-Poster Presentation / PP-10 - PP-13**

Prof. Dr. VEDAT SANŞOY Hall

10:30-11:30 **(KVAK & IAYC joint session)**

**Revisiting Chronic Heart Failure**

**Chairpersons:** *Oktay Ergene, Larisa Dizdarevic*

Fantastic 5: Ablation in heart failure patients with atrial fibrillation - *Lorenzo Constantini*

Interventional new devices for HF patients - *Arash Hashemi*

13:15-13:30 **Discussion**

# CARDIOVASCULAR ACADEMY CONGRESS

## & INTERNATIONAL ACADEMY OF YOUNG CARDIOLOGISTS

Eleus Hotel Kyrenia, North Cyprus

18-22 September 2024

20 SEPTEMBER 2024, *Friday*

Prof. Dr. ALAIN CRIBIER Hall

10:45-12:00 **Abstract Session 8**

**Chairperson:** *Özcan Başaran*

- OP-55** Endovascular treatment of mesenteric artery aneurysm using flow diverting ROAD-SAVER stent to preserve the flow of side branches  
*Müslüm Şahin, Abdulrahman Naser*
- OP-57** Impact of the baseline renal function status on the long-term prognosis in patients underwent transcatheter aortic valve implantation  
*Melike Zeynep Kenger, Aykun Hakgür, Fatih Erkam Olgun*
- OP-58** The relationship between Neutrophil-Lymphocyte Ratio and Platelet-Lymphocyte Ratio and mortality in patients undergoing carotid artery stenting  
*Ali Yaşar Kılınc, Ziya Apaydın*
- OP-60** Evaluation of left ventricular systolic function by mitral annular plane systolic excursion (MAPSE) after recanalization of chronic total occlusion  
*Hacı Ali Kürklü, Nil Özyüncü, İrem Müge Akbulut Koyuncu*
- OP-73** Two Different Life-threatening Condition; Acute Coronary Syndrome and Trombocytopenia and as a Treatment Option Partial Splenic Embolization  
*Merve Kapçık, Yusuf Yılmaz, Murat Aşık, Aysu Oktay*

13:30-14:30 **LUNCH**

# CARDIOVASCULAR ACADEMY CONGRESS

## & INTERNATIONAL ACADEMY OF YOUNG CARDIOLOGISTS

Elexus Hotel Kyrenia, North Cyprus

18-22 September 2024

20 SEPTEMBER 2024, *Friday*

Prof. Dr. ALAIN CRIBIER Hall

**14:30-15:45 Device and Non-invasive Therapies**

**Chairpersons:** *Fethi Kılıçarslan, Ebru Akgül Ercan*

Treatment of hypertrophic cardiomyopathy arrhythmias - *Emir Baskovski*

Contemporary ICD use in patients with heart failure - *Marta Acena Ramos*

Clinical effects of enhanced external counterpulsation - *İlaha Agayeva*

**15:30-15:45 Discussion**

**15:45-16:00 COFFEE BREAK**

**16:00-17:15 Acute Heart Failure**

**Chairpersons:** *Zumreta Kušjugić, Hamza Duygu*

Clinical phenotypes and gender-related differences - *Ümit Yaşar Sinan*

Value of echocardiography in the treatment of patients with acute heart failure - *Rezzan Deniz Acar*

The current and future status of inotropes in heart failure management - *Sherzod Amedov*

**17:00-17:15 Discussion**

# CARDIOVASCULAR ACADEMY CONGRESS

## & INTERNATIONAL ACADEMY OF YOUNG CARDIOLOGISTS

Elexus Hotel Kyrenia, North Cyprus

18–22 September 2024

21 SEPTEMBER 2024, *Saturday*

### Prof. Dr. ALAIN CRIBIER Hall

09:15-10:30 **New breath in heart failure treatment: SGLT2 inhibitors**

**Chairpersons:** *Lorenzo Constantini*

Is there a difference between SGLT2 inhibitors in the treatment of heart failure? - *Aycan Fahri Erkan*

When should SGLT2 inhibitors be started in the treatment of HFREF? - *Mehmet Ali Çetiner*

Will SGLT2 inhibitors meet the expectations in the treatment of HFpEF? - *Eleni Nakou*

10:15-10:30 **Discussion**

10:30-11:00 **COFFEE BREAK**

11:00-12:15 **Pulmonary Hypertension**

**Chairpersons:** *Berkay Ekici, Mesut Demir*

Gray Area in Pulmonary Hypertension: PH Due to HFpEF and HFREF - *Selvi Öztas*

Is there a place for PAH-specific treatments in Group 2 PH? - *Ebru Akgül Ercan*

Differentiation between Group 1 and Group 2 PH in the diagnostic approach - *Çağlar Emre Çağlıyan*

12:00-12:15 **Discussion**

### Prof. Dr. VEDAT SANSOY Hall

12:45-13:45 **(KVAK & IAYC joint session)**

**Advanced Heart Failure**

**Chairpersons:** *Berkay Ekici, Ahmet Karagöz*

Updated definition and prognostic stratification - *Ilaha Aghaeva*

Management of Obstructive Sleep Apnea - *Ahmed Masci*

Mechanical circulatory support devices - *Arash Hashemi*

13:15-13:30 **Discussion**

13:30-14:30 **LUNCH**

### Prof. Dr. ALAIN CRIBIER Hall

14:30-15:45 **Optimisation of treatments for heart failure with reduced ejection fraction in routine practice**

**Chairpersons:** *Mehdi Zoghi, Özlem Yıldırımürk*

Who is the team captain? ARNI or SGLT2-i? - *Rezzan Denir Acar*

Biomarker-Guided Therapy - *Larisa Dizdarevic*

How to diagnose and treat venous congestion? - *Ebru Akgül Ercan*

15:30-15:45 **Discussion**

15:45-16:00 **COFFEE BREAK**



# CARDIOVASCULAR ACADEMY CONGRESS

## & INTERNATIONAL ACADEMY OF YOUNG CARDIOLOGISTS

Elexus Hotel Kyrenia, North Cyprus

18–22 September 2024

22 SEPTEMBER 2024, *Sunday*

Prof. Dr. ALAIN CRIBIER Hall

### 09:00-10:00 Abstract Session 9

**Chairperson:** Berkay Kicici, Javokhir Akhrorov

- OP-63** A New Marker To Predict No-Reflow Phenomenon: Leukocyte/Glucose Index  
*Onur Altinkaya, Sidar Siyar Aydın*
- OP-64** An Unpleasant Surprise During Pregnancy; Myocarditis or Ischemia?  
*Aylin Safak Arslanhan, Sinan Saymaz, Cengiz Sabanoglu, Alihan Ayata*
- OP-65** Left ventricular remodeling in patients with severely reduced ejection fraction undergoing revascularization considering myocardial viability  
*Yasmin Rustamova, Shahin Khalilov, Isfendiyar Ismayilov, Vasadat Azizov, Galib Imanov*
- OP-67** Successful LBBAP Therapy by Stylet-driven Ingevity lead for Complete Trifascicular Block in Ischemic HFmrEF patient: A case report  
*Ozgun Demiroglu, Yakup Yunus Yamanturk*
- OP-68** Unforeseen Beneficial Effect of Successful PVC Ablation: Achieving Migraine Attack Control Without Medication  
*Muhammed Emin Teker, Gozde Cansu Yilmaz, Muge Akbulut, Basar Candemir, Yakup Yunus Yamanturk*

Prof. Dr. ALAIN CRIBIER Hall

### 10:00-11:00 Abstract Session 10

**Chairperson:** Sinem Çakal, Sherzod Ahmedov

- OP-69** Effects of prosthetic heart valve-associated subclinical intravascular hemolysis on endothelium and cardiovascular system: a retrospective cohort study  
*Cagdas Ozdol, Kerim Esenboga, Demet Menekse Gerede Uludag, Yakup Yunus Yamanturk*
- OP-70** How We Managed An Acute Ischemic Stroke Event During Tavi Procedure  
*Oyku Gulmez Ozkaya, Omer Kozan, Abdulla Arslan*
- OP-71** Can Annual Follow-Ups Replace Biannual Visits for DOAC Therapy? Insights from the COVID-19 Era?  
*Kemal Engin, Ekin Günay, Nihan Turhan, Said Mesut Doğan, Özge Çetinarslan*
- OP-72** Successful Management Of Hyperacute Pseudoaneurysm of the Distal Superficial Femoral Artery  
*Regayip Zehir, Zeynep Esra Guner*
- OP-74** The predictive value of pan-immune-inflammation value (piv) for saphenous vein graft disease in post-coronary artery bypass grafting patients  
*Zeki Çetinkaya*

# CARDIOVASCULAR ACADEMY CONGRESS

## & INTERNATIONAL ACADEMY OF YOUNG CARDIOLOGISTS

Elexus Hotel Kyrenia, North Cyprus

18-22 September 2024

22 SEPTEMBER 2024, *Sunday*

### ABSTRACT Hall

#### 09:00-10:00 Abstract Session 11

**Chairperson:** *M. Fatih Yılmaz, Selçuk Öztürk*

- OP-75** Evaluating the Naples Prognostic Score in Predicting Long-Term Mortality for Cancer Patients with ST-Elevation Myocardial Infarction  
*Fatma Esin, Berkay Palaç*
- OP-76** Evaluation of Left Atrial Strain in Post COVID-19 Syndrome Patients with Persistent Dyspnea  
*Mesut Karatas, Nursen Keles, Kemal Emrehan Parsova, Mehmet Baran Karatas, Ali Nural, Cevdet Ugur Kocogullari, Erkan Kahraman*
- OP-77** A phenomenon that should not be ignored: A case report of vasospastic angina  
*Mustafa Kamil Yemiş, Şölen Taşlıçukur, Ahmet Göktuğ Çolakoğlu, Onurcan Türk, Fatma Nur Tanrıverdi, Shabnam Javadova, Turgut Karabağ, Ahmet Öz, Özgürcan Usta*
- OP-78** Acute coronary angiogenesis observed in the anterior STEMI in a Patient at Term Pregnancy  
*Semih Kalkan, Ahmet Karaduman*
- OP-79** Successful Intervention in a Patient With Massive Coronary Air Embolism to the Left Coronary Arteries During Coronary Angiography: A Case Report  
*Anıl Akray, Rabia Eker Akıllı, Ömer Tepe*
- OP-80** Successful Percutaneous Management of Device Migration After Left Atrial Appendage Occlusion: Combination of Guidewire and Snare  
*Fatma Esin, Sadık Volkan Emren, Mustafa Karaca, Emre Özdemir*

### ABSTRACT Hall

#### 10:00-11:00 Abstract Session 12

**Chairperson:** *Mehmet Ali Çetiner*

- OP-81** Challenges in a case of acute coronary syndrome with coronary artery anomaly  
*Hakan Kilci, Güneş Melike Doğan*
- OP-82** The predictive role of mitral annular calcification in the manifestation of symptomatic atrial fibrillation at long-term follow-up in patients with acute coronary syndrome  
*Hüseyin Durak, Nadir Emlek*
- OP-83** The Predictive Value of TG/HDL Ratio on No-Reflow Phenomenon in STEMI Patients  
*Yunus Emre Özbebek*
- OP-84** Effect of Body Mass Index on Electrocardiographic Parameters in Healthy Subjects  
*Zülkif Tanrıverdi, Ali Nizami Elmas*
- OP-85** Management of complications that develop during intervention in LAD ostial lesion  
*Sinem Çakal, Halil İbrahim Biter, Erdal Belen, Mehmet Mustafa CanKahraman, Cevdet Ugur Kocogullari, Hüseyin Oğuz*
- OP-86** Coronary Perforation in STEMI, How We Managed It?  
*Cansu Ozturk*

# CARDIOVASCULAR ACADEMY CONGRESS

## & INTERNATIONAL ACADEMY OF YOUNG CARDIOLOGISTS

Elexus Hotel Kyrenia, North Cyprus

18-22 September 2024

22 SEPTEMBER 2024, *Sunday*

### ABSTRACT Hall

11:00-12:15 **Abstract Session 13**

**Chairperson:** *Yasemin Kılavuz Doğan*

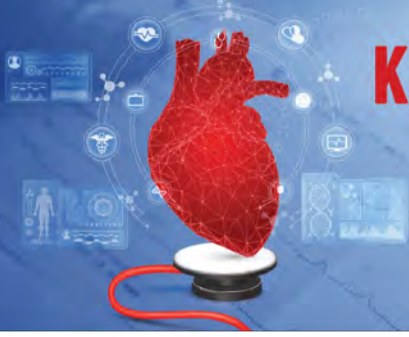- OP-88** Coronary Artery Fistula With ST Elevation Myocardial Infarction Finding on ECG. Fistulization From Three Coronary Arteries to the Left Ventricle (Coronary-Cameral Fistulae)  
*Abdulkadir Çakmak, Ömer Kertmen*
- OP-89** Management of Acute Saphenous Vein Graft Thrombotic Occlusion: Effective Use of Mechanical and Medical Treatment within the PCI Strategy  
*Yakup Yunus Yamanturk*
- OP-90** 10-second pause associated with syncope: A successful cardiac neuromodulation case managed without resorting to permanent pacemaker implantation  
*Yakup Yunus Yamanturk, Mahmut Ekrem Cunetoglu, Bilge Nazar Ateş, Basar Candemir, Elif Oya İlhan*
- OP-91** Do specific ECG variants in acute coronary syndrome indicate particular coronary anomalies? A patient with De Winter Syndrome had a circumflex artery (Cx) originating from the right coronary artery (RCA)  
*Elif Oya İlhan, Yakup Yunus Yamanturk*
- OP-92** New adjunct method for successful transseptal puncture in lipomatous hypertrophy: "Smart"Touch to the interatrial septum  
*Yakup Yunus Yamanturk, Muhammed Emin Teker, Basar Candemir, Elif Oya İlhan*
- OP-93** The real Heartbreak  
*Nasir Ali Tokmak, Abdullah Orhan Demirtaş, Ali Akin Önal*
- OP-94** "A New Model for Prediction of Myocardial Injury of Non-Elective Surgery in Elderly"  
*Mert Babaoglu, Faysal Saylik, Samet Yavuz, Ahmet Furkan Mazlum, Hatice Altinisik, Mustafa Oguz, Mert Ilker Hayiroglu, Tufan Cinar, Ulas Bagci, Vedat Çiçek*
- OP-95** The Role of ALBI Score in Predicting Thrombus Burden in Patients with Non-ST-Elevation Myocardial Infarction  
*Hakan Caf, Abdullah Yıldırım, Mükremin Coşkun*
- OP-96** Prodromal Symptoms in Patients Presenting with Acute Coronary Syndrome  
*Duygu Malkoçoğlu, Faruk Bulut, Selin Arca, Buket Hancer, Nimet Selin Aydın, Elton Soydan, Mehdi Zoghi, Arzu Rzayeve*

### Prof. Dr. ALAIN CRIBIER Hall

11:00-11:10 **CONGRESS CLOSING CEREMONY**

# ORAL PRESENTATION





# KARDİYOVASKÜLER AKADEMİ KONGRESİ

## & INTERNATIONAL ACADEMY OF YOUNG CARDIOLOGISTS

Elexus Hotel Girne. K.K.T.C.  
18-22 Eylül 2024

### **[OP-01] A CASE OF ACUTE CORONARY SYNDROME DUE TO UNNECESSARY USE OF NON-STEROIDAL ANTI-INFLAMMATORY DRUGS**

*Tuğçe Kaya, Betül Balaban Koçaş, Gökhan Çetinkal  
Prof. Dr. Cemil Tascioglu City Hospital, Istanbul, Turkey*

**Introduction:**The synthesis of COX enzymes, which is important in prostaglandin synthesis, is mainly inhibited by non-steroidal anti-inflammatory drugs (NSAID's). If COX-2 enzyme synthesis is inhibited much more than COX-1, endothelium is more prone to thrombosis. Here we report a case suffering from ST Elevation Myocardial Infarction (STEMI) due to NSAID usage.

**Case:**47-year-old female presented to our emergency department with a typical chest pain which was started one hour ago. She had a history of hypertension and peripheral artery disease.

She was on etodolac therapy by herself without an accurate medical indication. The patient had been taking etodolac twice a day for three days. Electrocardiography was consistent with Inferior STEMI.

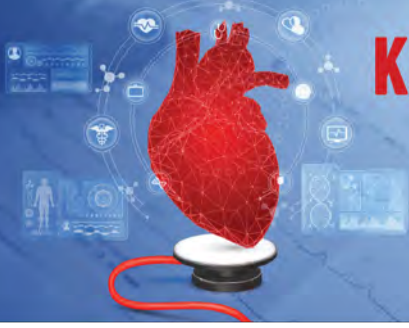Transthoracic echocardiography revealed severe hypokinesia in the basal and mid inferior segments, hypokinesia in the mid inferolateral segment and ejection fraction was measured 50%.The patient was underwent primary percutaneous coronary intervention

Coronary angiography showed thrombus at distal segment of circumflex artery (CX) and mid segment of left anterior descending artery (LAD) (Figure 1A and 1B). Right coronary artery was totally occluded from the proximal segment. (Figure 2)The lesion was crossed with a floppy wire. IV and IC tirofiban infusion was initiated. Predilatation was performed with a 2.75 × 15 mm NC balloon, followed by implantation of a 4.0 × 35 mm drug eluting stent. Procedure was completed successfully. (Figure 3)Control angiography was performed after three days. Control angiography revealed no thrombus in both CX and LAD. (Figure 4A and Figure 4B) Medical treatment was decided for the patient in follow up period. She was discharged from hospital without any complication.

**Discussion:**Since patients using NSAIDs may experience severe complications such as coronary thrombosis, it is crucial to avoid excessive NSAID use in patients with severe cardiovascular risk factors.Also, in outpatient clinics patients must be educated and informed about unnecessary NSAID usage.

**Keywords:** CORONARY THROMBOSIS, NON-STEROIDAL ANTI-INFLAMMATORY DRUGS, ST ELEVATION MYOCARDIAL INFARCTION



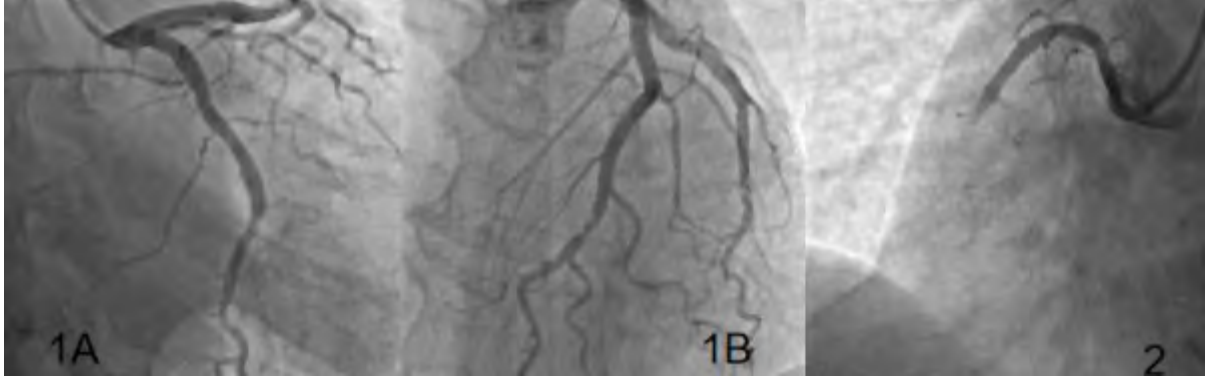

# KARDİYOVASKÜLER AKADEMİ KONGRESİ

## & INTERNATIONAL ACADEMY OF YOUNG CARDIOLOGISTS

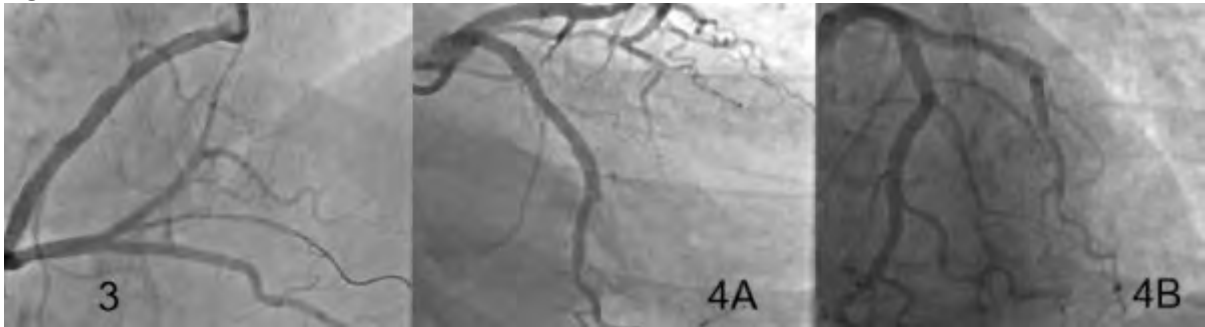
Elexus Hotel Girne, K.K.T.C.  
18-22 Eylül 2024

**Figure 1A-1B-2**



*thrombus at distal segment of circumflex artery, mid segment of left anterior descending artery(Figure 1A and 1B). Right coronary artery was totally occluded from the proximal segment. (Figure 2)*

**Figure 3-4A-4B**



*Procedure was completed successfully. (Figure 3).Control angiography revealed no thrombus in both CX and LAD. (Figure 4A and Figure 4B)*



# KARDİYOVASKÜLER AKADEMİ KONGRESİ

## & INTERNATIONAL ACADEMY OF YOUNG CARDIOLOGISTS

Elexus Hotel Girne, K.K.T.C.  
18-22 Eylül 2024

### [OP-02] CORONARY PERFORATION AND ITS MANAGEMENT

*Mustafa Sarı, Ali Yaşar Kılınc, Mehmet Kara*  
*Haseki training and research hospital*

Coronary perforation (CP) is a rare complication of percutaneous coronary intervention (PCI) and can lead to pericardial tamponade and hemodynamic instability. Prolonged balloon inflation is a reasonable treatment choice for CP, but there is no standard recommendation on the preferable choice between the balloon site for prolonged balloon inflation (ie, proximal and in situ of the perforation). We present a case of successful prolonged balloon inflation at the proximal site of the CP after the failure of balloon advancement to the site of perforation. The patient developed CP during wiring of calcific lesion. Proximal inflation could manage the CP. The lesson to be learned from this case is that in patients with CP after PCI, if the balloon cannot be advanced to the perforation site, prolonged inflation in the proximal region may be an alternative option.

A 79 year-old woman was admitted to the our clinic with the complaint of chest pain, which was tight in character and had been present for 9 months, evidence of ischemia with myocardial perfusion scintigraphy (MPS).

According to the coronary angiography,  
LMCA: Normal LAD: Proximal 40% obstruction, CX: Proximal 80% obstruction, IMA:  
Osteal %70 obstruction, RCA: Mid 99% calcific obstruction

PCI for the RCA occlusion was planned ad hoc.

Calcific lesion could not be passed with floppy wire. This wire was sent to RV branch of RCA. A PT2 guide wire was passed across the lesion and control images revealed a perforation at the level of the mid RCA. It was decided to close the perforation with prolonge balloon inflation method.

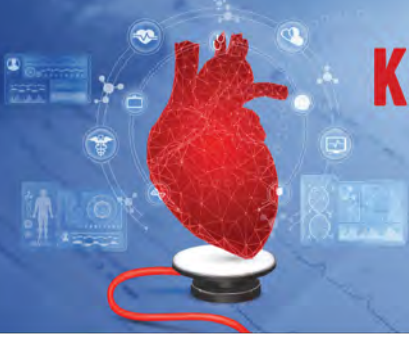The balloon could not be advanced to the perforation site. So we decided to inflate baloon in the proximal region. A 2.5X12 mm semicompliant balloon was inflated for 5 minutes in the proximal region of RCA.

After this prolonged inflation, control images revealed RCA dissection form proximal to distal was observed. Then Sion Black wire was taken. Inadvertent subintimal tracking of the sion black guidewire was observed. This wire was left in subintimal space and a buddy wire was made with Gaia 2 wire and true lumen was reached. Distal PTCA was performed with 1.5X20 and 2.5X12 \* 2 balloons.

Then, 2.5X48 MM DES stent at 12 ATM was implanted distally,  
2.75X48 MM DES stent at 16 ATM was implanted in the mid region,  
3.0X23 MM DES stent 16 ATM WAS implanted proximally. Then, post-dilatations were performed with 3.5X15 MM NC balloon.

No pericardial fluid was observed in the control echocardiography performed after the procedure.

**Keywords:** Coronary artery perforation, coronary balloon angioplasty, percutaneous coronary intervention

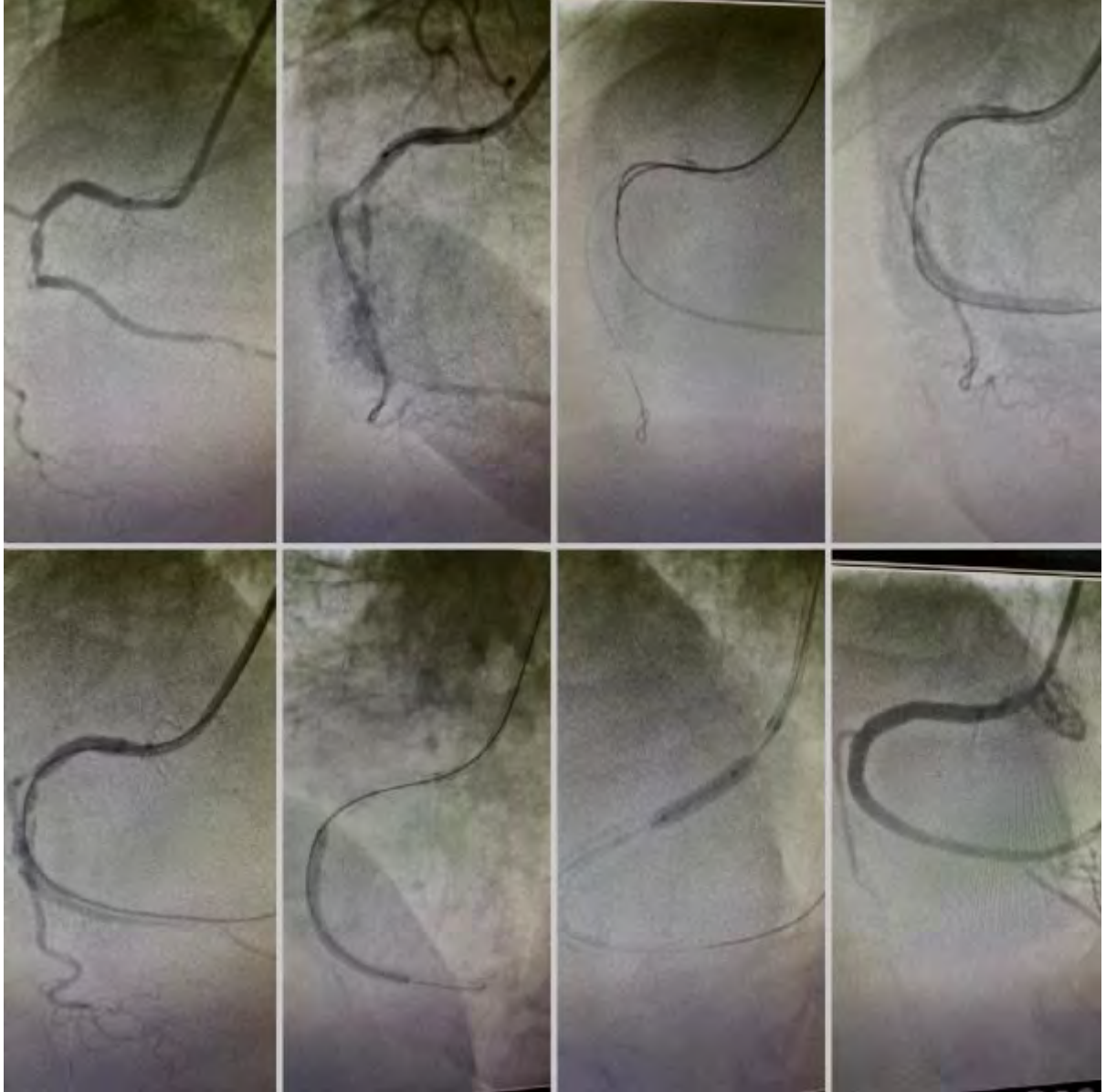

# KARDİYOVASKÜLER AKADEMİ KONGRESİ

## & INTERNATIONAL ACADEMY OF YOUNG CARDIOLOGISTS

Elexus Hotel Girne, K.K.T.C.  
18-22 Eylül 2024

Coronary angiography images of the procedure







# KARDİYOVASKÜLER AKADEMİ KONGRESİ

## & INTERNATIONAL ACADEMY OF YOUNG CARDIOLOGISTS

Elexus Hotel Girne, K.K.T.C.  
18-22 Eylül 2024

### [OP-03] CLINICAL AND DEMOGRAPHIC CHARACTERISTICS OF PATIENTS WITH ACUTE CORONARY SYNDROMES ACCORDING TO PRESENTATION TYPE

*Nedret Ülvan*<sup>1</sup>, Ömer Işık<sup>2</sup>, Mete Kağan Polat<sup>3</sup>, Elton Soydan<sup>4</sup>, Berkay Ekici<sup>3</sup>, Mehdi Zoghi<sup>4</sup>

<sup>1</sup>*Department of Cardiology, Bilkent city hospital*

<sup>2</sup>*FIRAT UNIVERSITY DEPARTMENT OF CARDIOLOGY, ELAZIĞ*

<sup>3</sup>*Ufuk University Ridvan Ege Hospital*

<sup>4</sup>*Department of Cardiology, Ege University*

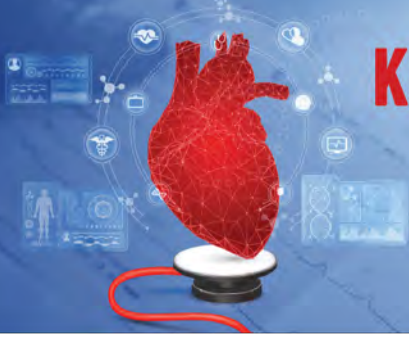**Introduction:** Acute coronary syndromes are a group of syndromes that are frequently encountered in emergency departments and are life-threatening. Clinical and demographic features of acute coronary syndromes, have not been examined in detail according to their types. In this study, we examined possible clinical and demographic differences between ACS types.

**Materials-Methods:** 252 consecutive patients who presented with ACS (NSTEMI and STEMI) were included in our study. Study data were obtained using a pre-prepared case report form administered online. The data were statistically evaluated in terms of clinical and demographic characteristics according to ACS type.

**Results:** 252 patients, 177 (70.2%) male and 75 (29.8%) female, with a mean age of 63.2±12.2 years, were included in the study. Of the cases, 47.2% were hypertensive, 33.3% hyperlipidemic, 33.7% diabetic and 41.3% smokers. At the time of application, it was determined that 40.5% of the patients came with STEMI and 59.5% with NSTEMI. When the method of application to the hospital was examined, it was seen that 31% of the patients came by ambulance, 57.1% by private vehicle, 3.2% by public transportation and 7.5% of the patients were detected during the outpatient clinic application. 45.2% of the individuals had a family history of CAD. It was understood that 23.8% of the patients had a cardiology outpatient clinic check-up 3 months before the development of ACS. When the cardiac history was examined, it was seen that 10.7% of the patients had CABG surgery, 34.1% had stents and 3.2% had pacemakers. Of the patients, 225 underwent coronary angiography before discharge. It was observed that 76.2% of them received stents, 3.2% CABG surgery and 11.5% medical treatment. Patients with NSTEMI had higher rates of 2- or 3-vessel disease than patients with STEMI (25.3% vs. 19.6%; p<0.001). Males were predominant in both ACS groups [NSTEMI (69.3%), STEMI (71.6%)]. The proportion of patients who could not undergo angiography (14.7% vs 1%) or who were decided to undergo medical treatment (16.7% vs 3.9%) or CABG surgery (4.7% vs 1%) after angiography was higher in NSTEMI patients than in STEMI patients (p<0.001). Initial clinical characteristics of the patients according to the type of ACS are given in Table-1.

**Discussion:** According to the results obtained from our study, it was observed that patients presenting with NSTEMI had more comorbidities, consistent with the literature. During the application, it was determined that patients with NSTEMI had higher blood pressure values than those presenting with STEMI. Patients with STEMI were found to have lower initial EF (%) values as a result of possible transmural involvement of the left ventricle. It was observed that STEMI patients applied to healthcare institutions in a shorter time than patients with NSTEMI. The proportion of patients arriving at the hospital by ambulance was higher in STEMI patients than in NSTEMI patients.

**Keywords:** Acute coronary syndromes, clinical features, demographic features



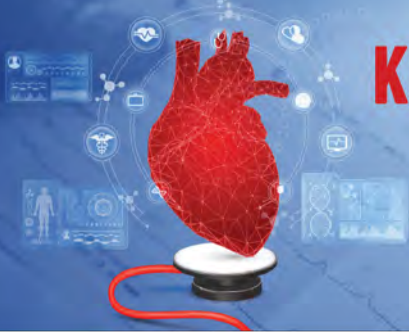# KARDİYOVASKÜLER AKADEMİ KONGRESİ

## & INTERNATIONAL ACADEMY OF YOUNG CARDIOLOGISTS

Elexus Hotel Girne, K.K.T.C.  
18-22 Eylül 2024

**Table-1 Clinical and demographic features according to ACS type**

	NSTE-ACS (n=150)	STEMI (n=102)	P değeri
Age	64.1±11.7	61.8±12.8	0.116
Systolic BP	137.2±22.8	125.9±21.5	<0.011
Diastolic BP	80.1±13.7	75.3±15.4	0.008
Pulse (bpm)	80.9±14.4	78.8±14.7	0.241
BMI (kg/m <sup>2</sup> )	27.5±3.9	26.9±4.0	0.190
Years of smoking	15.9±20.1	16.2±19.4	0.765
LDL-C (mg/dL)	126.3±44.3	123.9±38.4	0.676
Ejection Fraction (%)	49.7±11.6	44.8±11.9	<0.001
Hospitalization duration (days)	3.7±1.9	4.1±2.5	0.295
Application period (hours)	2.0±1.1	1.3±1.2	<0.001
Ambulance rate (%)	26.7	37.3	0.001
Hypertension (%)	52.7	39.2	0.036
Hyperlipidemia (%)	38.7	25.5	0.029
Diabetes Mellitus (%)	39.3	25.5	0.023



# KARDİYOVASKÜLER AKADEMİ KONGRESİ

## & INTERNATIONAL ACADEMY OF YOUNG CARDIOLOGISTS

Elexus Hotel Girne, K.K.T.C.  
18-22 Eylül 2024

### [OP-04] PROGNOSIS AND MORTALITY IN PATIENTS WITH GROUP 1 AND GROUP 4 PULMONARY HYPERTENSION

Saadet Aydın

*Bakircay University, Faculty Of Medicine, Department of Cardiology, Izmir, Turkey.*

**Introduction:** Pulmonary hypertension is a major global health problem. WHO Group 1 refers to pulmonary arterial hypertension, which occurs when the pulmonary arteries become narrow, thickened, or stiff. WHO Group 4 is called chronic thromboembolic pulmonary hypertension (CTEPH) and may occur due to failure of a blood clot in the pulmonary arteries to resolve. In this study, we present the 9-year follow-up data and clinical features of patients with Group-1 and 4 pulmonary hypertension.

**Materials-Methods:** 64 patients who underwent right heart catheterization (RHC) with a preliminary diagnosis of pulmonary hypertension between 2016-2024 were included in the study. Five patients were excluded from the study, because their mean pulmonary artery pressure values were  $< 20$  mmHg in the RHC. 59 patients were evaluated in terms of demographic characteristics, echocardiography parameters, catheter data and mortality rates during follow-up.

**Results:** Of the 59 patients who participated in the study, 15 (25.4%) were male and 44 (74.6%) were female. 57.5% of the patients were evaluated as group-1, 37.3% as group-4 and 5.1% as CTEH. The echocardiography and RHC findings of the patients are given in Table-1. During the follow-up, 21 patients were found to have died (12 patients in group-1, 9 patients in group-4). Patients with mortality had higher sPAP ( $72.9 \pm 17.5$  vs  $53.8 \pm 14.9$ ,  $p < 0.001$ ), mPAP ( $39.8 \pm 11.4$  vs  $36.9 \pm 14.6$ ,  $p = 0.215$ ) and right atrium pressure (RAP) values ( $14.1 \pm 19.8$  vs  $8.8 \pm 7.8$ ,  $p = 0.035$ ) (mmHg) than patients who survived. Despite recent developments in the treatment of group-1 and 4 pulmonary hypertension, mortality rates are still very high in these patients. In this context, echocardiographic and RHC based follow-up of patients is important

**Discussion:** in determining high-risk patients. In our study, the relationships between mortality and echocardiographically determined sPAP and RHC determined SaAP values suggest that patients with elevated values of these parameters should be closely monitored.

**Keywords:** Prognosis and Mortality, Group 1 Pulmonary Hypertension, Group 4 Pulmonary Hypertension

**Table-1 Basic characteristics of Group 1 and 4 patients**

mmHg	sPAB	mPAB	RAP
Group 1	$61.0 \pm 16.5$	$40.1 \pm 14.8$	$9.3 \pm 8.0$
Group 2	$63.1 \pm 19.0$	$36.4 \pm 10.1$	$13.4 \pm 19.5$

### [OP-05] POSSIBLE DIFFERENCES IN NEUTROPHIL/LYMPHOCYTE RATIO, ECHOCARDIOGRAPHY, AND



# KARDİYOVASKÜLER AKADEMİ KONGRESİ

## & INTERNATIONAL ACADEMY OF YOUNG CARDIOLOGISTS

Elexus Hotel Girne. K.K.T.C.  
18-22 Eylül 2024

### CATHETERIZATION PARAMETERS IN PATIENTS WITH GROUP 1 AND GROUP 4 PULMONARY HYPERTENSION

Saadet Aydın

*Bakircay University, Faculty Of Medicine, Department of Cardiology, Izmir, Turkey*

**Introduction:** N/L ratio is an inflammatory marker that can be easily detected from hemogram analysis in clinical practice. Inflammation has been reported in the literature to contribute to pulmonary vascular disease, pulmonary arterial hypertension (PAH), and even CTEPH etiopathogenesis. In this study, we investigated possible differences in N/L ratio, echocardiographic, and catheter parameters in Group 1 and 4 patients.

**Material-Methods:** Twenty-three consecutive cases who underwent right heart catheterization in our center between 2023 and 2024 were retrospectively analyzed in terms of N/L ratio, echocardiography, and catheterization findings.

**Results:** Of the patients included in the study, 18 were female (78.3%) and 5 were male (21.7%). No statistically significant difference was observed between the groups in terms of N/L ratio (2.8  $\pm$  1.1 vs 5.1  $\pm$  4.9). Mean pulmonary artery pressure determined by right heart catheterization (RHC) was higher in Group 1 patients than in Group 4 patients (45.9  $\pm$  17.3 vs 32.9  $\pm$  11.8 mmHg; p=0.037). Systolic pulmonary artery pressure determined by echocardiography was also numerically higher in Group 1 patients than in Group 4 patients, but there was no statistically significant difference (57.5  $\pm$  17.6 vs 50.8  $\pm$  9.5, p=0.525). Again, pulmonary vascular resistance (7.3  $\pm$  7.1 vs 4.0  $\pm$  1.9 WU, p=0.281), pulmonary capillary wedge pressure (13.3  $\pm$  5.1 vs 11.3  $\pm$  2.9 mmHg, p=0.447) and right atrial pressure (13.2  $\pm$  11.8 vs 7.7  $\pm$  2.0 mmHg, p=0.315) values determined by RHC were higher in group 1 patients, but were not statistically significant. In addition, there was no difference between the groups in terms of TAPSE (mm) (16.7  $\pm$  5.1 vs 19.1  $\pm$  5.4, p=0.316) and EF (%) (60.5  $\pm$  3.9 vs 59.3  $\pm$  6.6, p=0.928) values determined by echocardiography.

**Discussion:** According to the findings obtained from our study, we cannot say that a specific parameter is diagnostic in group 1 and group 4 patients. Clinical data, laboratory findings and various imaging methods should be used in differential diagnosis.

**Keywords:** Neutrophil/lymphocyte ratio, Group 1 - Group 4 pulmonary, hypertension, echocardiography, catheterisation





# KARDİYOASKÜLER AKADEMİ KONGRESİ

## & INTERNATIONAL ACADEMY OF YOUNG CARDIOLOGISTS

Elexus Hotel Girne, K.K.T.C.  
18-22 Eylül 2024

### [OP-06] EVALUATION OF TRIGLYCERIDE-GLUCOSE INDEX IN THREE GENERATION BETA-ADRENOCEPTOR BLOCKERS

Demet Erciyes

*Demirođlu Bilim University*

Beta-blockers (B-blockers) differ in their metabolic effects and side effects. First and second generation B-blockers have negative effects on insulin sensitivity and glucose metabolism. They have been associated with insulin resistance and increased risk of new-onset diabetes mellitus, whereas third generation B-blockers have more favorable cardiometabolic effects.

The Triglyceride-Glucose Index (TyG index), calculated from fasting triglyceride and glucose levels, has been accepted as a surrogate marker of insulin resistance. Its diagnostic and prognostic value has been demonstrated in several diseases, including coronary heart disease, hypertension, diabetes mellitus, and ischemic stroke. We compared the metabolic effects of beta-blockers by evaluating the TyG index in patients treated with this group of drugs.

#### Material and methods

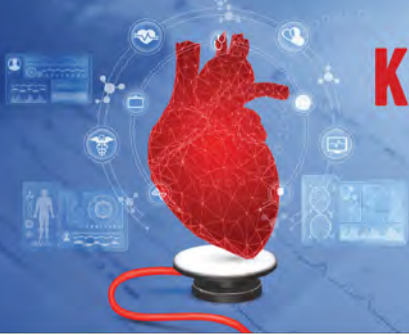Five hundred and eighteen patients treated with B-blockers were included in the study. Patients were divided into three groups according to the use of B-blocker type. First, second and third generation B-blocker groups were composed of 100, 256 and 162 patients, respectively. The TyG index was calculated according to the formula:  $\text{Ln} [\text{fasting triglycerides (mg/dL)} \times \text{fasting plasma glucose (mg/dL)} / 2]$

**Results:** The mean age of the study population was  $58.73 \pm 4.87$  years, of which 251 (48.5%) were female. Average duration of the beta-blocker use was found to be as  $42.28 \pm 24.30$  months. There were no significant differences among the three groups with respect to age, sex, presence of hypertension, coronary artery disease, and medication use. Glucose, triglyceride and TyG index were significantly different between the three groups ( $p < 0.001$  for all). Post hoc analysis showed that the differences were manifested between the third generation and the second generation and the third generation and the first generation groups.

**Discussion:** Our study showed that patients treated with third-generation B blockers had lower levels of the TyG index compared to patients treated with other-generation B blockers.

B-blockers are commonly used in patients at high cardiovascular risk, and their adverse effects have become a concern for clinicians. Over time, several B-blockers have been developed with additional vasodilating and distinct metabolic activities, making them desirable in clinical practice. Patients who used first, and second-generation B-blockers at higher risk of getting diabetes mellitus compared to patients who do not use them. It has been found that metoprolol significantly reduced insulin sensitivity index in patients with metabolic syndrome. Moreover third generation B-blockers are associated more favorable metabolic effects with higher insulin sensitivity. Our results showed that third generation B-blockers leads to more favorable metabolic effects in terms of reduced values of TyG index.

**Keywords:** Beta-blockers, triglyceride-glucose index, coronary heart disease



# KARDİYOVASKÜLER AKADEMİ KONGRESİ

## & INTERNATIONAL ACADEMY OF YOUNG CARDIOLOGISTS

Elexus Hotel Girne, K.K.T.C.  
18-22 Eylül 2024

### Demographic features of different beta blocker groups

	First generation	Second generation	Third generation	p
Age (years)	58.55±4.64	59.14±4.84	58.15±5.11	0.138
Gender (n,%)				0.573
male	56 (56)	131 (51.2)	80 (49.4)	
female	44 (44)	125 (48.8)	82 (50.6)	
Hypertension	56 (56)	137 (53.5)	79 (48.8)	0.472
Coronary artery disease (n,%)	47 (47)	129 (50.4)	87 (53.7)	0.565
Calcium channel blocker (n,%)	44 (44)	128 (50)	86 (53.1)	0.359
Angiotensin receptor blocker (n,%)	13 (13)	40 (15.6)	27 (16.7)	0.723
Angiotensin converting enzyme inhibitor (n,%)	14 (14)	34 (13.3)	22 (13.6)	0.984
Thiazide diuretic (n,%)	29 (29)	77 (30.1)	53 (32.7)	0.782
Statin (n,%)	47 (47)	129 (50.4)	88 (54.3)	0.498
Glucose (mg/dl)	98.81±5.92	97.06±5.84	95.16±3.63	<0.001
Triglyceride (mg/dl)	133.43±18.52	135.18±17.15	126.24±11.46	<0.001
TyG index	8.78±0.18	8.77±0.16	8.69±0.11	<0.001



# KARDİYOVASKÜLER AKADEMİ KONGRESİ

## & INTERNATIONAL ACADEMY OF YOUNG CARDIOLOGISTS

Elexus Hotel Girne, K.K.T.C.  
18-22 Eylül 2024

### **[OP-07] JAIL TAIL FRACTURE AND LONGITUDINAL STENT DEFORMATION ASSOCIATED WITH DEEP CATHETER ENGAGEMENT DURING LEFT MAIN STEM STENTING**

*Süleyman Atalay, Betül Balaban Kocaş, Gökhan Çetinkal*

*Prof. Dr. Cemil Taşçıoğlu City Hospital*

**INTRODUCTION:** The use of a jailed wire during provisional side branch stenting is an acceptable and widely used technique in daily practice. However there is a risk of the jailed wire becoming trapped or incarcerated behind the stent. When support catheters such as AL1, AL2 and EBU are used, deep engagement of the catheter may occur during stenting of the LMCA as the wire is retracted, leading to longitudinal stent deformation. The jailed wire may fracture during attempts to retract it, potentially resulting in life-threatening complications. To prevent these complications, crushing with another stent or complete extraction of the stent from the coronary artery may be necessary. Here we report jailed wire a fracture of the tip of the jailed wire and longitudinal deformation of the LMCA stent case due to deep engagement of the 7F EBU 3.5cm catheter.

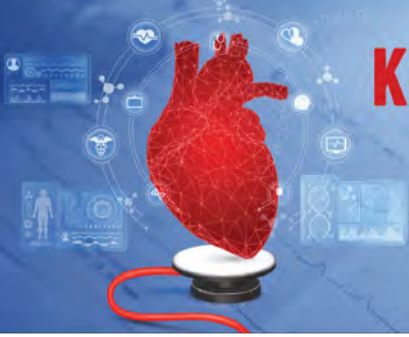**HISTORY OF PRESENTATION:** 63-year-old male presented to our outpatient clinic with a complaint of shortness of breath. The patient has a history of diabetes mellitus, hypertension, and bladder cancer. A exercise stress test was consistent with ischemia. So we decided to perform CAG. CAG revealed LMCA+ two vessel disease. The heart team recommended CABG operation for the patient but he rejected. So we planned IVUS guided PCI for LMCA lesion.

**INVESTIGATION:** CAG and IVUS revealed a 60% stenosis in the distal LMCA, a 30% plaque in the proximal LAD and a plaque in Cx (Figure 1a). RCA was observed to be totally occluded from the proximal segment (Figure 1b).

**MANAGEMENT:** We planned a crossover LMCA provisional stenting after IVUS. LAD and Cx was crossed with workhorse floppy wires. LMCA lesion was predilatated with a 3.5x18 mm NC balloon. A 4.0\*26 mm DES was deployed from the LMCA to the LAD at 14 atm (Figure 2a). POT was performed in the LMCA using a 5.0\*12 mm NC balloon. After POT, control views revealed critical stenosis at the ostium of Cx (Figure 2b). The Cx was rewired and we planned to perform kissing balloon. Two NC balloons were positioned to both LAD and Cx (Figure 3a). Before inflating the balloons, the jailed wire was retracted. While pulling out the jailed wire, the tip of the wire was ruptured under LMCA stent struts. At the same time the EBU catheter was deeply engaged uneventfully, resulting to longitudinal stent deformation of the LMCA stent (Figure 3b). The LMCA was visualized with IVUS, revealing multiple malapposed struts. The crushed LMCA stent was dilated with a 3.5\*13 mm NC balloon. A 4.0\*13 mm Firehawk DES was deployed at 18 atmospheres, positioned to LMCA ostium. Final POT was performed using a 5.0\*15 mm NC balloon (Figure 6). The broken piece of the wire was jailed under the new stent struts. LMCA was re-evaluated with IVUS, showing well-apposed stent struts (Figure 4a). The procedure was concluded. (Figure 4b)

**DISCUSSION:** Physicians must kept in mind the wire rupture and longitudinal stent deformation during retraction of jailed wire in the LMCA stenting session. Very soft and gentle maneuvers must be done in this procedure.

**Keywords:** longitudinal stent deformation, deep catheter engagement, jail tail fracture, stent retraction complications



# KARDİYOVASKÜLER AKADEMİ KONGRESİ

## & INTERNATIONAL ACADEMY OF YOUNG CARDIOLOGISTS

Elexus Hotel Girne, K.K.T.C.  
18-22 Eylül 2024

**FIGURE 3-4**

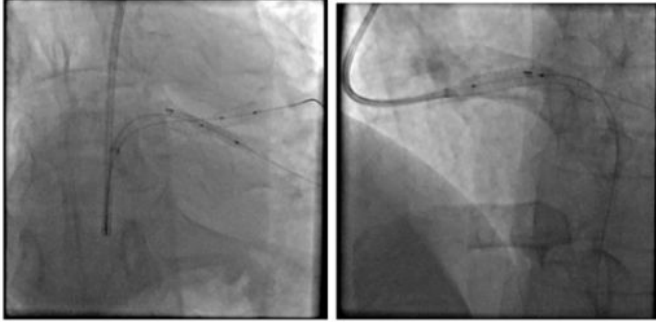


Figure 3a

Figure 3b

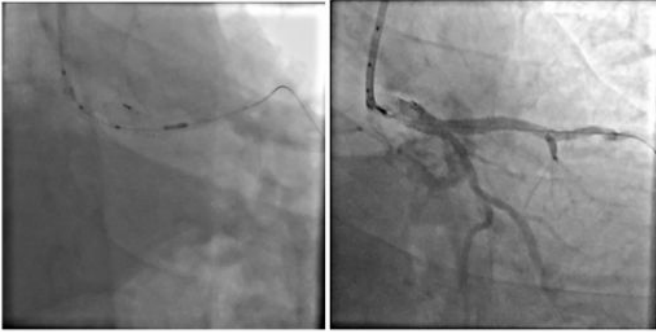


Figure 4a

Figure 4b

*complication and management*



# KARDİYOVASKÜLER AKADEMİ KONGRESİ

## & INTERNATIONAL ACADEMY OF YOUNG CARDIOLOGISTS

Elexus Hotel Girne, K.K.T.C.  
18-22 Eylül 2024

figure1-2

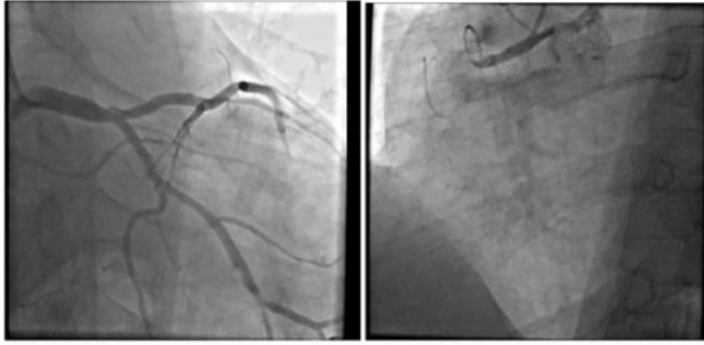


Figure 1a

Figure 1b

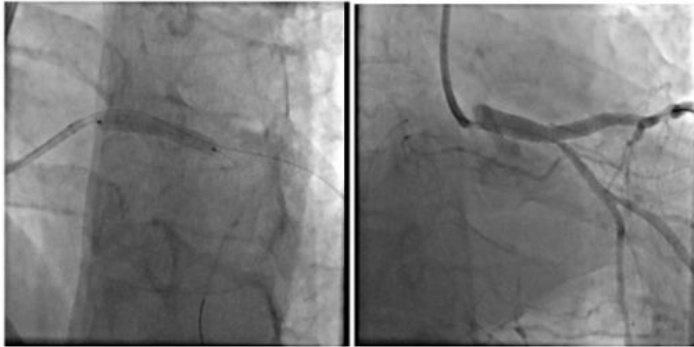


Figure 2a

Figure 2b

*coronary angiography and LMCA PCI*



# KARDİYOVASKÜLER AKADEMİ KONGRESİ

## & INTERNATIONAL ACADEMY OF YOUNG CARDIOLOGISTS

Elexus Hotel Girne. K.K.T.C.  
18-22 Eylül 2024

### **[OP-08] TO EVALUATE LEFT VENTRICULAR FUNCTION WITH STRAIN ECHOCARDIOGRAPHY IN PATIENTS WITH OR WITHOUT TREATMENT WITH A DIAGNOSIS OF CORONARY SLOW FLOW**

*Ecem Gurses, Saadet Aydın*

*Cardiology, Bakırçay University Çiğli Education Research Hospital, İzmir Turkey*

In our study, we aimed to compare left ventricular functions, evaluated by strain echocardiography, between patients who were diagnosed with coronary slow flow and subsequently used calcium channel blocker or beta blocker treatment, and patients who did not. In our study, we retrospectively compare the left ventricular functions of 100 coronary slow flow patients diagnosed by coronary angiography in our hospital, 50 patients who received treatment and 50 patients who did not receive treatment, by evaluating them with strain echocardiography

**Keywords:** coronary slow, flow, strain echocardiography



# KARDİYOVASKÜLER AKADEMİ KONGRESİ

## & INTERNATIONAL ACADEMY OF YOUNG CARDIOLOGISTS

Elexus Hotel Girne. K.K.T.C.  
18-22 Eylül 2024

### [OP-09] HIGH OSAKA PROGNOSTIC SCORE IS ASSOCIATED WITH INCREASED THROMBUS BURDEN IN PATIENTS WITH ST ELEVATION MYOCARDIAL INFARCTION

Nail Burak Özbeyaz<sup>1</sup>, Engin Algül<sup>2</sup>, Haluk Furkan Şahan<sup>2</sup>, Gürkan İş<sup>2</sup>

<sup>1</sup>Ankara University

<sup>2</sup>Etlik City Hospital

**Background and Aim:** It is known that poor immune-nutritional status is associated with poor prognosis in many critical illnesses. It has been shown in the literature, by using different immune parameters, that poor immune-nutritional status is associated with increased mortality and thrombus burden in patients with myocardial infarction. Osaka prognostic score (OPS), defined as the immune-nutritional status parameter in recent years, has been shown in the literature to be an objective and easily applicable parameter in showing the prognosis of cancer patients. In our study, we planned to investigate the relationship of Osaka prognostic score with thrombus burden in patients with ST elevation myocardial infarction (STEMI).

**Methods:** A total of 925 patients presenting with STEMI were included in this retrospective study. The patients' baseline demographics, echocardiographic data, and in-hospital follow-up data were obtained from hospital records. OPS was calculated from the biochemistry samples taken at the time of admission, using CRP, serum albumin and total lymphocyte counts values as defined in the literature. Coronary thrombus burden was calculated according to the TIMI thrombus classification. Patients with TIMI thrombus grade <3 were defined as low thrombus burden (LTB) group, and those with TIMI thrombus grade ≥3 were defined as high thrombus burden (HTB) group.

**Results:** LTB was detected in 576 patients, while HTB was detected in 349 patients. Osaka prognostic score was found to be significantly higher in the HTB group. (1.68±0.46 vs. 0.46±0.12; p = 0.002) The incidence of DM, HT, anterior MI rate and in-hospital mortality rate were also higher in the HTB group compared to the LTB group.

**Conclusion:** We found that OSP, which can be easily calculated from patients' baseline laboratory data, is associated thrombus burden in STEMI patients.

**Keywords:** Osaka prognostic score, thrombus burden, ST elevation myocardial infarction





# KARDİYOVASKÜLER AKADEMİ KONGRESİ

## & INTERNATIONAL ACADEMY OF YOUNG CARDIOLOGISTS

Elexus Hotel Girne, K.K.T.C.  
18-22 Eylül 2024

**Table 1. Basal demographic and laboratory characteristics of the patients according to the thrombus burden.**

	Low thrombus burden (n =576)	High thrombus burden (n = 349)	p
High thrombus burden (n = 349)	60.2±11.3	66.3±13.8	<0.001
Male gender, n (%)	441(76.5)	210(60.1)	<0.001
Diabetes mellitus, n (%)	194(33.6)	204(58.4)	<0.001
Hypertension, n (%)	301(52.2)	224(64.1)	<0.001
Hyperlipidemia, n (%)	321(55.8)	217(62.3)	.021
CAD, n (%)	238(41.4)	140(40.2)	.561
HF, n (%)	393(68.2)	274(78.5)	0.001
Smoking, n (%)	240(41.7)	182(52.1)	0.001
Systolic blood pressure, mm/Hg	132.7±21.4	133.7±19.2	0.105
Heart rate per minute	80.9±22.8	86.4±21.7	0.045
Left-ventricular ejection fraction (%)	43.0±10.4	40.6±10.2	0.004
Hemoglobin, g/dL	13.8±1.8	13.1±2.2	<0.001
White blood cell count, cells/μL	10.5±3.1	10.7±4.6	0.147
Platelet count, cells/μL	261.7±64.5	261.9±54.8	0.813
Lenfosit, 10 <sup>9</sup> /L	1.9±0.6	1.3±0.8	0.004
CRP, mg/L	8.6±1.9	8.8±1.3	0.196
Albumin, g/dL	41.2±5.1	36.1±3.9	0.018
Baseline creatinine, mg/dL	1.2±0.5	1.3±0.4	0.286
Peak troponin, ng/l	10692±628	11503±761	0.001
LDL, mg/dL	121.4±36.7	127.3±24.2	0.236
Osaka Prognostic Score	0.46±0.12	1.68±0.46	0.002
Multi-vessel stenosis (> 50%), n (%)	158(27.4)	92(26.5)	0.261
LAD as the infarct-related artery, n (%)	270(46.8)	226(64.7)	0.001
In-hospital mortality	21(3.6)	32(9.2)	<.001

**[OP-10] A CASE OF INFECTIVE ENDOCARDITIS PRESENTING WITH CORONARY EMBOLISM**



# KARDİYOVASKÜLER AKADEMİ KONGRESİ

## & INTERNATIONAL ACADEMY OF YOUNG CARDIOLOGISTS

Elexus Hotel Girne. K.K.T.C.  
18-22 Eylül 2024

Fatma Esin<sup>1</sup>, Gökhun Akkan<sup>2</sup>, *Bahadır Akar*<sup>1</sup>, Uğur Kocabaş<sup>1</sup>

<sup>1</sup>*Katip Çelebi University Medical School Cardiology Department*

<sup>2</sup>*Nazilli State Hospital Cardiology Department*

**INTRODUCTION:** Coronary embolism has replaced non-atherosclerotic causes as a rare etiology in the pathogenesis of acute coronary syndromes. Due to its rarity or difficulty in diagnosing during the acute process, there is insufficient data regarding its prevalence. Clinically significant coronary embolism has been reported in 1.5% of cases with infective endocarditis and micro-emboli to the coronary arteries were present in more than 60% of cases on postmortem examination.

**CASE REPORT:** A 46-year-old male patient was admitted to our emergency department with anginal chest pain that started 1 hour ago. In his medical history, there was a hospitalization one month ago due to ischemic stroke at an external facility. Other than that, he did not have any chronic illnesses. ST elevation in the inferior leads and reciprocal changes in the lateral leads were observed on the electrocardiogram (ECG) (Figure 1).

In laboratory tests troponin I (416 ng/L) and CRP (151 mg/L) were markedly elevated. The patient was admitted to the catheter laboratory with a preliminary diagnosis of STEMI. The vessels were observed to be normal in coronary angiography. During the patient's follow-up, the ST elevations and reciprocal changes in the ECG resolved. It was thought that it might be coronary embolism.

The echocardiogram showed an ejection fraction of 60%, and it was observed that the mitral valves were myxomatous, with moderate to severe mitral regurgitation. On transesophageal echocardiography, it was observed that the mitral leaflets were myxomatous, both leaflets were prolapsed, there was chordal rupture and severe mitral regurgitation. Additionally, on the atrial side of the leaflets, hypoechoic masses, approximately 4-5 in total, with a length of 3-4 mm each, were observed, which were considered compatible with vegetations (Figure 2).

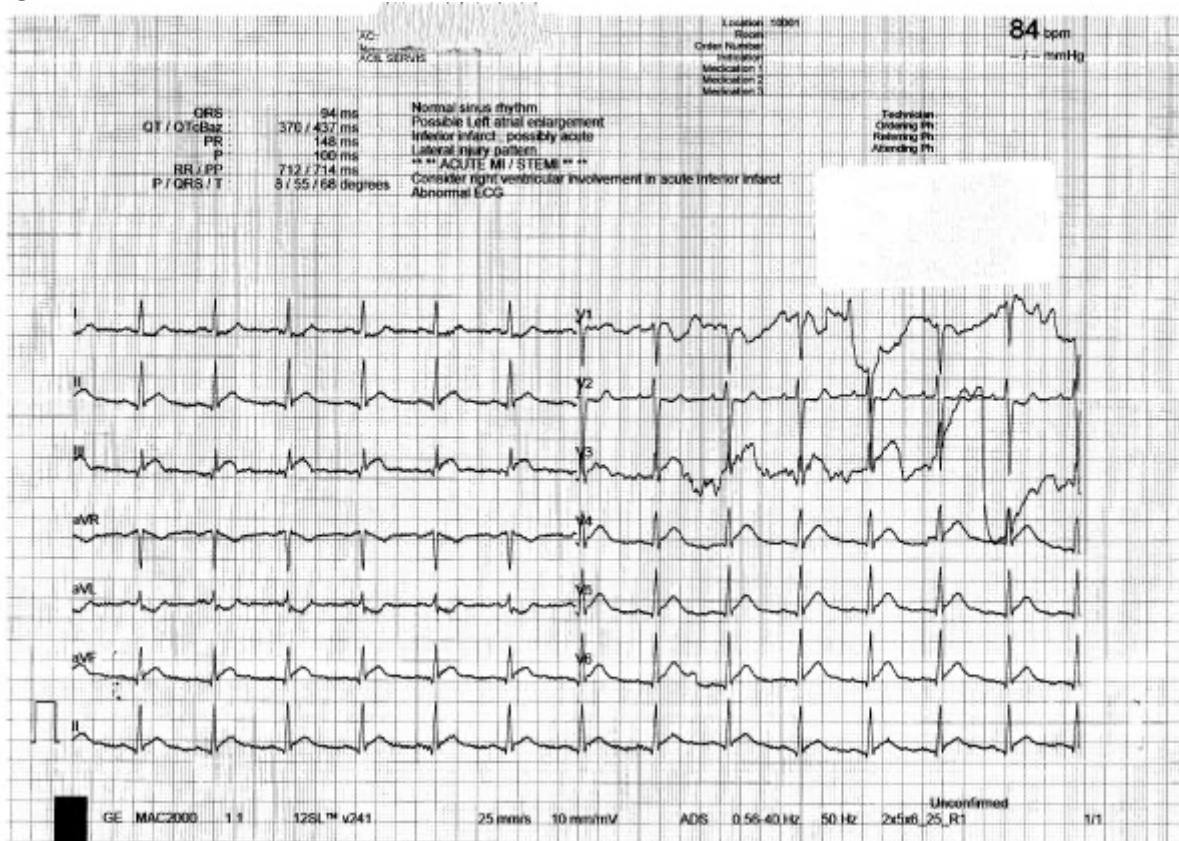
Antibiotic therapy has been initiated. Streptococcus mitis grew in blood cultures. Surgical decision was made in the cardiology-cardiovascular surgery council. However, while preparations for surgery were being made, the patient suffered another ischemic stroke and unfortunately passed away.

**DISCUSSION AND CONCLUSION:** The coronary arteries appear relatively protected anatomically from embolic events compared with the other systemic circulation. Thromboemboli originating in the left ventricle or left atrium most commonly pass into the carotids or distal systemic circulation because these vessels are in a relatively linear trajectory from the left ventricular outflow tract compared with the coronaries. Despite these protections, coronary embolism can still occur.

It is crucial to thoroughly investigate the sources of emboli in patients suspected of coronary embolism during coronary angiography. These patients should undergo transthoracic echocardiography, and if there is suspicion, transesophageal echocardiography should be performed to identify the source of the embolism and determine treatment accordingly.

**Keywords:** Acute coronary syndrome, coronary embolism, infective endocarditis

Figure 1



The patient's ECG at the emergency department. ST elevation in the inferior leads and reciprocal changes in the lateral leads were observed on the ECG.

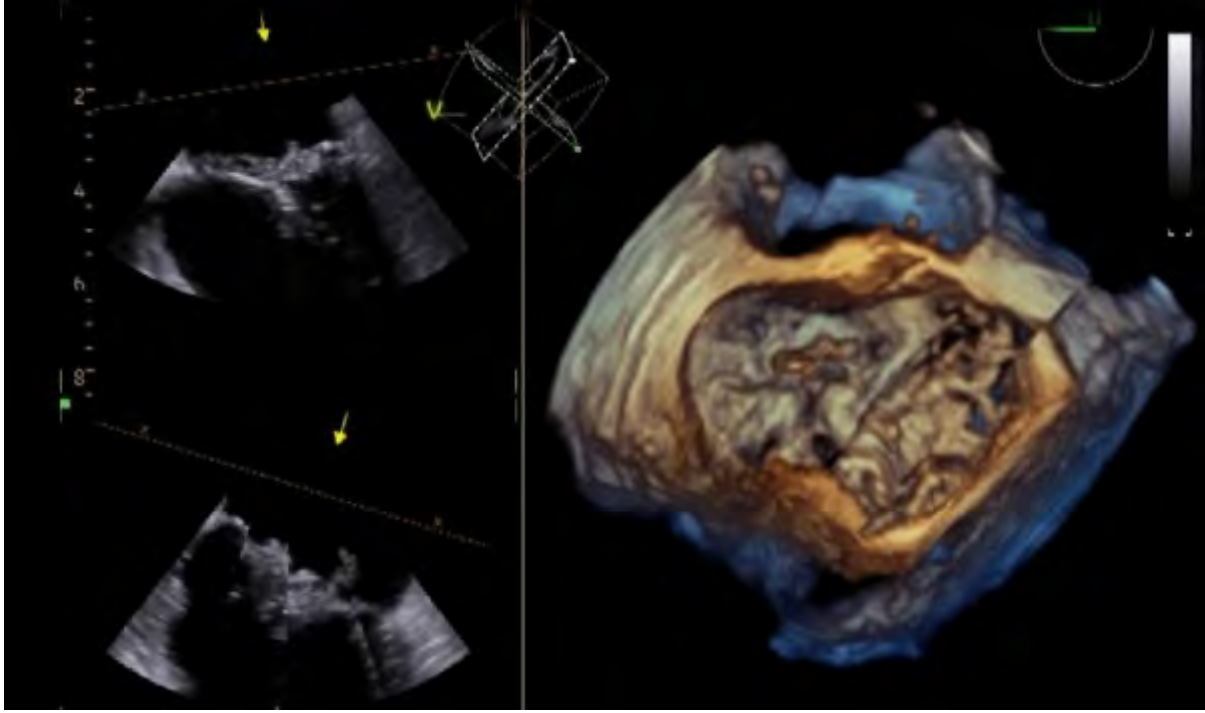


# KARDİYOVASKÜLER AKADEMİ KONGRESİ

## & INTERNATIONAL ACADEMY OF YOUNG CARDIOLOGISTS

Elexus Hotel Girne. K.K.T.C.  
18-22 Eylül 2024

Figure 2



*On the atrial side of the leaflets, hypoechoic masses, approximately 4-5 in total, with a length of 3-4 mm each, were observed, which were considered compatible with vegetations.*



# KARDİYOVASKÜLER AKADEMİ KONGRESİ

## & INTERNATIONAL ACADEMY OF YOUNG CARDIOLOGISTS

Elexus Hotel Girne. K.K.T.C.  
18-22 Eylül 2024

### **[OP-11] Usability of Neutrophil Percentage to Albumin Ratio in Predicting New Onset Atrial Fibrillation in ST Elevation Myocardial Infarction Patients**

Ahmet Özderya<sup>1</sup>, Yahya Dağcan Bıçakçı<sup>2</sup>, Muhammet Raşit Sayın<sup>2</sup>

<sup>1</sup>Department of Cardiology, Trabzon Kanuni Training and Research Hospital Cardiology Clinic, Trabzon, Turkey.

<sup>2</sup>Department of Cardiology, University of Health Sciences Trabzon Ahi Evren Thoracic and Cardiovascular Surgery Training and Research Hospital, Trabzon, Turkey

**Introduction:** The aim of this study is to investigate the relationship between Neutrophil percentage-to-albumin ratio (NPAR) and new-onset AF (NOAF) in patients with ST elevation myocardial infarction (STEMI).

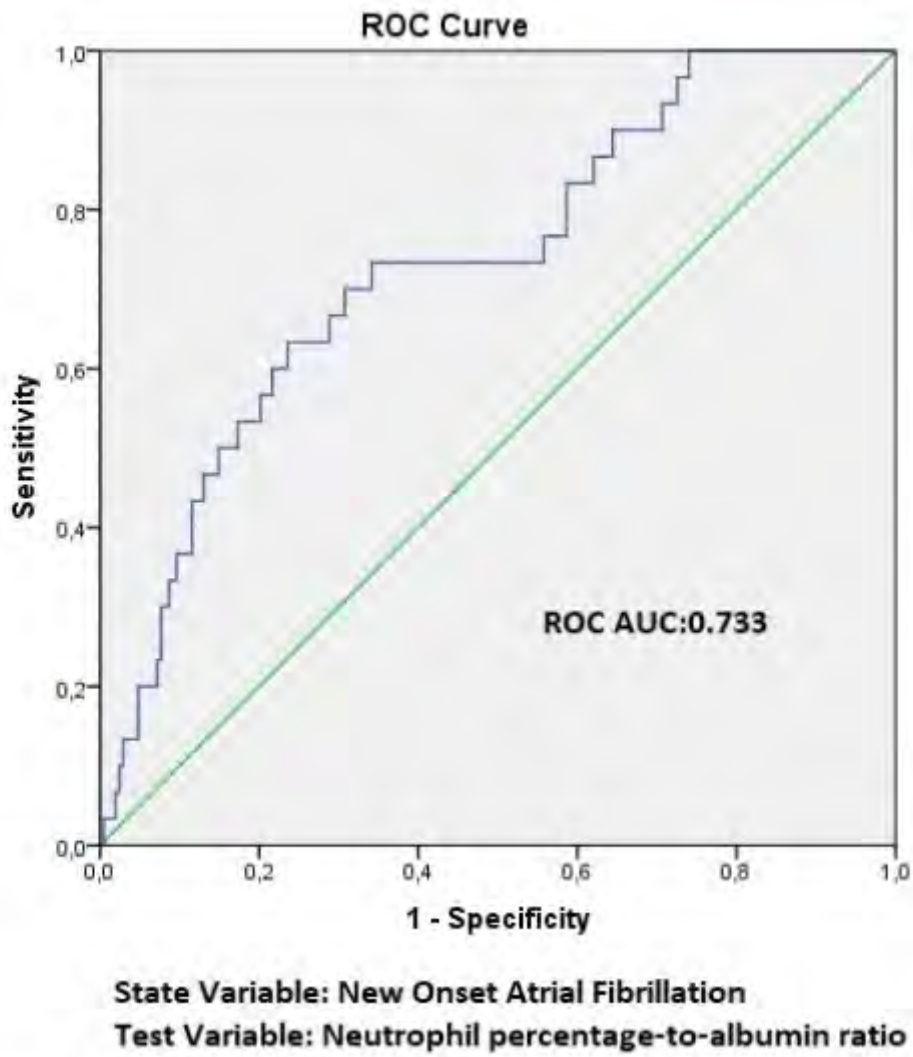
**Material-Methods:** Our study included 476 STEMI patients between September 2019 and May 2023. Monitoring records and ECGs were examined during their hospitalization. NOAF was detected in 60 (12.6%) patients. The remaining 416 (87.4%) patients were included in the control group. Statistical analysis was performed between the two groups by calculating the NPAR in the patients.

**Results:** Demographic characteristics, blood parameters and echocardiographic values of the individuals included in the study are given in Table-1. NPAR was statistically increased in the NOAF group [0.22 (0.15-0.33) vs. 0.18 (0.07-0.34)  $p < 0.001$ ]. The correlation between NOAF and NPAR was determined by Spearman correlation test ( $p < 0.001$ ). In the multivariable logistic regression analysis model performed to determine the predictors of NOAF detection, age ( $p = 0.007$ ), E/E' ( $p = 0.002$ ), Left atrium ( $p < 0.001$ ) and NPAR ( $p < 0.001$ ) were found to be independent predictors for NOAF. In the ROC curve analysis for the estimation of NOAF detection, the NPAR cut-off value was found to be 0.1987 with 70% Sensitivity and 69.2% Specificity. (area under curve: 0.733, 95 % CI, 0.666-0.799,  $p < 0.001$ ; Figure 1)

**Discussion and Conclusion:** NPAR is an independent predictor of NOAF detection in STEMI patients and is an easily accessible method in clinical practice. Closer follow-up of patients may be required, as it is associated with early treatment of risk factors and poor prognosis of patients who may develop AF.

**Keywords:** Neutrophil Percentage to Albumin Ratio, Atrial Fibrillation, Myocardial Infarction

Figure 1



*Receiver operating characteristic curve of neutrophil percentage to albumin ratio to predict new onset atrial fibrillation*



# KARDİYOVASKÜLER AKADEMİ KONGRESİ

## & INTERNATIONAL ACADEMY OF YOUNG CARDIOLOGISTS

Elexus Hotel Girne, K.K.T.C.  
18-22 Eylül 2024

**Table 1**

	New onset AF n=60	Control Group n=416	
Age (years)	69.5±12.52	61.38±13.02	<0.001 a
Sex (F/M) (n) (%)	38 / 22	330 / 86	0.006 b
BMI (kg/m <sup>2</sup> )	33.1 (22.04-40.60)	29.06 (20.08-46.57)	<0.001c
Hypertension (n)	52 (%86)	212 (%51)	<0.001 b
Diabetes Mellitus (n)	22 (%36)	80 (%19.2)	0.002 b
Hyperlipidemia (n)	38 (%63)	86 (%20.6)	<0.001 b
Smoking (n)	42 (%70)	260 (%62.5)	0.259 b
Hemoglobin (g/dL)	13.35 (8.6-16.3)	14.1 (8.6-18.3)	0.002 c
WBC (×10 <sup>9</sup> /L)	11.77 (5.34-22.25)	10.38 (4.26-22)	0.051 c
RDW (%)	13.95 (12.1-15.7)	13.3 (11.1-17.2)	0.109 c
PLT (×10 <sup>9</sup> /L)	227 (158-374)	223 (115-453)	0.295 c
Lymphocyte (x10 <sup>3</sup> /μL)	1.33 (0.52-2.5)	1.66 (0.46-6.73)	<0.001 c
Neutrophil (x10 <sup>3</sup> /μL)	9.27 (4.22-19.82)	7.39 (2.08-18.4)	<0.001 c
MPV (fl)	9.0±0.97	8.76±0.94	0.135 a
Creatinine (mg/dL)	0.97 (0.43-1.53)	0.89 (0.32-3.35)	0.016 c
Glucose (mg/dL)	118 (94-394)	119.5 (81-471)	0.691 c
CRP (mg/dL)	1.45 (0.43-1.53)	2.03 (0.1-25.46)	0.377 c
Albumin (g/dL)	3.86 (2.6-5.14)	4.18 (2.4-5.05)	0.001 c
LDL-C (mg/dL)	144.5 (64-292)	135 (48-276)	0.018 c
HDL-C (mg/dL)	39 (18-63)	40.5 (21-74)	0.256 c
Total Cholesterol (mg/dL)	168 (118-323)	192 (106-420)	0.091 c
Triglyceride (mg/dL)	125 (45-472)	108 (27-465)	0.024 c
Hs-Troponin I (ng/L)	59.37 (3.81-129.86)	47.84 ( 0.61-425)	0.663 c
LV-EF (%)	46 (25-60)	45 (20-65)	0.167 c
E/E'	15.61±2.61	12.28±2.61	<0.001 a
LA (mm)	36.74±3.34	31.9±5.28	<0.001 a
NPAR	0.22 (0.15-0.33)	0.18 (0.07-0.34)	<0.001 c

*Table 1: Comparison of the Clinical characteristics and Echocardiographic parameters*





# KARDİYOVASKÜLER AKADEMİ KONGRESİ

## & INTERNATIONAL ACADEMY OF YOUNG CARDIOLOGISTS

Elexus Hotel Girne, K.K.T.C.  
18-22 Eylül 2024

### **[OP-12] The Relationship Between Echocardiographically Determined Systolic Pulmonary Arterial Pressure and Blood Lipid Levels**

Nedret Ülvan, Hafize Corut Güzel

*Ankara Bilkent City Hospital, Cardiology Clinic*

**Introduction:** Hyperlipidemia is a well-known metabolic marker of cardiovascular risk, however its role in pulmonary hypertension (PH) has not yet been fully established. Therefore, we evaluated whether total cholesterol (TC)/HDL, LDL/HDL, and Triglyceride/HDL levels, which are new applications in clinical practice, change in PH patients.

**Material and Method:** A total of 89 males (51.7%) and 83 females (48.3%) with systolic pulmonary artery pressure (sPAP) of 40 mmHg and above who underwent transthoracic echocardiography were included in the study. TC/HDL, LDL/HDL and Triglyceride/HDL ratios were obtained from the fasting blood biochemistry values of the patients. These values were statistically compared with the SPSS 21 program.

**Results:** Type 2 diabetes mellitus in 32% of the patients (n=55), hypertension in 41.3% (n=71), family history of coronary artery disease in 22.7% (n=39) and smoking in 57.6% (n=99) were present. The mean sPAP value (mmHg) was  $58.3 \pm 12.8$  in females; in males, it was  $57.1 \pm 12.8$ . There was a statistically significant positive correlation between sPAB values and TC/HDL, LDL/HDL and triglyceride/HDL ( $p < 0.001$ ,  $r = 0.285$ ;  $p < 0.001$ ,  $r = 0.310$ ; and  $p = 0.035$ ,  $r = 0.161$ , respectively). The TC/HDL ( $\geq 4.1$ ) ratio was found to be predictive of the possibility of severe pulmonary hypertension (sPAB  $\geq 60$  mmHg) with 64% sensitivity - 54% specificity [ $p < 0.001$ , AUC: 0.656, 95% CI (0.575-0.737)]. Similarly, LDL/HDL ( $\geq 2.6$ ) and triglyceride/HDL ( $\geq 2.7$ ) were found to be predictive of severe pulmonary hypertension with 60% sensitivity - 56% specificity [ $p = 0.002$ , AUC: 0.640, 95% CI (0.558-0.723)] and 60% sensitivity - 51% specificity [ $p = 0.024$ , AUC: 0.600, 95% CI (0.516-0.685)] respectively.

**Discussion:** In conclusion, our research provides innovative diagnostic and prognostic biomarkers, and highlights the importance of lipidemic changes in PH

**Keywords:** Pulmonary hypertension, TC/HDL, LDL/HDL, Triglyceride/HDL



# KARDİYOVASKÜLER AKADEMİ KONGRESİ

## & INTERNATIONAL ACADEMY OF YOUNG CARDIOLOGISTS

Elexus Hotel Girne. K.K.T.C.  
18-22 Eylül 2024

### [OP-15] Association Between Uric Acid Albumin Ratio in Cardiac Patients Undergoing Cardiac Rehabilitation

Koray Kalenderoglu<sup>1</sup>, Nazmiye Ozbilgin<sup>1</sup>, Basak Bilir Kaya<sup>2</sup>

<sup>1</sup>Department of Cardiology, Health Sciences University, Dr Siyami Ersek Cardiovascular and Thoracic Surgery Center, Istanbul, Turkey

<sup>2</sup>Department of Physical Medicine and Rehabilitation, Erenköy Physical Therapy and Rehabilitation Hospital, Istanbul, Turkey

**Background:** Uric acid/albumin ratio (UAR) has recently admitted in the literature as a predictor of adverse cardiovascular events. Although, thoroughly mechanisms linking high uric acid levels to cardiovascular diseases are still unclear, uric acid has been shown to be one of the mediators of endothelial dysfunction, inflammation, and vascular disease. Increased inflammatory response has been associated with decreased serum albumin synthesis and increased catabolism. Low serum albumin levels can increase blood viscosity and impair endothelial function.

Cardiac rehabilitation(CR) is defined as the provision of comprehensive long-term services that include medical evaluation, prescribed exercise, cardiac risk factor modification, education, counseling, and behavioral interventions. Many studies have shown that exercise-based CR has significant benefits in reducing cardiovascular mortality and morbidity. In this study, we investigated the effectiveness of UAR before and after CR in cardiac patients.

**Methods:** We retrospectively analyzed hospital records and studied 155 cardiac patients treated with 30 sessions of CR between January 2017 and November 2018.

**Results:** A total number of 155 patients (57%, n:88 men) with a mean age 55.7±10.1 were enrolled for this study. C-reactive protein(CRP), body mass index, systolic blood pressure and diastolic blood pressure levels were detected as 0.77 ± 0.62, 30.1 ± 5.1, 131.5 ± 14.4 mmHg, 82.3 ± 8.1 mmHg before and 0.53 ± 0.38, 29.7 ± 5.0, 122.1 ± 14.7mmHg, 77.5 ± 9.1 mmHg after rehabilitation, respectively (P<0.001) Although there was no significant difference in uric acid levels before and after 30 sessions of CR, a significant difference was detected in albumin levels (before CR 5.3 ± 0.7, 4.3 ± 0.71 and after CR 5.3 ± 1.2, 4.5 ± 0.51). Uric acid/albumin ratio was reduce after rehabilitation (before CR 1.26± 0.8 0.0(0.0-2.0) after CR 1.21± 0.32 0.0(0.0-0.0))(P<0.05).

**Conclusion:** In conclusion, CR may help reduce UAR, an inexpensive and simple laboratory parameter which are directly related to mortality in cardiac patients, and increases the functional capacity of patients.

**Keywords:** uric acid/albumin ratio, cardiac rehabilitation, inflammation



# KARDİYOVASKÜLER AKADEMİ KONGRESİ

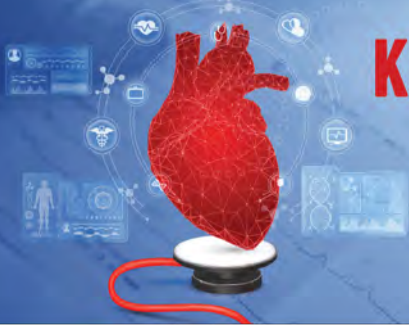## & INTERNATIONAL ACADEMY OF YOUNG CARDIOLOGISTS

Elexus Hotel Girne, K.K.T.C.  
18-22 Eylül 2024

### Clinical Characters and Laboratory Parameters

	Pre-CR	Post-CR	P value
Body mass index	30.1 ± 5.1	29.7 ± 5.0	<0.001
Heart rate	77.3 ± 8.0	75.4 ± 10.3	0.106
Systolic blood pressure	131.5 ± 14.4	122.1 ± 14.7	<0.001
Diastolic blood pressure	82.3 ± 8.1	77.5 ± 9.1	<0.001
Albumin (g/dl)	4.3 ± 0.71	4.5 ± 0.51	<0.001
Triglycerides	124 ± 47	134 ± 60	0.145
Total cholesterol	210 ± 30	205 ± 24	0.008
LDL	132 ± 29	128 ± 20	0.003
HDL	51 ± 11	50 ± 10	0.777
ESR	21.4 ± 10.3	21.8 ± 12.3	0.813
CRP	0.77 ± 0.62	0.53 ± 0.38	<0.001
WBC	7.1 ± 1.6	6.8 ± 1.4	<0.001
Platelet	264 ± 51	261 ± 60	0.252
Neutrophils	3.9 ± 1.3	3.6 ± 1.1	0.001
Lymphocytes	2.3 ± 0.8	2.5 ± 0.6	0.003
Uric acid	5.3 ± 0.7 5.3 ± 1.2 0.620	5.3 ± 1.2	0.620
Uric acid/albumin ratio	1.26 ± 0.8 0.0 (0.0 – 2.0)	1.21 ± 0.32 0.0 (0.0 – 0.0)	0.009

CR:cardiac rehabilitation,LDL:low-density lipoprotein,HDL:high-density lipoprotein,ESR:erythrocyte sedimentation rate, CRP:C-reactive protein,WBC:white blood cell



# KARDİYOVASKÜLER AKADEMİ KONGRESİ

## & INTERNATIONAL ACADEMY OF YOUNG CARDIOLOGISTS

Elexus Hotel Girne, K.K.T.C.  
18-22 Eylül 2024

### [OP-16] Predictive capability of modified Bedside shock index in patients with ST segment elevation myocardial infarction

Bektaş Murat<sup>1</sup>, Cihat Çalışkan<sup>2</sup>, Fatih Enes Durmaz<sup>2</sup>, Fatih Aydın<sup>1</sup>, Selda Murat<sup>2</sup>

<sup>1</sup>Department of Cardiology, Eskisehir City Hospital, Eskisehir, Turkey

<sup>2</sup>Department of Cardiology, Eskisehir Osmangazi University, Eskisehir, Turkey

**Objectives:** The aim of study was to evaluate the predictive capability of, bedside shock index (SI), modified SI (MSI) age-SI (A-SI) and age-MSI for major adverse cardiovascular vents (MACE) in patients with ST segment elevation myocardial infarction (STEMI) who undergone primary percutaneous intervention (PPCI)

**Methods:** Patients with STEMI who undergone PPCI at two tertiary center were included in this study. The Bedside SI was calculated as the ratio of heart rate (HR)/ systolic blood pressure (SBP), Age-SI was calculated as the age x SI, MSI was calculated as the ratio of HR to mean arterial pressure (MAP), where MAP is calculated using the formula  $(2 \times \text{diastolic blood pressure} + \text{SBP})/3$ . Age-MSI (A-MSI) was calculated as age x MSI. All patients were monitored throughout their hospitalization. Major Adverse Cardiovascular Events were recorded as any of the following: re-infarction, stroke, cardiogenic shock, arrhythmias (VT/VF) or death.

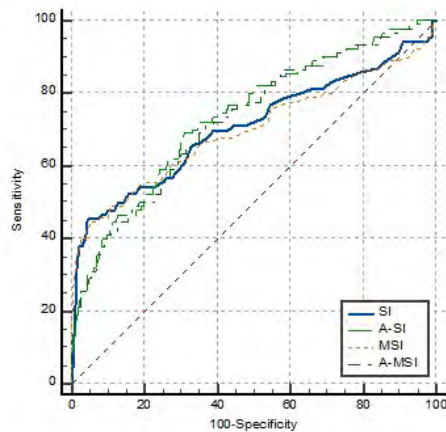
**Results:** A total of 480 patients were included out of which 380 (79.2%) were male and mean age was  $50.5 \pm 16.9$  years. Other demographic, laboratory and clinical characteristics are presented in Table 1. In-hospital MACE was observed in 90 (18.8%) patients which comprises of 19 (4%) re-infarction, 2 (0.4%) stroke, 36 (7.5%), cardiogenic shock, 54 (11.3%) arrhythmias (VT/VF), and 25 (5.2%) death.

The ROC curve analysis for SI (AUC: 0.707, sensitivity 45.6%, specificity 95.1%,  $p < 0.001$ ), A-SI (AUC: 0.736, sensitivity 68.8%, specificity 69.0%,  $p < 0.001$ ), MSI (AUC: 0.698, sensitivity 44.4%, specificity 94.9%,  $p < 0.001$ ), and A-MSI (AUC: 0.727, sensitivity 71.1%, specificity 63.2%,  $p < 0.001$ ), MACE are shown in Fig 1.

**Conclusion:** A-SI and A-MSI can be utilized as straightforward risk classification tools with a moderate predictive value in identifying the risk of MACE within the hospital for patients with STEMI patients. These indices can be considered effective screening tools for identifying high-risk patients.

**Keywords:** ST segment elevation myocardial infarction, Bedside shock index, outcome

**SI: Shock Index (SI), MSI: Modified SI, A-SI: Age-SI, A-MSI: Age-MSI**



SI: Shock Index (SI), MSI: Modified SI, A-SI: Age-SI, A-MSI: Age-MSI





# KARDİYOVASKÜLER AKADEMİ KONGRESİ

## & INTERNATIONAL ACADEMY OF YOUNG CARDIOLOGISTS

Elexus Hotel Girne, K.K.T.C.  
18-22 Eylül 2024

### Clinical features of acute coronary syndrome according to MACE

	MACE (+)	MACE (-)	p value
	(n=90)	(n=390)	<0.001
Age, years, $\pm$ SD	56.4 $\pm$ 17.6	49.2 $\pm$ 16.4	0.349
Male, n(%)	68 (75.6%)	312 (%80)	0.341
HT, n(%)	35 (38.9%)	131 (33.6%)	<0.001
DM, n(%)	35 (38.9%)	83 (21.3%)	0.903
Smoking, n(%)	49 (54.4%)	214 (55.2%)	0.004
HR, beats/minute, $\pm$ SD	90.6 $\pm$ 28.1	81.6 $\pm$ 12.7	0.002
Hemoglobin, g/dl, $\pm$ SD	14.3 $\pm$ 2.1	15.1 $\pm$ 1.6	0.003
Creatinine, mg/dL, $\pm$ SD	1.1 $\pm$ 0.5	0.9 $\pm$ 0.5	<0.001
LVEF, %, $\pm$ SD	43.8 $\pm$ 11.5	51.9 $\pm$ 9.5	<0.001
SI	0.9 $\pm$ 0.4	0.6 $\pm$ 0.2	<0.001
MSI	1.3 $\pm$ 0.5	0.9 $\pm$ 0.2	<0.001
A-SI	54.5 $\pm$ 31.0	33.6 $\pm$ 14.6	<0.001
A-MSI	73.5 $\pm$ 41.3	46.0 $\pm$ 19.0	<0.001
Coronary Angiography Duration, minute, $\pm$ SD	36.5 $\pm$ 14.2	31.5 $\pm$ 11.3	0.014
Coronary care stay, [IQR]	4.6 (2.0-5.5)	2.5 (2.0-3.0)	0.001
Ward stay, [IQR]	2.2 $\pm$ (1.0-3.0)	1.8 (1.0-2.0)	0.276
Total length of stay, $\pm$ SD	6.5 $\pm$ 5.2	4.1 $\pm$ 2.5	<0.001

*Clinical features of acute coronary syndrome according to MACE*



# KARDİYOVASKÜLER AKADEMİ KONGRESİ

## & INTERNATIONAL ACADEMY OF YOUNG CARDIOLOGISTS

Elexus Hotel Girne, K.K.T.C.  
18-22 Eylül 2024

### [OP-17] Coronary Slow Flow is Associated with Anxiety and Depression but not Adverse Childhood Experiences and Alexithymia

Hayriye Mihrimah Ozturk<sup>1</sup>, Ibrahim Halil Inanç<sup>2</sup>, Mehmet Cilingiroglu<sup>3</sup>, Yasar Turan<sup>4</sup>, Huseyin Kandemir<sup>2</sup>, Selcuk Ozturk<sup>2</sup>

<sup>1</sup>Kırıkkale University Faculty of Medicine, Department of Psychiatry, Kırıkkale, Turkey

<sup>2</sup>Kırıkkale Yuksek Ihtisas Hospital, Department of Cardiology, Kırıkkale, Turkey

<sup>3</sup>The University of Texas MD Anderson Cancer Center, Department of Cardiology, Houston, TX USA

<sup>4</sup>Istanbul Yeni Yuzyil University Faculty of Medicine, Department of Cardiology, Istanbul, Turkey

**Objective:** The literature concerning the association between coronary slow flow (CSF) and, anxiety and depression are controversial. Besides, there is no data in the literature whether an association exists between CSF and adverse childhood experiences (ACE) and/or alexithymia. The study aimed to investigate the relationship between CSF and psychosocial conditions including anxiety, depression, alexithymia, and ACE.

**Methods:** The participants underwent coronary angiography through femoral route. Coronary artery blood flow rate was evaluated quantitatively for each coronary artery according to the Thrombolysis in Myocardial Infarction frame count (TFC) method. CSF was diagnosed as a corrected TFC value >27 in at least one coronary artery. Symptoms of anxiety and depression were assessed through Hospital Anxiety and Depression Scale (HADS). Alexithymia and ACE were evaluated by Twenty-item Toronto Alexithymia Scale (TAS-20) and Childhood Trauma Questionnaire (CTQ).

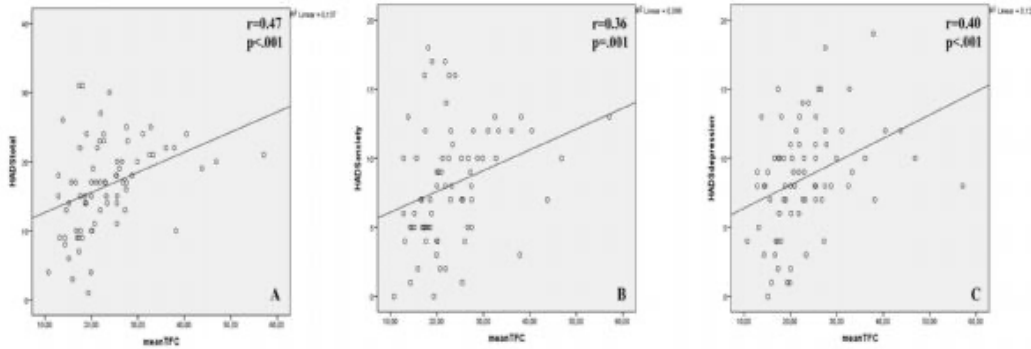
**Results:** The study participants were categorized into two groups, namely normal coronary flow (n=58) and CSF (n=18). Total HADS score, HADS anxiety subscale (HADS-A) score and HADS depression subscale (HADS-D) score were all significantly higher in CSF group patients than NCF group patients. Total TAS-20 and CTQ score and their subfactor scores were all comparable between groups. Correlation analyses of mean TFC calculation, and total HADS score ( $r=0.47$ ,  $p<.001$ ), HADS-A score ( $r=0.36$ ,  $p=.001$ ) and HADS-D score ( $r=0.40$ ,  $p<.001$ ) revealed positive and moderate correlation (Figure 1). On the other hand, there were no correlation among mean TFC calculation, and total TAS-20 and CTQ scores ( $p>.050$  for both). Total HADS score, HADS-A score and HADS-D score were determined as significant factors associated with CSF in univariate logistic regression analysis. However, TAS-20 score and CTQ score did not associate with CSF. Multivariate regression analysis performed in separate models demonstrated total HADS score (Odds ratio [OR]:1.27, 95% Confidence interval [CI]:1.08-1.50,  $p=.003$ ), HADS-A score (OR:1.25, 95 CI%:1.03-1.51,  $p=.019$ ) and HADS-D score (OR:1.36, 95 CI%:1.06-1.74,  $p=.014$ ) as independent predictors of CSF in multivariate logistic regression analysis (Table 1).

**Conclusion:** Neither alexithymia nor ACE is associated with CSF. On the other hand, measures of both anxiety and depression assessed through HADS independently associate with CSF.

**Keywords:** Alexithymia, anxiety, childhood trauma, coronary slow flow, depression



**Figure 1**



Correlation between mean TIMI frame count calculation and total HADS score (A), HADS anxiety score (B), and HADS depression score (C). HADS= Hospital anxiety depression scale, TIMI= Thrombolysis in myocardial infarction.

**Table 1**

Table 1. Predictors of CSF by logistic regression analysis				
	Univariate		Multivariate*	
	Odds Ratio (95%CI)	p value	Odds Ratio (95%CI)	p value
HADS-Total score	1.13 (1.02-1.24)	.012	1.27 (1.08-1.50)	.003
HADS-Anxiety score	1.14 (1.00-1.30)	.043	1.25 (1.03-1.51)	.019
HADS-Depression score	1.21 (1.03-1.41)	.015	1.36 (1.06-1.74)	.014
TAS-20 total score	0.99 (0.95-1.04)	.844	..	..
CTQ score	0.98 (0.93-1.03)	.460	..	..

\* Adjusted to gender, height, hyperlipidemia and antiplatelet usage

**Abbreviations:** CI=Confidence interval, CSF=Coronary slow flow, CTQ=Childhood trauma questionnaire, HADS=Hospital anxiety depression scale, TAS=Toronto alexithymia scale.

*Predictors of CSF by logistic regression analysis*

**AuthorToEditor:** To the Editor, On behalf of my co-authors, I would like to submit the enclosed abstract for oral presentation entitled “Coronary Slow Flow is Associated with Anxiety and Depression but not Adverse Childhood Experiences and Alexithymia”. The manuscript has not been accepted for publication in any journal yet. I hope that you may find it worthy of oral presentation in the congress. I kindly look forward for the result of the manuscript. Sincerely yours, Corresponding author: Selcuk OZTURK Assoc. Prof. MD, Kirikkale Yuksek Ihtisas Hospital, Department of Cardiology, Kirikkale, Turkey. Correspondence to S.O



# KARDİYOVASKÜLER AKADEMİ KONGRESİ

## & INTERNATIONAL ACADEMY OF YOUNG CARDIOLOGISTS

Elexus Hotel Girne, K.K.T.C.  
18-22 Eylül 2024

### [OP-18] Importance of the Triglyceride High-Density Lipoprotein Ratio for Assessing Multivessel Disease in Hypertensive Patients Undergoing Coronary Computed Tomographic Angiography

Sidar Şiyar Aydın, Oğuzhan Birdal, Ferih Özcanlı

*Atatürk University, Faculty of Medicine, Department of Cardiology*

**Objective:** Hypertension (HT) is considered the most common cardiovascular disease all over the world. Research in epidemiology demonstrates that 31% of adults suffer from HT, with projections suggesting a further increase in the future. Previous studies have shown that there is a relationship between HT and dyslipidemia. Recently, there has been a rise in the use of the triglyceride high-density lipoprotein (HDL) ratio (THR) as a parameter. There is a notion that THR may be closely associated with both insulin resistance and Diabetes Mellitus (DM). In addition, DM was one of the well-known risk factors for multivessel disease. In light of these findings, our study aimed to evaluate the predictive power of THR in detecting multivessel coronary artery disease in patients diagnosed with HT who underwent coronary computed tomographic angiography (CTTA).

**Materials-Methods:** The study conducted at our hospital's cardiology outpatient clinic in 2023 involved 197 HT patients with chest pain who had undergone CCTA. The hemogram and biochemical parameters of the patients were recorded. THR was calculated. Patients were classified as having multivessel disease (MVD) if their CCTA reports showed  $\geq 70\%$  of lesions in at least two epicardial coronary arteries. A comparison of demographic, laboratory, and clinical characteristics was made between patients with and without MVD.

**Results:** Out of the patients, 19.2% (38 individuals) were diagnosed with MVD. Patients with MVD had an average age of  $62.7 \pm 8.7$ , while those without MVD had an average age of  $55.3 \pm 8.9$ , indicating a significant statistical difference ( $p < 0.001$ ). In addition, Coronary calcium score (CCS), gamma-glutamyl transferase (GGT), HbA1c, triglyceride, and THR showed statistically significant differences between the two groups. The multivariate logistic regression analysis revealed that CCS and THR were independent predictors for the identification of MVD (OR: 1.014 (1.002-1.026) ( $p = 0.019$ ), OR: 1.490 (1.057-2.100) ( $p = 0.023$ ), respectively). ROC analysis was used to examine the discriminative ability of THR in detecting MVD. The area under the curve for THR was 0.647 (95% CI = 0.542-0.753;  $p = 0.008$ ), the cut-off was 4.15, and the sensitivity and specificity were 58.8% and 58.1%.

**Conclusion:** The study results indicated that THR independently predicted the detection of MVD. HT and dyslipidemia are associated with adverse cardiovascular outcomes. At the same time, MVD also increases the rate of adverse cardiovascular outcomes. THR first showed a high correlation with insulin resistance in patients with DM. In addition, high THR was found to be associated with serious coronary artery disease in patients with insulin resistance without DM. Since high THR is associated with both DM and atherosclerosis, it supports the results of our study. In conclusion, in addition to traditional cardiovascular risk factors, high levels of THR in patients with HT may predict the risk of MVD.

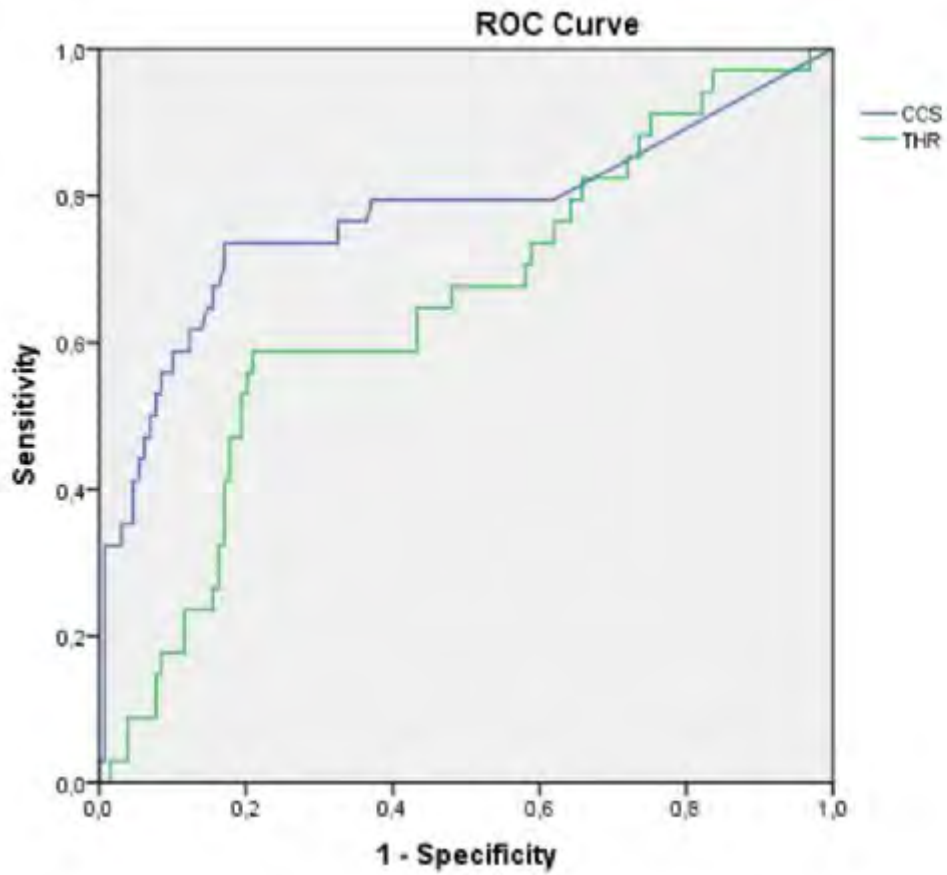
**Keywords:** Hypertension, Multivessel disease, Triglyceride High-Density Lipoprotein Ratio

# KARDİYOVASKÜLER AKADEMİ KONGRESİ

## & INTERNATIONAL ACADEMY OF YOUNG CARDIOLOGISTS

Elexus Hotel Girne, K.K.T.C.  
18-22 Eylül 2024

Figure 1



ROC Curve Analysis



# KARDİYOVASKÜLER AKADEMİ KONGRESİ

## & INTERNATIONAL ACADEMY OF YOUNG CARDIOLOGISTS

Elexus Hotel Girne, K.K.T.C.  
18-22 Eylül 2024

### [OP-19] Floating stent in the aorta, thought to be jailed after being stripped

Hüseyin Kandemir, Mustafa Karakurt, Selçuk Öztürk  
*Kırıkkale Yüksek İhtisas Hastanesi*

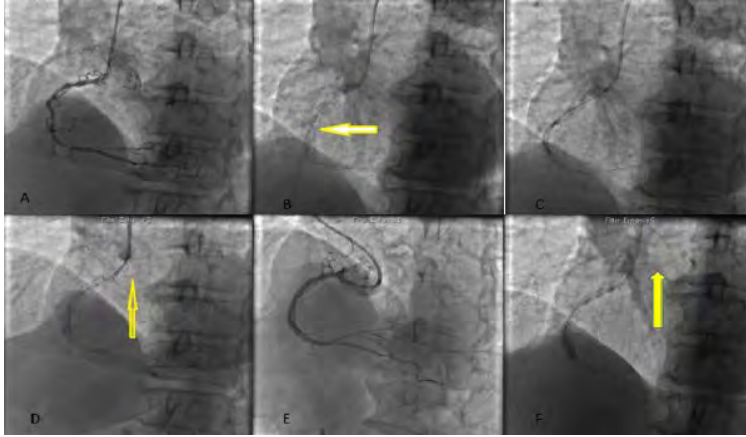
A 71-year-old male patient, who had previously refused to undergo bypass, was diagnosed with USAP. During coronary angiography, a decision was made to intervene in the right coronary artery. With 6FJR4 guiding catheter support, the microcatheter and fielder xt wire were passed to the PLA distal, and after control with tip injection, the wire was changed with 0.014 inch sion blue. It was predilated with a 1.5x20mm sc balloon and then with 2.5x15mm NC balloons at high pressures from the PLA to proximally. The decision was made to stent proximally from the PLA. However, the 2.5x 40 mm drug-eluting stent could not be passed through the acute margin branch level. Then it was dilated again. However, when the stent did not advance distally, the decision was made to perform proximal stenting first. A 3.5x44mm drug-coated stent was implanted proximally towards the trunk. Then, while the 2.5x40mm stent was taken again and tried to be passed distally with the support of the guideliner, it was observed that the stent was stuck to the guideliner and peeled off. Thereupon, the guideliner and stent complex was removed. It was observed that the stripped stent remained stuck in the stent in the body. A new wire was taken and passed to the distal RCA. The stripped stent was crushed against the vessel wall with a 3.5x15mm NC balloon. Then, a 3.5x36mm drug-coated stent was implanted in this area and the stripped stent was jailed. After that RCA was stented distally to the crux. Meanwhile, a freely moving stent piece was seen in the aorta, extending from the RCA to the aorta, which was not noticeable in the previous exposures. For removing the floating stent in aorta, a manual snare was made with a 0.014 inch Sion blue wire because of there was no snare in the catheterization laboratory. The stent, which was floating and free at one end, was pulled off with manual snare. The stent piece floating freely in the aorta was broken off and removed. It was observed that approximately 5 cm of wire remained extending from the RCA ostial into the aorta. Complete removal of this remaining stent piece was considered. However, it could not be snareed because it was very thin and one end was jailed under the stent. It was left like that way because it was very thin, immobile and did not cause any dysfunction. The RCA artery was rewired and all stent interiors were post-dilated with a NC balloon. The process was terminated with TIMI 3 flow in RCA.

Especially when intervening in calcified and tortuous vessels, you should intervene very carefully and with gentle movements, without forcing, and in cases such as stent stripping, make sure that the stent is fully locked or completely removed.

**Keywords:** Floating stent in the aorta, calcified and tortuous coronary arteries, stent stripping

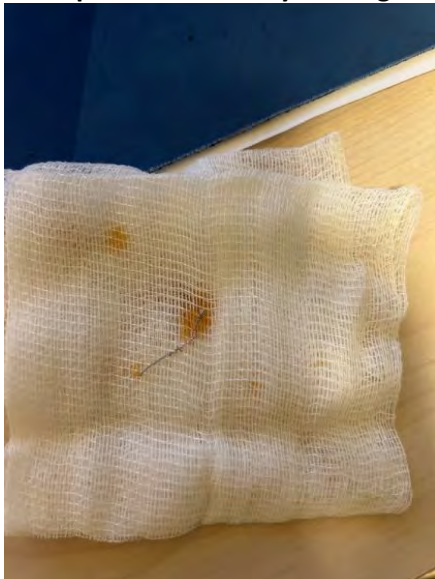

### Percutaneous coronary intervention and complication management stages



*A: Calcific and tortuous appearance of the right coronary artery, B: Visualization of the stripped stent in the RCA trunk (arrow sign), C: Stripped stent remaining in the RCA trunk, crushing the RCA wall with NC balloons over the new wire, D: After the right coronary artery is fully revascularized In the control poses, it is noticed that there is a floating stent extending in the aorta (arrow sign), E: the result image of the right coronary artery after complete revascularization, F: after the snare, the appearance of a very thin fixed wire extending from the RCA to the aorta remains (arrow sign).*

### Stent piece removed by holding it with a snare



**AuthorToEditor:** I tried to explain, as briefly as possible, a case in which a second complication arose while trying to combat one complication, and the presentation of the case was as long as the duration of the procedure. If the notification is deemed appropriate to be presented verbally, I will present it in a more understandable and detailed manner, accompanied by videos and images. Kind regards.

### [OP-20] The Role of New Inflammatory Markers in Determining The Development of Contrast-Induced Nephropathy in Patients Undergoing Percutaneous Coronary Angiography Due to STEMI

Zeki Çetinkaya

University of Health Sciences, Department of Cardiology, Elazığ Fethi Sekin City Hospital, Elazığ, Turkey

The Role of New Inflammatory Markers in Determining The Development of Contrast-Induced Nephropathy in Patients Undergoing Percutaneous Coronary Angiography Due to STEMI.

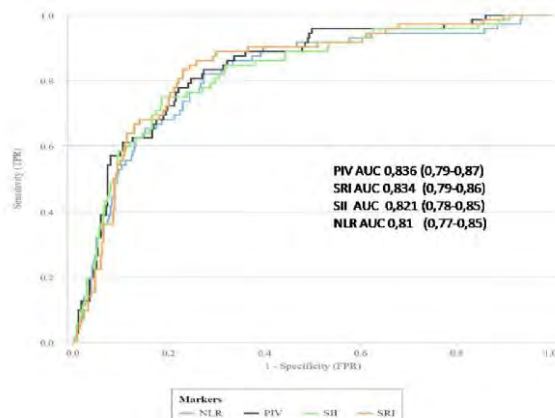
Contrast induced nephropathy is an important complication that develops after angiographic procedures. It is an important morbidity and mortality problem that causes patients to stay in hospital for a long time. This study aims to investigate the role of pre-procedural new immune-inflammation markers in predicting CIN development in patients undergoing percutaneous coronary intervention (PCI) due to ST segment elevation myocardial infarction (STEMI). A total of 417 STEMI patients were included in the study. CIN was defined as an increase of at least 0.5 mg/dl or 25% in serum baseline creatinine level 72 hours after the procedure. Patients were divided into two groups: those with and without CIN. Baseline characteristics, angiographic features, laboratory data, pan-immune-inflammation, systemic immune inflammation index (SII) and systemic response index were compared between the two groups. STEMI patients who developed CIN, platelet count ( $p=0,017$ ), Neutrophil count ( $p=0,017$ ), white blood cell (WBC) count ( $p<0.001$ ), monocyte count ( $p<0.001$ ), neutrophil-to-lymphocyte ratio (NLR) ( $p<0.001$ ), systemic immune inflammation index (SII) score ( $p<0.001$ ), SRI ( $p<0,001$ ), PIV ( $p<0.001$ ) were higher compared to those without CIN.

The receiver operating characteristic curve analysis (ROC) showed a cut off value of 468.6 with a sensitivity of 83.3 % and a specificity of 72 % in patients with PIV. CIN. ( $AUC=0,83$ ) SRI  $>2,19$  had 83% specificity and 77% sensitivity in detecting CIN ( $AUC=0.834$ ). SII  $>838.9$  had 81% specificity and 75% sensitivity in detecting CIN ( $AUC=0.82$ ). NLR  $>838.9$  had 72 % specificity and 81% sensitivity in detecting CIN ( $AUC=0.81$ ).

Our study shows that pre-procedural PIV and SRI values are a strong predictor among new inflammatory markers in determining the development of contrast-induced nephropathy in STEMI patients.

**Keywords:** Contrast induced nephropathy, STEMI, percutaneous coronary intervention

#### ROC analysis







# KARDİYOVASKÜLER AKADEMİ KONGRESİ

## & INTERNATIONAL ACADEMY OF YOUNG CARDIOLOGISTS

Elexus Hotel Girne. K.K.T.C.  
18-22 Eylül 2024

**Table 1. Demographic Characteristics of the Study Populations.**

	CIN (+)	CIN (-)	P
Variables	(n=72)	(n=345)	
Age (years)	66,8±10,6	64,5±9,9	0,07
male gender (n,%)	44 (%61,1)	205 (%59,6)	0,69
Body mass index (kg/m <sup>2</sup> )	30,1±2,8	31,3±2,6	0,55
Hypertension (n, %)	40 (%54,8)	187 (%54,4)	0,94
Diabetes Mellitus (n, %)	47 (%64,4)	172 (%50)	0,02
Current smoker (n, %)	52 (%71,2)	210 (%61)	0,1
Hypercholesterolemia (n, %)	20 (%27,4)	103 (%29,9)	0,6
Left ventricular ejection fraction (%)	54,2±5,2	54,79±5,1	0,4
Systolic blood pressure (mm Hg)	126,9±6,4	127,1±6,4	0,75
Diastolic blood pressure (mm Hg)	82,2±6,5	81,6±6,5	0,4
Heart rate (beats/min)	76,3±7,7	78,2±7,8	0,07



# KARDİYOVASKÜLER AKADEMİ KONGRESİ

## & INTERNATIONAL ACADEMY OF YOUNG CARDIOLOGISTS

Elexus Hotel Girne, K.K.T.C.  
18-22 Eylül 2024

### [OP-21] Investigation of Serum Raftlin (RFTN1) Level in Disseminated Coronary Artery Disease

Ali Eren Onuş, Ünal Öztürk

*Department of Cardiology, Faculty of Medicine, Kahramanmaraş Sutcu Imam University,  
Kahramanmaraş, Turkey*

**Objective:** Raftlin (RFTN1) is the major lipid raft protein responsible for regulating B cell antigen receptor (BCR) signal transduction. RFTN1 also plays an important role in the induction of autoimmune response and vascular inflammatory response. RFTN1 has been previously evaluated for oxidative stress, endothelial dysfunction and intimal inflammation in several studies, but no data on coronary artery disease have been found. In this study, we aimed to use the level of this biomarker in the prediction and risk classification of coronary artery disease.

**Methods:** The study was planned as a prospective single center study. A total of 88 patients, 46 males (mean age 63.37 years) and 42 females (mean age 63.21 years), who underwent coronary angiography in the Cardiology Clinic of KSU Medical Faculty for 1 year were included in the study.

**Results:** RFTN1 level was statistically different between the study groups. RFTN1 level was found to be strongly correlated with Gensini score.

**Conclusion:** In this prospective study, the relationship between RFTN1 and coronary artery disease was investigated for the first time in the literature and the findings showed that this biomarker was successful in predicting extensive or severe coronary artery disease. A multicenter clinical study with a larger sample size is needed to confirm these results.

**Keywords:** Raftlin, Coronary artery disease, Gensini score

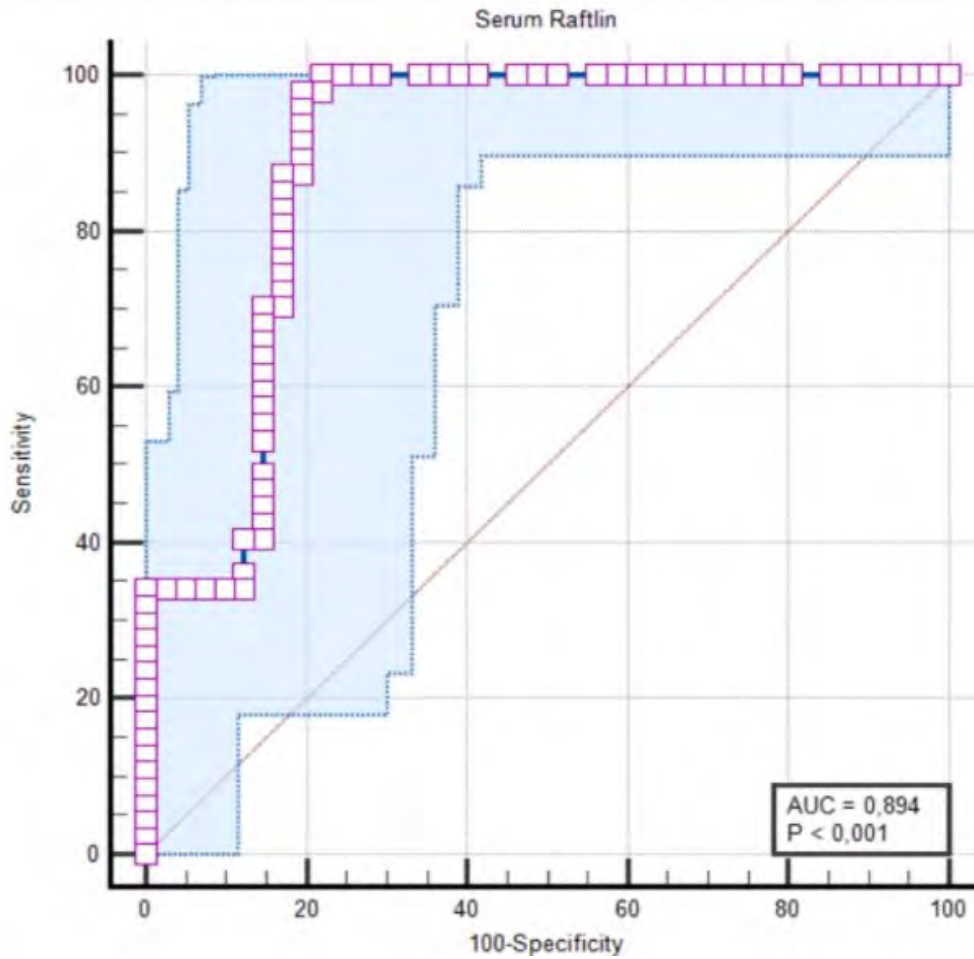


# KARDİYOVASKÜLER AKADEMİ KONGRESİ

## & INTERNATIONAL ACADEMY OF YOUNG CARDIOLOGISTS

Elexus Hotel Girne, K.K.T.C.  
18-22 Eylül 2024

ROC plot of Raftlin values for predicting the presence of prevalent CAD



The Raftlin cut-off value for the presence of prevalent CAD was found to be  $>2.12$  ng/ml. This value had a specificity of 80.46% [65.1-91.2] and a sensitivity of 97.87% [88.7-99.9] in predicting prevalent CAD. The area under the curve was 0.894 [0.810-0.950] and the predictive value of the Raftlin level for the presence of prevalent CAD was significant ( $p < 0.001$ ).

Statistically significant variables are shown in the multivariate analysis.

Variables	B	S.E	WALD	P	OR	CL
RFTN1	-4,813	2,064	5,440	0,020	0,008	0,000-0,464
Gensini score	-0,906	0,30	9,981	0,002	0,909	0,856-0,964

Univariate and multivariate logistic regression analysis was performed to determine the predictive power of a set of non-categorical variables for prevalent CAD in Group 1 and Group 2 participants. The Backward-Wald method was used in the analysis. According to the results of the multivariate analysis, the Raftlin and Gensini Score was statistically significant in predicting severe or extensive CAD ( $p < 0.05$ ).



# KARDİYOVASKÜLER AKADEMİ KONGRESİ

## & INTERNATIONAL ACADEMY OF YOUNG CARDIOLOGISTS

Elexus Hotel Girne, K.K.T.C.  
18-22 Eylül 2024

### [OP-22] Treatment of Persistent Thrombus with Stent-Retriever Thrombectomy in Acute Myocardial Infarction: A Case Report

Umur Baran Yılmaz, Aylin Şafak Arslanhan, Halil İbrahim Kardeş, Abdullah Orçun Öner  
ÜMRANİYE TRAINING AND RESEARCH HOSPITAL

Retriever thrombectomy stents are frequently and successfully used in occlusion of cerebral vessels. Thrombectomy has lost its popularity in acute coronary artery occlusions. It is rarely used as a salvage method in thrombosed lesions where vessel patency cannot be achieved by conventional methods. In this case report, we present the treatment of coronary thrombus with retriever thrombectomy stent in a patient who presented to the emergency department with acute inferior myocardial infarction. A 59-year-old male patient was admitted to the emergency department with sudden onset of chest pain that had been increasing in intensity for the last 2 hours. The patient's cardiac risk factors were hypertension, hyperlipidaemia and smoking. No pathological heart sound was detected on cardiac auscultation. Blood pressure was 95/68 mmHg; heart rate was 110/min and oxygen saturation was 95. During the initial evaluation, haemodynamics deteriorated and ventricular fibrillation developed. The patient was defibrillated 2 times. ECG showed ST segment elevation in the inferior leads. Pocket echocardiography performed in the emergency department showed ejection fraction 50%, hypokinesia in the mid part of the inferior wall and mild mitral regurgitation. After 300 mg acetyl salicylic acid and 180 mg ticagrelor were loaded, the patient was transferred to the cath lab. Transfemoral coronary angiography showed plaque in the left main coronary artery, plaque in the left anterior descending artery, 80% stenosis in the obtus marginalis artery and 100% thrombosed stenosis in the proximal segment of the right coronary artery (Figure 1). The right coronary ostium was engaged with a 6F right Judkins guide catheter. The thrombosed lesion was crossed with a guide wire. Despite repeated balloon angioplasty and mechanical thrombectomies, thrombus appearance persisted. A microcatheter was placed distal to the thrombus. A micro catheter was advanced distal to the thrombus. The guide wire was retrieved. Transfemoral neurovascular stent retriever (TREVO NXT PROVUE RETRIEVER) was sent through the microcatheter into the coronary artery. The stent was opened and the thrombus was trapped in the retriever stent (Figure 2). After thrombus extraction, XEINCE PRO DES 4x33 mm stent was implanted in the lesion area. Post dilatation was performed with 4.5x15 mm non-compliant balloon. Coronary TIMI 3 flow was provided. No peripheral embolism was observed during follow-up. Inferior wall hypokinesia was recovered on control echocardiography 2 months later. Thrombectomy in the coronary system can be performed by thrombus fragmentation, manual thrombus aspiration and neolithic thrombectomy. Stent retriever thrombectomy system is only approved for use in intracranial circulation, but there are rare cases showing that it can be used in acute myocardial infarction with high thrombus burden as in our case.

**Keywords:** Stent Retriever Thrombectomy, Acute Myocardial Infarction, Thrombectomy, Right Coronary Artery

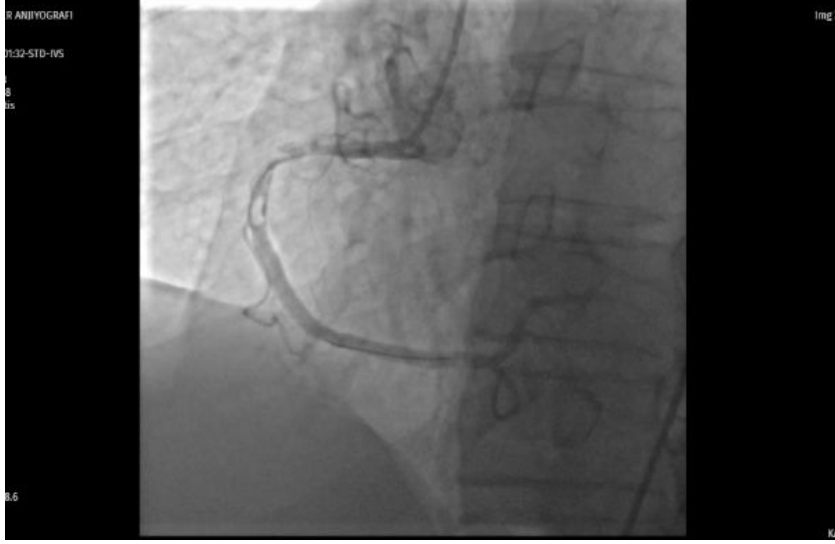


# KARDİYOVASKÜLER AKADEMİ KONGRESİ

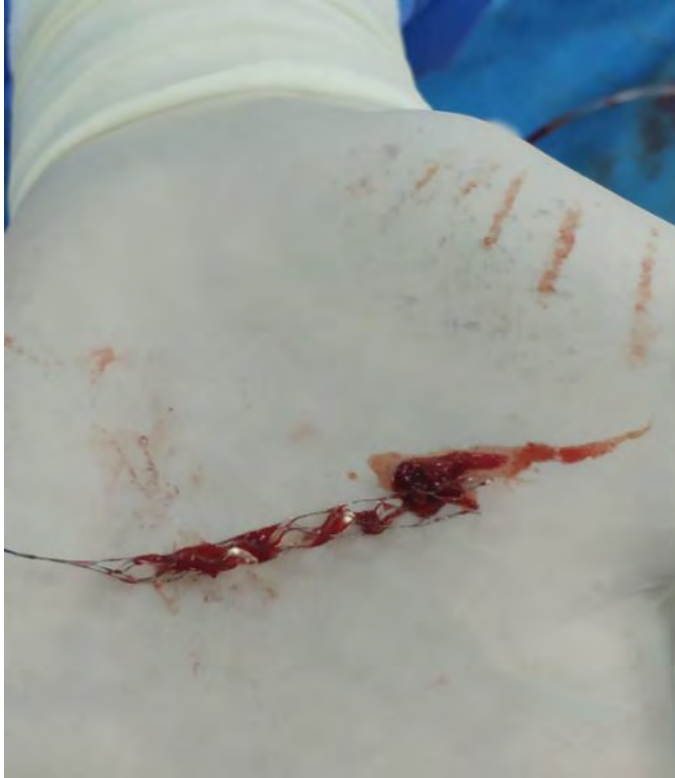## & INTERNATIONAL ACADEMY OF YOUNG CARDIOLOGISTS

Elexus Hotel Girne, K.K.T.C.  
18-22 Eylül 2024

**Figure 1**



**Figure 2**







# KARDİYOVASKÜLER AKADEMİ KONGRESİ

## & INTERNATIONAL ACADEMY OF YOUNG CARDIOLOGISTS

Elexus Hotel Girne, K.K.T.C.  
18-22 Eylül 2024

### [OP-23] The Role of Systemic Inflammation Response Index (SIRI) in Predicting Stent Restenosis

Orhan Karayiğit

*Yozgat Şehir Hastanesi, Kardiyoloji Bölümü*

**Objective:** Although the rates of restenosis have gradually decreased with the use of drug-eluting stents and the development of stent technologies, intervention in stent restenosis remains a significant clinical problem. Inflammation plays a significant role in the atherosclerotic process and stent restenosis. Within this context, we aimed to evaluate the predictive value of Systemic Inflammation Response Index (SIRI) of stent restenosis.

**Material-Methods:** The study retrospectively examined patients who were presented to the hospital with acute coronary syndrome or stable angina pectoris between May 2019 and May 2022, underwent successful stent implantation, and subsequently underwent repeat coronary angiography due to stable angina pectoris within one year. The Systemic Inflammation Response Index (SIRI) was calculated from the routine hemogram test taken before the patients' second coronary angiography using the formula (Neutrophil count x Monocyte count) / Lymphocyte count. A total of 330 patients were included in the study and were divided into two groups: those with in-stent restenosis (n:165) and those without restenosis (n:165).

**Results:** The median level of SIRI was found to be higher in the group with restenosis (+) (3.03 vs 1.62,  $p<0.001$ ) (Fig. 1). About curve analysis of the receiver-operating characteristic (ROC), SIRI values above 2.15 predicted restenosis with 66.7% sensitivity and 69.1% specificity (Area under the curve: 0.760; 95% CI: 0.710-0.811,  $p<0.001$ ) (Fig. 2). As for the analysis based on the multivariate logistic regression, stent diameter (OR:0.347, CI 95%: 0.198-0.609,  $p<0.011$ ), DM (OR:1.767, CI 95%: 1.035-3.016), smoking (OR:2.827, CI 95%: 1.647-4.850,  $p<0.001$ ), and SIRI (OR:1.906, CI 95%: 1.544-2.354,  $p<0.001$ ) were found to be independent predictors of in-stent restenosis (Table).

**Conclusions:** SIRI, which is an inflammation marker and can be calculated easily, was found to be an independent predictor of in-stent restenosis. Therefore, careful monitoring of various inflammatory parameters, including SIRI, is important for predicting in-stent restenosis, calling these patients for closer follow-up, and tight glyceic control.

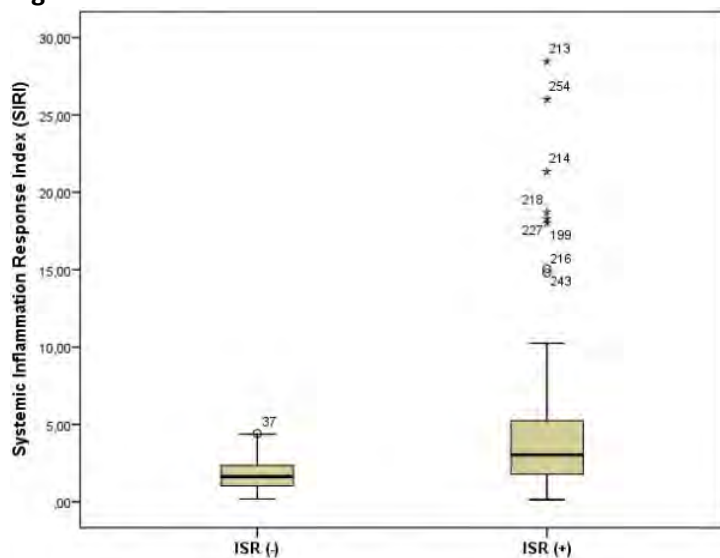
**Keywords:** In-stent restenosis, Systemic Inflammation Response Index, SIRI

# KARDİYOVASKÜLER AKADEMİ KONGRESİ

## & INTERNATIONAL ACADEMY OF YOUNG CARDIOLOGISTS

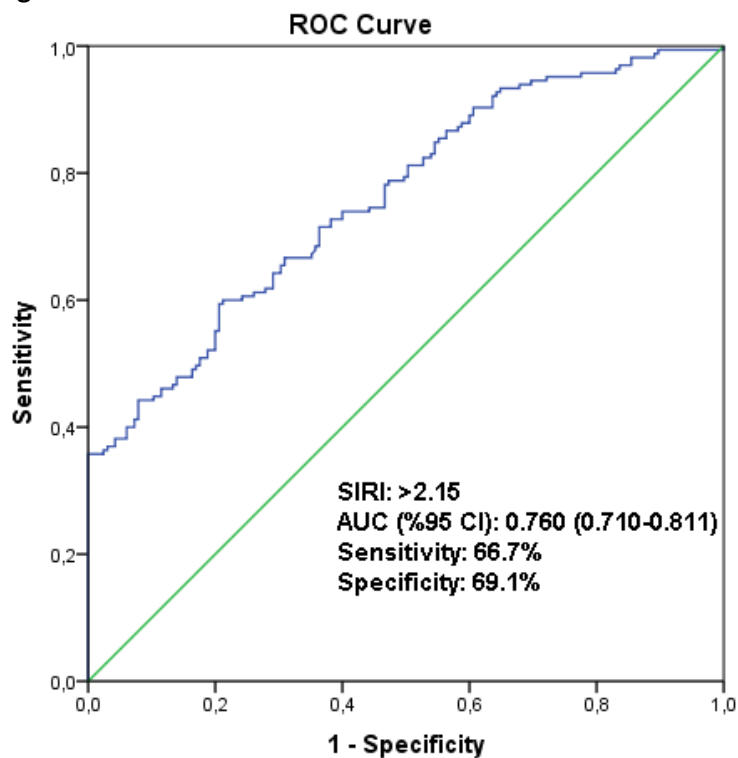
Elexus Hotel Girne, K.K.T.C.  
18-22 Eylül 2024

Fig. 1



Comparison of Systemic Inflammation Response Index (SIRI) of the Study Groups

Fig. 2



Receiver operating characteristic (ROC) curve analysis of Systemic Inflammation Response Index (SIRI) for the identification of stent restenosis



# KARDİYOVASKÜLER AKADEMİ KONGRESİ

## & INTERNATIONAL ACADEMY OF YOUNG CARDIOLOGISTS

Elexus Hotel Girne, K.K.T.C.  
18-22 Eylül 2024

**Table**

Variables	Univariate analysis	p value	Multivariate analysis	p value
Smoking	2.920 (1.865-4.570)	<0.001	2.827 (1.647-4.850)	<0.001
Diabetes Mellitus	1.811 (1.167-2.811)	0.008	1.767 (1.035-3.016)	0.037
Hemoglobin	0.880 (0.790-0.981)	0.021	0.959 (0.843-1.092)	0.531
LVEF	0.970 (0.951-0.991)	0.004	0.992 (0.967-1.017)	0.537
Stent diameter	0.329 (0.203-0.531)	<0.001	0.347 (0.198-0.609)	<0.001
SIRI	1.947 (1.610-2.335)	<0.001	1.906 (1.544-2.354)	<0.001

*Univariate and multivariate logistic regression analysis for predicting stent restenosis*

**AuthorToEditor:** Dear Scientific Committee members, Although the rates of restenosis have gradually decreased with the use of drug-eluting stents and the development of stent technologies, intervention in stent restenosis remains a significant clinical problem. In this article, we aimed to evaluate the predictive value of Systemic Inflammation Response Index (SIRI) of stent restenosis. I think that this manuscript have a potential to take your readers interest. Sincerely Orhan KARAYİÇİT



# KARDİYOVASKÜLER AKADEMİ KONGRESİ

## & INTERNATIONAL ACADEMY OF YOUNG CARDIOLOGISTS

Elexus Hotel Girne, K.K.T.C.  
18-22 Eylül 2024

### [OP-24] Long-Term Results in Patients Operated Due to Cardiac Mass: Tertiary Center Experience

Mehmet Altunova, Samet Sevinc

*University of Health Sciences, Mehmet Akif Ersoy Thoracic and Cardiovascular Surgery Training and Research Hospital, Department of Cardiology, Istanbul, Turkey*

**Aim:** Cardiac masses are a relatively rare cardiac condition that includes benign, malignant, and non-tumoral mass lesions. This study aims to share our findings regarding cardiac masses observed in our tertiary cardiology hospital and our experiences regarding long-term results.

**Materials and methods:** We evaluated the in-hospital, early-term and long-term outcomes of 121 patients who underwent surgical excision for a cardiac mass at our tertiary care center between January 2012 and January 2022.

**Results:** The mean age of the patients was  $52.2 \pm 14.8$  years, and 63 (56.8%) were women. Early complications were observed in 17 patients (14.4%); Of these, pulmonary complications occurred in 6 patients, in-hospital mortality occurred in 3 patients, pericardial tamponade occurred in 3 patients, incomplete resection occurred in 3 patients, stroke occurred in 1 patient, and wound infection occurred in 1 patient. In mass excision, 60 (50.8%) patients had myxoma, 31 (26.3%) had thrombus, 9 (7.6%) had fibroelastoma, 8 (6.8%) had lipoma and hemangioma, 6 (5.1%) had malignancy, and 4 (3.4%) had vegetation.

The patients were followed for a median of 38.5 months. During follow-up, recurrence occurred in 3 patients and mortality occurred in 24 patients. Univariate and multivariate Cox regression analysis was performed to identify predictors of long-term mortality. Accordingly, chronic kidney disease ( $p=0.031$ ) and length of stay in the intensive care unit ( $p=0.004$ ) were determined as independent variables of long-term mortality during follow-up.

**Conclusion:** Among surgically removed heart tumors, benign heart tumors are much more common than both primary and secondary malignancies. The most common cardiac mass was myxoma, and most were localized in the left atrium. Long-term mortality rates were relatively low because the majority were benign. Independent variables of long-term mortality are chronic kidney disease and length of stay in the intensive care unit.

**Keywords:** Cardiac mass, Surgery, Mortality

---



# KARDİYOVASKÜLER AKADEMİ KONGRESİ

## & INTERNATIONAL ACADEMY OF YOUNG CARDIOLOGISTS

Elexus Hotel Girne, K.K.T.C.  
18-22 Eylül 2024

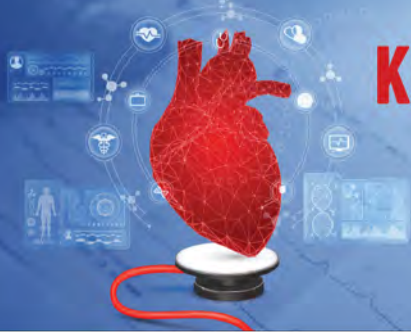Figure1

**Table 2.** Univariate and multivariate Cox regression analysis to determine mortality predictors in long-term follow-up

	Univariate analysis			Multivariate analysis		
	Hazard ratio	95% CI (lower upper)	P value	Hazard ratio	95% CI (lower upper)	P value
Age	1.033	1.003-1.063	<b>0.032</b>	1.025	0.990-1.058	0.179
Chronic renal failure	5.734	2.399-13.706	<b>&lt;0.001</b>	3.382	1.116-10.251	<b>0.031</b>
Previous CVD	3.540	1.546-8.106	<b>0.003</b>	2.147	0.764-6.033	0.147
Mass index	1.026	1.005-1.047	<b>0.014</b>	1.018	0.993-1.044	0.160
ICU length	1.295	1.180-1.422	<b>&lt;0.001</b>	1.205	1.062-1.368	<b>0.004</b>
Malignant	1.471	1.198-1.807	<b>&lt;0.001</b>	1.159	0.817-1.644	0.408

*Univariate and multivariate Cox regression analysis to determine mortality predictors in long-term follow-up*





# KARDİYOVASKÜLER AKADEMİ KONGRESİ

## & INTERNATIONAL ACADEMY OF YOUNG CARDIOLOGISTS

Elexus Hotel Girne, K.K.T.C.  
18-22 Eylül 2024

**Table 1. Baseline demographic, clinical, and mass characteristics of all patients**

	Survivor group (n=94)	Non-survivor group (n=24)	P value
Age, year, mean (SD)	50.6 ± 14.4	58.5 ± 14.9	0.018
Gender (female), n (%)	52 (55.3)	14 (58.3)	0.791
Diabetes mellitus, n (%)	24 (25.5)	8 (33.3)	0.443
Hypertension, n (%)	30 (31.9)	13 (54.2)	0.043
Coronary artery disease, n (%)	6 (6.4)	5 (20.8)	0.030
Chronic renal failure, n (%)	6 (6.4)	8 (33.3)	<0.001
Previous CVD, n (%)	10 (10.6)	9 (37.5)	0.001
COPD, n (%)	10 (10.6)	4 (16.7)	0.415
Current smoking, n (%)	25 (26.6)	5 (20.8)	0.563
Atrial fibrillation, n (%)	40 (42.6)	13 (54.2)	0.307
LVEF, (%)	59.5 ± 7.4	56.9 ± 8.5	0.288
Intraoperative characteristics			
ACC time (min)	44 (32.5-60)	67 (31.3-77.8)	0.113
CPB time (min)	82 (64-100)	101 (72.8-121.8)	0.093
Hypothermia, °C	29.9 ± 2.2	29.4 ± 2	0.137
Additional surgical procedure	40 (42.6)	13 (54.2)	0.307
Mass characteristics			
Mass leght, mm	33.5 ± 16.1	44.2 ± 23.7	0.010
Mass wide, mm	23.1 ± 11.4	25.8 ± 13.8	0.314
Mass histopathology, n (%)			<0.001
Malignant mass	1 (1.1)	5 (20.8)	
Benign mass	93 (98.9)	19 (79.2)	
Myxoma	55 (58.8)	5 (20.8)	
Thrombus	20 (21.3)	11 (45.8)	
Fibroelastoma	8 (8.5)	1 (4.2)	
Lipoma-hemangioma	7 (7.4)	1 (4.2)	
Vegetation	3 (3.2)	1 (4.2)	
Clinical presentation, n (%)			0.250
Asymptomatic	9 (9.6)	2 (8.3)	
Obstruction	58 (61.7)	14 (58.3)	
Contraction defect	17 (18.1)	2 (8.3)	



# KARDİYOVASKÜLER AKADEMİ KONGRESİ

## & INTERNATIONAL ACADEMY OF YOUNG CARDIOLOGISTS

Elexus Hotel Girne, K.K.T.C.  
18-22 Eylül 2024

Embolization	10 (10.6)	6 (25)	
Location, n (%)			0.585
Left atrium	61 (64.9)	14 (58.3)	
Right atrium	13 (13.8)	6 (25)	
Left ventricle	3 (3.2)	0 (0)	
Right ventricle	2 (2.1)	1 (4.2)	
Valves	15 (16)	18 (15.3)	
ICU length of stay, days	1 (1-2)	2 (1-7.3)	0.009
Hospital length of stay, days	6 (6-9)	8 (5.3-12)	0.274
Follow-up, months	41 (29-78)	18.5 (9.3-33)	<0.001

*Abbreviation: ACC, aortic cross-clamp; CPB, cardiopulmonary bypass; COPD: chronic obstructive pulmonary disease; CVD: cerebrovascular disease; LVEF: left ventricular ejection fraction.*

**[OP-25] The Effect of the Demographic and Clinical Characteristics of the Patients with Supraventricular Tachycardia on the Procedure Times in the Electrophysiology Study**



# KARDİYOVASKÜLER AKADEMİ KONGRESİ

## & INTERNATIONAL ACADEMY OF YOUNG CARDIOLOGISTS

Elexus Hotel Girne. K.K.T.C.  
18-22 Eylül 2024

Rustem Yilmaz, Osman Can Yontar

*Samsun University Faculty of Medicine, Samsun Training and Research Hospital, Department of Cardiology, Samsun, Turkey.*

**Introduce:** Supraventricular tachycardia (SVT) is common and often symptomatic in young and middle-aged patients. SVT usually originates in the atrioventricular node or above the AV node. Atrioventricular nodal reentry tachycardia (AVNRT), atrioventricular reentry tachycardia (AVRT), and atrial tachycardia (AT) are the most common types of SVT. Patients who are symptomatic despite medications require treatment with electrophysiological procedures. In this study, the effect of the demographic and clinical characteristics of the patients with SVT on the procedure times in the electrophysiology study (EPS) was investigated.

**Methods:** 33 patients who underwent electrophysiological study and ablation due to SVT were included in the study. Of the patients with SVT, 33 (100%) had an AVNRT. The patients were divided into two groups according to the duration of the procedure (Group 1: procedure time < 60 minutes and Group 2: procedure time  $\geq$  60 minutes) in the EPS. Patients in whom tachycardia could not be induced in EPS and ablation could not be performed were excluded from the study. Demographic and clinical characteristics of patients and duration of procedure were obtained.

**Results:** A total of 33 patients participated in the study, of which 19 (57,6%) were group 1 and 14 (42,4%) were group 2. Body Mass Index (BMI) and age were significantly higher in group 2 than group 1 ( $p < 0.05$ ). However, hypertension (HT), diabetes mellitus (DM), smoking, gender, and symptom time were not statistically significant between in the group 1 and group 2 ( $P > 0.05$ ).

**Conclusion:** BMI and age may be important in estimating the duration of the procedure in patients with SVT in the EPS. These factors can be important in daily patient planning.

**Keywords:** Supraventricular tachycardia, Electrophysiology study, Procedure times

**Comparison of demographic and clinical features of patients with Group 1 (Procedure time <60 minutes) and Group 2 (Procedure time  $\geq$ 60 minutes)**



# KARDİYOVASKÜLER AKADEMİ KONGRESİ

## & INTERNATIONAL ACADEMY OF YOUNG CARDIOLOGISTS

Elexus Hotel Girne. K.K.T.C.  
18-22 Eylül 2024

	GROUP 1		GROUP 2		p-value
AGE	42±10,55 Mean±SD		48,4±4,7 Mean±SD		0,031
	Count	Column N %	Count	Column N %	p-value
WOMEN: 0, MEN: 1	0 12 1 7	63,0% 37,0%	10 4	71,4% 28,6%	0,618
HT NO: 0, YES: 1	0 16 1 3	84,2% 15,8%	12 2	85,7% 14,3%	0,927
DM NO: 0, YES: 1	0 19 1 0	100,0% 0,0%	12 2	85,7% 14,3%	0,089
SMOKING NO: 0, YES: 1	0 18 1 1	94,7% 5,3%	11 3	78,6% 21,4%	0,160
BMI: 22-25): 0, (BMI: 26-29): 1, (BMI> 30): 2	0 7 1 10 2 2	36,8% 52,6% 10,5%	3 4 7	21,4% 28,6% 50,0%	0,042
Symptom Time 1< Year: 0, 1-5 Year: 1, 5> Year: 2	0 5 1 3 2 11	26,3% 15,8% 57,9%	1 6 7	7,1% 42,9% 50,0%	0,143

Abbreviations; HT: Hypertension, DM: Diabetes Mellitus, BMI: Body Mass Index





# KARDİYOVASKÜLER AKADEMİ KONGRESİ

## & INTERNATIONAL ACADEMY OF YOUNG CARDIOLOGISTS

Elexus Hotel Girne. K.K.T.C.  
18-22 Eylül 2024

### [OP-26] Diagnostic accuracy of computed tomography coronary angiography in different coronary arteries

Fatih Koca

Sağlık Bilimleri Üniversitesi Bursa Yüksek İhtisas Eğitim ve Araştırma Hastanesi, Kardiyoloji Kliniği

**OBJECTİVES:** Computed tomography coronary angiography (CTCA) is a reliable, non-invasive imaging modality versus invasive coronary angiography (CAG), which is the reference standard for assessing the degree of coronary artery stenosis. In our study, we aimed to investigate the sensitivity, specificity, positive and negative predictive values (PPV and NPV) of the different coronary artery lesions detected with CCTA compared to CAG.

**Methods:** In our hospital, 94 patients who underwent CTCA followed by CAG in the last 2 years were identified. Demographic, laboratory and imaging data of these patients were recorded. Coronary artery lesions detected in CTCA and CAG of the patients were divided into 6 categories based on the degrees of narrowing coronary lumen (0, 1-24, 25-49, 50-74, 75-99 % and total lesions) and recorded. Sensitivity, specificity, PPV and NPV in diagnosing coronary lesions with a diameter narrowing  $\geq 1-24$  % on CTCA were calculated separately for each coronary artery lesion using chi-square analysis. Complete accuracy rate (the rate of assessing the coronary lesion category as same as CAG) and near accuracy rate (the rate of assessing the coronary lesions category one degree below or above CAG) were found for each coronary artery on CTCA.

**Results:** The sensitivity rates were 75%, 92.5, 79.2, 71.4 for left main coronary artery (LMCA), left anterior descending artery (LAD), circumflex artery (Cx) and right coronary artery (RCA) lesions, respectively (see Table 1). The specificity rates were 77.7%, 65.5, 75.6 and 84.2 %, PPVs were 13, 87.1, 80.4 and 87 % and NPVs were 98.6, 76.72 and 66.7%, respectively. The rates of knowing the lesion categories with complete accuracy were 74.5%, 41.5, 45.7 and 47.9% for LMCA, LAD, Cx and RCA lesions, and the rates of knowing with near accuracy were 83, 74.5, 78.7 and 75.5%, respectively.

**Conclusion:** CCTA may be more sensitive in predicting LAD lesions than in other coronary artery lesions. Both complete accuracy and near accuracy rates were highest for LMCA among different coronary arteries on CTCA. Based on these results, CCTA may be used as a highly reliable imaging test to rule out LMCA lesions, especially with high NPV.

**Keywords:** CTCA, coronary angiography, coronary artery stenosis



# KARDİYOVASKÜLER AKADEMİ KONGRESİ

## & INTERNATIONAL ACADEMY OF YOUNG CARDIOLOGISTS

Elexus Hotel Girne, K.K.T.C.  
18-22 Eylül 2024

**Table 1**

**Table 2.** Distribution of lesion categories by coronary arteries and imaging test.

Variables	LMCA		LAD		Cx		RCA	
	CT	CAG	CT	CAG	CT	CAG	CT	CAG
Lesion, n (%)	23(24.5) 4(4.3)	70(74.5)	66(70.2)	51(54.3) 53(56.4)	46(48.9)	56(59.6)		
No lesion	71(75.5)	90(95.7)	24(25.5)	28(29.8)	43(45.7) 41(43.6)	47(50)	38(40.4)	
1-24% lesion, n(%)	5(5.3)	1(1.1)	3(3.2)	18(19.1)	6(6.4)	22(23.4)	6(6.4)	24(25.5)
25-49 % lesion, n(%)	8(8.5)	1(1.1)	18(19.1)	13(13.8)	12(12.8)	9(9.6)	15(16)	9(9.6)
50-74 % lesion, n(%)	7(7.4)	0(0)	20(21.3)	6(6.4)	12(12.8)	4(4.3)	15(16)	4(4.3)
75-99 % lesion, n(%)	3(3.2)	1(1.1)	18(19.1)	15(16)	9(9.6)	14(14.9)	6(6.4)	9(9.6)
Total lesion, n(%)	0 (0)	1(1.1)	11(11.7)	14(14.9)	12(12.8)	4(4.3)	5(5.3)	10(10.6)
Full accuracy, n (%)	70(74.5)		39(41.5)		43(45.7)		45(47.9)	
Near accuracy, n (%)	78(83)		70(74.5)		74(78.7)		71(75.5)	

**Abbreviations:** CAG: coronary angiography, CT: computerized tomography, Cx: circumflex artery, LAD: left anterior descending artery, LMCA: left main coronary artery, RCA: right coronary artery.

**Table 1.** Distribution of lesion categories by coronary arteries and imaging test.

**Table 1**

Variables	LMCA	LAD	Cx	RCA
Test	CT CAG	CT CAG	CT CAG	CT CAG
Lesion, n (%)	23(24.5) 4(4.3)	70(74.5) 66(70.2)	51(54.3) 53(56.4)	46(48.9) 56(59.6)
No lesion	71(75.5) 90(95.7)	24(25.5) 28(29.8)	43(45.7) 41(43.6)	47(50) 38(40.4)
1-24% lesion, n(%)	5(5.3) 1(1.1)	3(3.2) 18(19.1)	6(6.4) 22(23.4)	6(6.4) 24(25.5)
25-49 % lesion, n(%)	8(8.5) 1(1.1)	18(19.1) 13(13.8)	12(12.8) 9(9.6)	15(16) 9(9.6)
50-74 % lesion, n(%)	7(7.4) 0(0)	20(21.3) 6(6.4)	12(12.8) 4(4.3)	15(16) 4(4.3)
75-99 % lesion, n(%)	3(3.2) 1(1.1)	18(19.1) 15(16)	9(9.6) 14(14.9)	6(6.4) 9(9.6)
Total lesion, n(%)	0 (0) 1(1.1)	11(11.7) 14(14.9)	12(12.8) 4(4.3)	5(5.3) 10(10.6)
Complete accuracy, n (%)	70(74.5)	39(41.5)	43(45.7)	45(47.9)
Near accuracy, n(%)	78(83)	70(74.5)	74(78.7)	71(75.5)

**Table 1.** Distribution of lesion categories by coronary arteries and imaging test. Abbreviations: CAG: coronary angiography, CT: computerized tomography, Cx: circumflex artery, LAD: left anterior descending artery, LMCA: left main coronary artery, RCA: right coronary artery.

**AuthorToEditor:** I hope that this work, which I think will contribute to the literature, will be accepted as an oral presentation at your congress.



# KARDİYOVASKÜLER AKADEMİ KONGRESİ

## & INTERNATIONAL ACADEMY OF YOUNG CARDIOLOGISTS

Elexus Hotel Girne, K.K.T.C.  
18-22 Eylül 2024

### [OP-27] Successful management of stuck rotablator that developed during rotational atherectomy of the calcified left anterior descending artery

Murat Kelbaş, Kudret Keskin, Sinan Şahin

*İstanbul Seyrantepe Hamidiye Etfal Eğitim ve Araştırma Hastanesi, Kardiyoloji Kliniği,*

**Background:** Rotational atherectomy is frequently performed with high procedural success in complex fibrocalcific coronary lesions. Stuck rotablator is a rare but life-threatening complication that can lead to coronary occlusion. Here, we present the management of a stuck rotablator case that developed during percutaneous coronary intervention accompanied by a rotablator in a 59-year-old patient with a severe calcific lesion in the left anterior descending artery (LAD).

**Case:** A 59-year-old male patient with known coronary artery disease (2012 PCI) and hypertension was admitted to our clinic with the diagnosis of stable angina pectoris. Electrocardiography showed normal sinus rhythm. Echocardiography showed EF: 55% and the posterolateral and anterolateral walls were slightly hypokinetic. In the coronary angiography performed on the patient, we decided to perform percutaneous intervention accompanied by a rotablator for LAD: ectatic, calcific proximal 80% stenosis.

**Coronary angiography:** A 7F CLS 4.5 catheter was placed in the left system. Workhorse wire was sent to the distal part of the lesion with a microcatheter. Then, a Rotawire wire was sent over the microcatheter and plate modification was started at 150,000 rpm with 2.75 burr. Suddenly resistance was encountered and rapid drops of more than 5000 rpm were observed. The burr then became stuck within the lesion and the first attempted withdrawal maneuvers were unsuccessful. Simultaneously, LAD blood flow was interrupted and the patient began to have chest pain. Then, balloon dilatation was planned by advancing the floppy wire from the edge of the stuck rotablator, but the wire could not be advanced. Afterwards, the rotablator system was operated in Dyna mode at a lower speed of 60,000 rpm, the system was secured, and the catheter was cannulated up to the LAD ostium, and with a final maneuver, the rotablator catheter and the entire system were successfully withdrawn. Angiography was checked for dissection and no dissection was observed. The lesion was re-cannulated with a workhorse wire and plate modification was started at a higher speed of 170,000 rpm using the rotawire extrasupport wire. Subsequently, predilatation was performed with a 3.25 \* 18 mm NC balloon and a 4.0 \* 29 mm FIREHAWK DES was implanted at 14 ATM. Then, 4.5 \* after postdilatation with a 20 mm NC balloon, TIMI 3 flow was achieved and the procedure was terminated.

**CONCLUSION:** Rotablator burr entrapment is a rare but very serious complication of rotational atherectomy and can occur not only in tortuous calcified lesions but also in relatively flat proximal coronary segments. Reasons such as newly implanted stents, eccentric and calcific lesions, and high diameter/artery ratio increase the risk of stuck rotablator. Dilation of the lesion with balloon angioplasty or cutting the rotablator and then advancing guidewire to the stuck burr area and applying traction are safe and effective interventional treatment techniques.

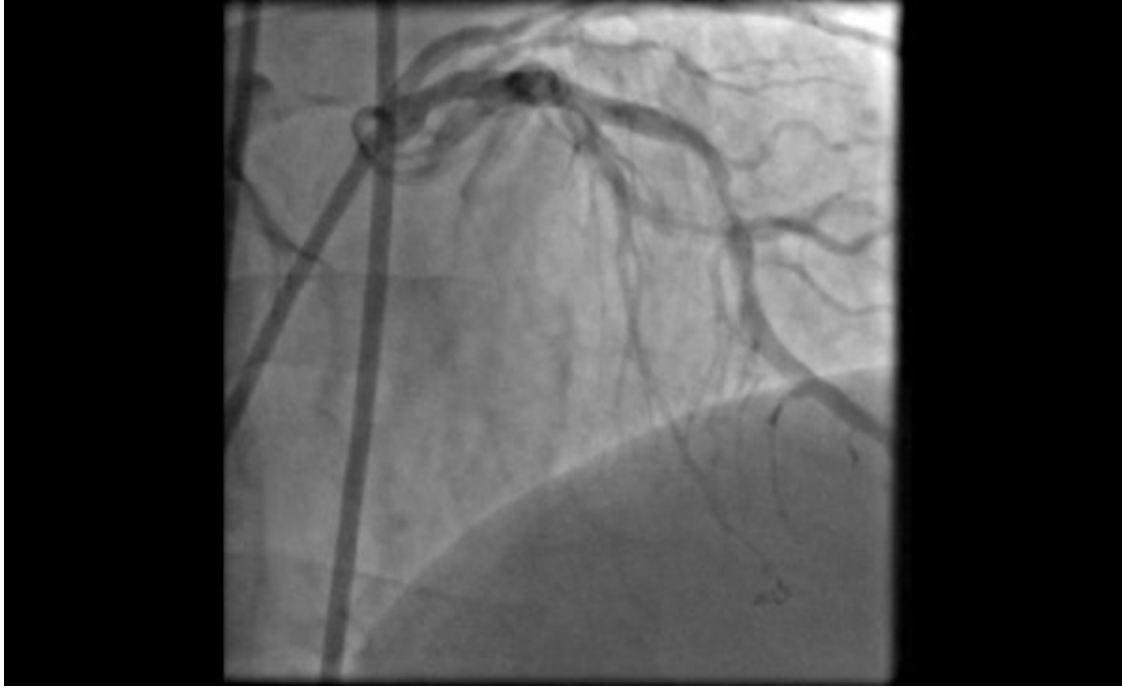**Keywords:** Angiography, atherectomy, complications, percutaneous coronary intervention

# KARDİYOVASKÜLER AKADEMİ KONGRESİ

## & INTERNATIONAL ACADEMY OF YOUNG CARDIOLOGISTS

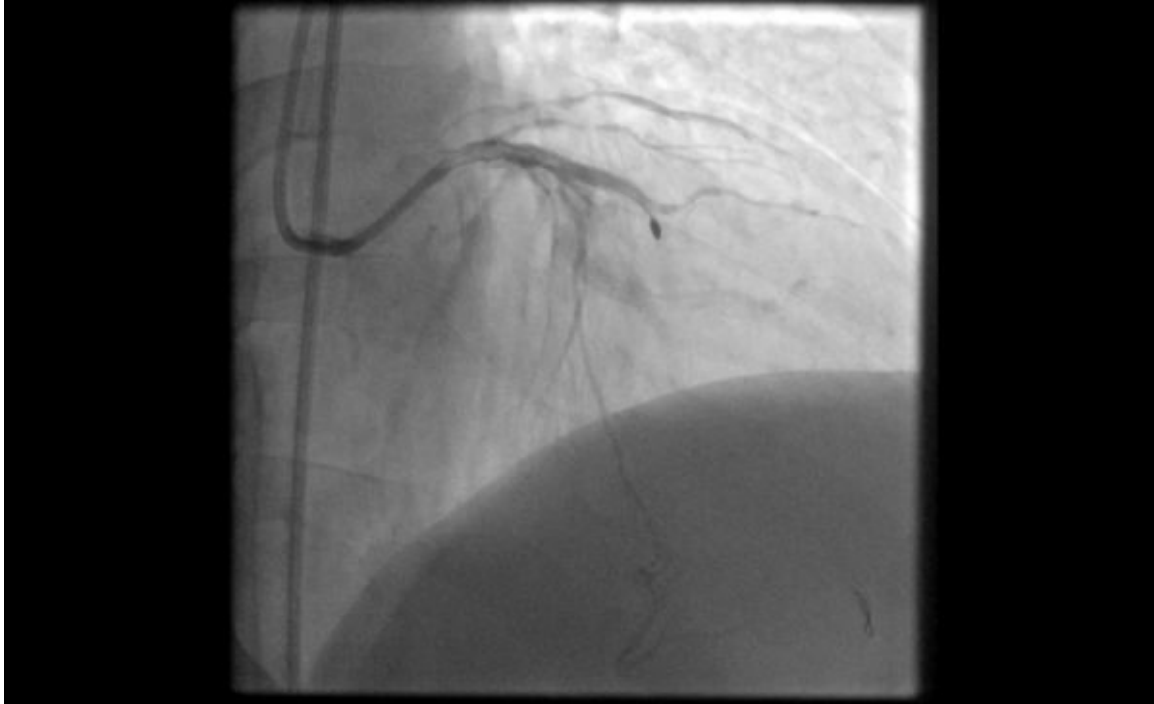
Elexus Hotel Girne, K.K.T.C.  
18-22 Eylül 2024

ŞEKİL 1



*Calcific 80% stenosis in the proximal left anterior descending artery*

Şekil 2



*Coronary occlusion developing after stuck rotablator*



# KARDİYOVASKÜLER AKADEMİ KONGRESİ

## & INTERNATIONAL ACADEMY OF YOUNG CARDIOLOGISTS

Elexus Hotel Girne. K.K.T.C.  
18-22 Eylül 2024

### [OP-28] Relationship Between FIB-4 Index and Interatrial Block Detected on 12-lead Electrocardiography in Non-alcoholic Population

Afag Özyıldız<sup>1</sup>, Ali Gökhan Özyıldız<sup>2</sup>

<sup>1</sup>Cardiology, Recep Tayyip Erdoğan Training and Research Hospital, Rize, Türkiye

<sup>2</sup>Cardiology, Faculty of Medicine, Recep Tayyip Erdoğan University, Rize, Türkiye

**Aim:** Interatrial block (IAB) is an electrocardiographic (ECG) pattern that indicates a delay in the conduction between the right and left atria, through Bachmann's bundle. Any delay in atrial conduction detected on the ECG as a P-wave duration longer than 120 ms is defined as IAB. The significance of this delay arises from its correlation with atrial arrhythmias, thromboembolic events and cardiovascular mortality. The Fibrosis-4 (FIB-4) index is a non-invasive scoring tool used to quantify the extent of liver fibrosis in individuals with non-alcoholic fatty liver disease (NAFLD). Growing evidence indicates that patients with NAFLD are at substantial risk for the development of hypertension, coronary heart disease, cardiomyopathy, and cardiac arrhythmias, which ultimately lead to a higher incidence of cardiovascular morbidity and mortality. The aim of the current study is to examine the potential correlation between IAB and FIB-4 index in non-alcoholic population.

**Materials-Methods:** This cross-sectional study included a cohort of 248 (110 of them were women) non-alcoholic outpatients who admitted to the cardiology clinic. The analysis of the patients' individual FIB-4 index were conducted utilizing clinical and laboratory data:  $FIB-4 \text{ Score} = (\text{Age} \times \text{AST}) / (\text{Platelets} \times \sqrt{\text{ALT}})$ . Patients were divided into two groups according to the presence or absence of interatrial block on ECG. Following a minimum fasting time of 12 hours, laboratory parameters were acquired using peripheral venous sample, and electrocardiographic measurements, clinical and medication data were recorded.

**Results:** The univariate logistic regression analysis revealed significant associations between age ( $p=0.003$ ), FIB-4 index ( $p=0.025$ ), beta-blocker usage ( $p=0.01$ ), C-reactive protein (CRP,  $p=0.047$ ), and low-density lipoprotein (LDL,  $p=0.042$ ) with IAB. In the context of multivariate logistic regression analysis, there existed a significant independent relationship between IAB with LDL (OR: 0.989, 95% CI: 0.979-1.000,  $p=0.046$ ), CRP (OR: 3.804, 95% CI: 1.180-12.257,  $p=0.025$ ), and FIB-4 index (OR: 1.693, 95% CI: 1.018-2.816,  $p=0.043$ ).

**Conclusion:** The IAB may have a distinct correlation with NAFLD. Extensive investigations should validate this link, since IAB can serve as a useful ECG tool for monitoring patients before the onset of clinical signs related to liver fibrosis.

**Keywords:** Interatrial block, non-alcoholic fatty liver disease, FIB-4 index





# KARDİYOVASKÜLER AKADEMİ KONGRESİ

## & INTERNATIONAL ACADEMY OF YOUNG CARDIOLOGISTS

Elexus Hotel Girne, K.K.T.C.  
18-22 Eylül 2024

### [OP-29] A Rare Case: Ablation of Focal Atrial Tachycardia from the Non-Coronary Aortic Cusp

Cem Korucu, Halil Siner, İbrahim Etem Dural

*Afyonkarahisar Health Science University, Faculty of Medicine, Department of Cardiology*

**Case:** The patient, who had known heart failure, coronary artery disease and hypertension, was interned for electrophysiological study due to complaints of palpitations and shortness of breath. In the echocardiographic examination of the patient, the ejection fraction was 40-45% and there was mild mitral insufficiency and mild tricuspid insufficiency. After informed consent was obtained and antiarrhythmic medications were discontinued, the patient was taken to the catheter laboratory. The procedure was performed with sedation.

Catheters were inserted into the right atrium (RA), right ventricular apex (RVA), CS, and His bundle (HB) region via the femoral veins. After the catheters were placed, a 5000 IU intravenous heparin bolus was administered. The stimulation protocol consisted of two baseline cycle lengths (CL) of programmed stimulation in RA and RVA with up to two extra stimuli and burst pacing. Intravenous isoprenaline was available to induce tachycardia when necessary.

Focal AT was confirmed by the following criteria:

- the atrial activation sequence during tachycardia was different from that recorded during sinus rhythm
- the sequence of atrial activation during tachycardia differed from that obtained during ventricular stimulation with retrograde ventriculoatrial conduction
- V-A-A-V response after discontinuation of ventricular pacing
- Induction of tachycardia regardless of prolongation of the A-H interval
- temporary AV block during tachycardia

Right atrial mapping was also performed on the patient, who initially used the NaviStar system. (CARTO 3 system Biosense Webster, Johnson and Johnson). Activation time was measured from the onset of the local electrogram to a stable atrial electrogram recorded from the CS catheter.

The aortic sinus (AS) was also evaluated, as tachycardia was still inducible after focal ablation therapy in mapping in the RA and left atrium (LA). NCC was visualized retrogradely via the right femoral artery. The anatomical location of NCC was demonstrated by aortic root angiography. Once the location of the coronary ostium was confirmed, a 7Fr quadrapole catheter (NaviStar ThermoCool, Biosense Webster) with a 4-mm tip electrode was inserted into the NCC for mapping and ablation.

Tachycardia was induced with burst pacing stimulation. The post-vop response of tachycardia with variable VA was V-A-A-V. In the patient diagnosed with atrial tachycardia, the earliest CS recordings were proximal. The right atrium was mapped with the ablation catheter. The earliest A records were detected in the sensation region. Then the left system was switched and the NCC was mapped. The earliest A records were found in this region. Ablation was applied to this area. It was observed that the tachycardia slowed down and ended in the early period. Tachycardia was not induced by restimulation. At the patient's follow-up appointment 1 month later, it was observed that the palpitations and symptoms had subsided.

**Keywords:** Ablation, Aortic cusp, Atrial tachycardia, Electrocardiography, Mapping

**AuthorToEditor:** görece küçük bir üniversite olmamıza rağmen yeni başladığımız EPS maratonunda asistan olarak eğer kabul ederseniz ilk sunumum olacak. Saygılarımla Dr.Cem Korucu AFSÜ KARDİYOLOJİ -4.yıl Asistanı





# KARDİYOVASKÜLER AKADEMİ KONGRESİ

## & INTERNATIONAL ACADEMY OF YOUNG CARDIOLOGISTS

Elexus Hotel Girne. K.K.T.C.  
18-22 Eylül 2024

### [OP-30] SYNTAX-II Score and LDL-C / HDL-C Ratio In Non- STEMI patients

Cansu Ozturk, Onder Ozturk

*Health Sciences University of Turkey, Gazi Yasargil Education and Research Hospital, Diyarbakir, Turkey*

**Background:** Hyperlipidemia is a major risk factor for the development of CAD, with which individuals typically have elevated plasma low-density lipoprotein cholesterol (LDL-C) concentration as well as decreased circulating high-density lipoprotein cholesterol (HDL-C) level. High concentration of LDL possesses the ability to impair endothelium and induce oxidation, leading to atheromatous plaque formation and the narrowing of lumen. In contrast, HDL is a strongly inverse predictor of CAD with its properties to mediate cholesterol efflux from macrophages. The increase of low-density lipoprotein cholesterol (LDL-C) is widely accepted as an important factor in the occurrence of atherosclerosis. Previous researchs have found that a relationship between LDL-C/HDL-C and atherosclerosis progression. The aim of this study is investigate the relationship between SYNTAX-II score and LDL-C / HDL-C ratio in Non-STEMI patients.

**Material-Methods:** Sixty four (64) patients (39 male–25 female, mean age  $67.76 \pm 12.79$  years), who were hospitalized for an ACS and underwent coronary angiography, were included in the study. SYNTAX-II score, as an indicator of the severity of coronary artery disease (CAD), was calculated. We investigated the correlation between the LDL-C / HDL-C ratio and the SYNTAX-II of the Non-STEMI patients.

**Results:** The patients were divided into three groups according to the SYNTAX-II score: Group A (SYNTAX-II score: 1-22, n=21), group B: (SYNTAX-II score: 23-32, n=28), group C: (SYNTAX-II score: >32, n=15). There is a significant difference between groups according to age, hypertension, hyperlipidemia and biochemical parameters. Also, LDL-C / HDL-C ratio was significantly higher in Group-C patients (Table 1).

**Conclusion:** In this study, we found that there is a relation between SYNTAX-II score and LDL-C / HDL-C ratio in Non-STEMI patients. However, further studies are required.

**Keywords:** LDL-C/HDL-C ratio, SYNTAX-II score, coronary artery disease severity, myocardial infarction



# KARDİYOVASKÜLER AKADEMİ KONGRESİ

## & INTERNATIONAL ACADEMY OF YOUNG CARDIOLOGISTS

Elexus Hotel Girne, K.K.T.C.  
18-22 Eylül 2024

**Table 1: Clinical and laboratory parameters of patients.**

Variables	Group-A (n=21)	Group-B (n=28)	Group-C (n=15)	p value
Age (year)	53.85±5.03	70.42±4.03	82.26±11.81	<0.001
Gender (F/M)	6 / 15	12 / 16	7 / 8	0.471
Hypertension (n)	9	12	15	<0.001
Diabetes Mellitus (n)	9	9	7	0.590
Smoking (n)	15	18	8	0.536
Hyperlipidemia (n)	9	6	12	0.001
Glucose	125.64±52.67	176.85±99.33	256.46±178.35	0.002
Creatinin	0.82±0.11	0.74±0.10	1.07±0.12	<0.001
eGFR	93.92±4.86	88.16±7.72	56.20±10.62	<0.001
Total protein	65.40±3.56	70.10±7.71	66.41±7.08	0.095
Albumin	36.50±2.89	36.10±4.03	30.86±3.22	<0.001
Sodium	137.57±1.43	139.25±1.75	136.06±0.70	<0.001
Potassium	4.09±0.40	4.26±0.35	4.42±0.39	0.036
Total cholesterol	157.80±38.21	185.18±60.13	201.43±42.19	0.038
LDL cholesterol	91.13±22.01	133.29±40.95	146.22±74.24	0.010
HDL cholesterol	41.95±8.75	41.26±11.46	32.97±5.74	0.012
Triglyceride	121.71±42.74	128.59±35.47	117.66±39.98	0.693
Admission Troponin	82.75±92.36	256.82±346.67	769.75±745.73	0.001
HbA1c	5.64±0.24	6.94±2.52	9.08±2.02	0.001
Hemoglobin	14.68±1.92	13.21±1.89	12.56±1.67	0.003
Platelet	317.14±58.87	323.71±67.59	216.53±49.57	<0.001
LVEF (%)	55.71±4.45	52.42±5.97	49.66±9.72	0.015
LDL-C / HDL-C	2.89±0.91	3.26±1.13	3.41±1.25	0.013



# KARDİYOVASKÜLER AKADEMİ KONGRESİ

## & INTERNATIONAL ACADEMY OF YOUNG CARDIOLOGISTS

Elexus Hotel Girne, K.K.T.C.  
18-22 Eylül 2024

### [OP-31] The relationship between in-hospital mortality and systemic immune inflammation index in patients hospitalized with ST elevation and developing heart failure

Kamuran Kalkan, Mehmet Erdoğan, Burak Kardeşler, Hafize Corut Güzel, Nedret Ülvan, Serdal Baştuğ  
Ankara Bilkent City Hospital

**Introduction:** Heart failure (HF) may develop in patients with ST elevation myocardial infarction (STEMI). HF is associated with increased in-hospital and long-term mortality and morbidity. Systemic immune -inflammation index = platelet count x neutrophil count/lymphocyte count ratio is a parameter reflecting the inflammatory status which has been shown to be associated with coronary artery disease, heart failure and arrhythmias. In our study, we aimed to investigate whether the SII value predicts in-hospital death due to HF after presentation with STEMI.

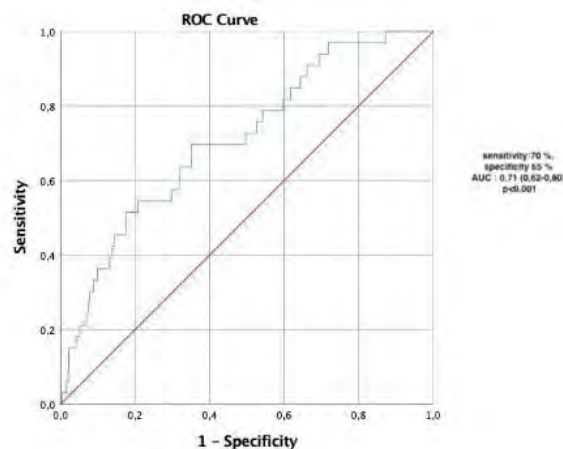
**Methods:** The study included 1413 patients admitted to our clinic with STEMI. All patients underwent primary percutaneous intervention. Echocardiography of the patients' during hospitalization was noted. Patient data were obtained from the hospital automation system and patient files. Patients with EF <40% were considered to have reduced EF heart failure (n: 714). We identified 36 patients with HF-related mortality. The groups with and without mortality were compared. The association of baseline SII values with in-hospital HF-related mortality was investigated.

**Results:** The mean age of the patients was 64± years, 62% were male. In the HF group, mean age, baseline creatinine and troponin values were higher, while baseline hemoglobin values were lower (p< 0.05). In addition, the rate of no-reflow was 35% in the mortal group and 11.2% in the other group (p< 0.001). In the ROC analysis, the cut-off value for SII in terms of prediction of in- hospital mortality due to HF was 1661, sensitivity: 70%, specificity 65% AUC: 0.71 (0.62-0.80) p<0.001.

**Conclusion:** In our study, we found that the SII value predicts in-hospital HF-related death in STEMI patients. In this context, this parameter, which can be calculated easily and cost-effectively, may be helpful in the follow-up and treatment of STEMI.

**Keywords:** STEMI, heart failure, in-hospital mortality, systemic immune -inflammation index

### Figure



Receiver operating characteristics (ROC) showed that level of  $\leq 1661$  predicted in-hospital mortality with a sensitivity of 70% and a specificity of 65% (area under the curve [AUC]: 0.71, 95%CI: 0.72-0.80, P < 0.001). AUC, area under the curve



# KARDİYOVASKÜLER AKADEMİ KONGRESİ

## & INTERNATIONAL ACADEMY OF YOUNG CARDIOLOGISTS

Elexus Hotel Girne, K.K.T.C.  
18-22 Eylül 2024

### [OP-32] Caught in the Current: A Case of Free Floating Thrombus in Right Heart

Halenur Sarıbaşı

*Ardahan State Hospital, Ardahan, Turkey*

**Introduction:** Right heart thrombus(RHT), also known as clot in transit, is a finding that has been associated with an increased mortality rate in pulmonary embolism(PE)(1). It has been reported that approximately 3-23% of patients with PE present with concomitant RHT(1,2). Despite numerous trials investigating the treatment of PE, there is no clear consensus regarding the management of PTE accompanied by RHT. This case study presents a case of PTE with a concomitant mobile RHT.

**Case Presentation:** A 73-year-old female patient presents to the emergency department with complaints of chest pain, weakness and shortness of breath for 4 days. Upon admission, an electrocardiogram reveals incomplete right bundle branch block and sinus tachycardia, with a heart rate of 112 beats per minute. The patient's blood pressure is 110/60 mmHg, respiratory rate is 34 breaths/min and oxygen saturation is 86% on 100% oxygen.

PE is identified on computed tomography pulmonary angiography(CTPA) in bilateral pulmonary arteries. Transthoracic echocardiography(TTE) reveals a highly mobile intracardiac thrombus, approximately 5x0.5 cm in size, protruding from the tricuspid valve into the right ventricle. The patient's right ventricular basal diameter is 46 mm, right ventricular tissue Doppler imaging systolic velocity is 11.4 cm/sec, tricuspid annular plane systolic excursion is 18 mm, systolic pulmonary artery pressure is 42 mmHg and McConnell sign is positive. The CTPA images of the patient are presented in Figure 1, and the TTE images are presented in Figure 2.

The patient's troponin value is 86 pg/ml(upper limit 14pg/ml), her PESI score is calculated as 133 and her sPESI score is 2. In accordance with the 2019 ESC PE guidelines, the patient, who is classified as intermediate-high risk PE, is transferred to the intensive care unit and initiated on unfractionated heparin treatment(3). During the subsequent follow-up of the patient, intermittent TTE demonstrated that the RHT had disappeared by the fourth day. A lower extremity venous Doppler ultrasound did not indicate the presence of a deep venous thrombosis. The patient was diagnosed with ovarian cancer. Following a 10-day hospitalisation, the patient was discharged on a regimen of warfarin therapy.

**Discussion:** There are several treatment strategies available for RHT with concomitant PE, including anticoagulation, systemic thrombolysis and surgical therapies, but there is a paucity of clinical data and guidelines on the treatment and management of RHT. While there are studies in the literature that highlight thrombolytic therapy, there are also studies that state there is no difference between these treatment strategies(1,2,4,5).

**Conclusion:** We believe that it would be appropriate to decide the treatment of these patients based on the clinical course with close haemodynamic monitoring. Further prospective randomized trials are needed to determine the optimal therapeutic strategies.

**Keywords:** clot in transit, pulmonary embolism, right heart thrombus



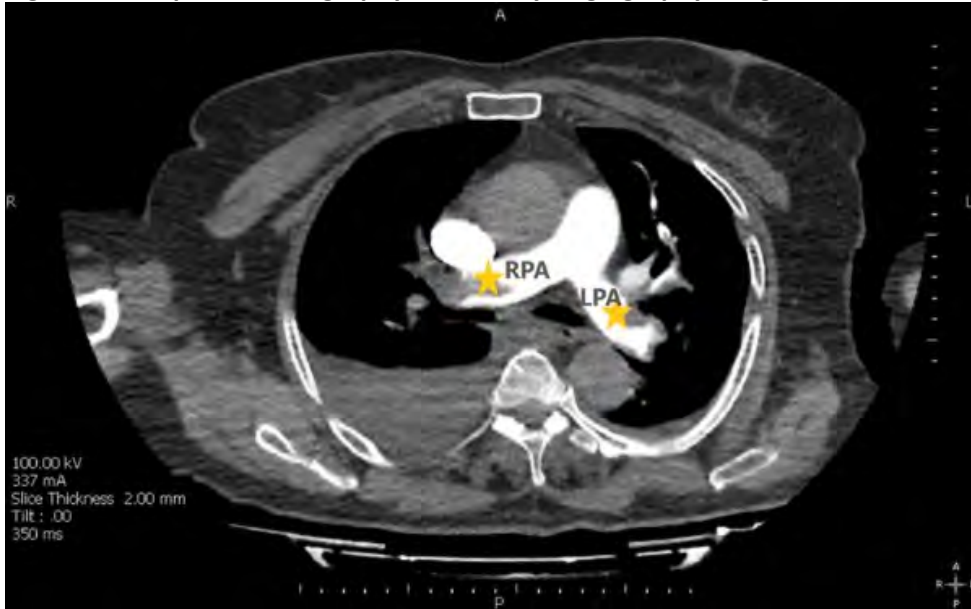

# KARDİYOVASKÜLER AKADEMİ KONGRESİ

## & INTERNATIONAL ACADEMY OF YOUNG CARDIOLOGISTS

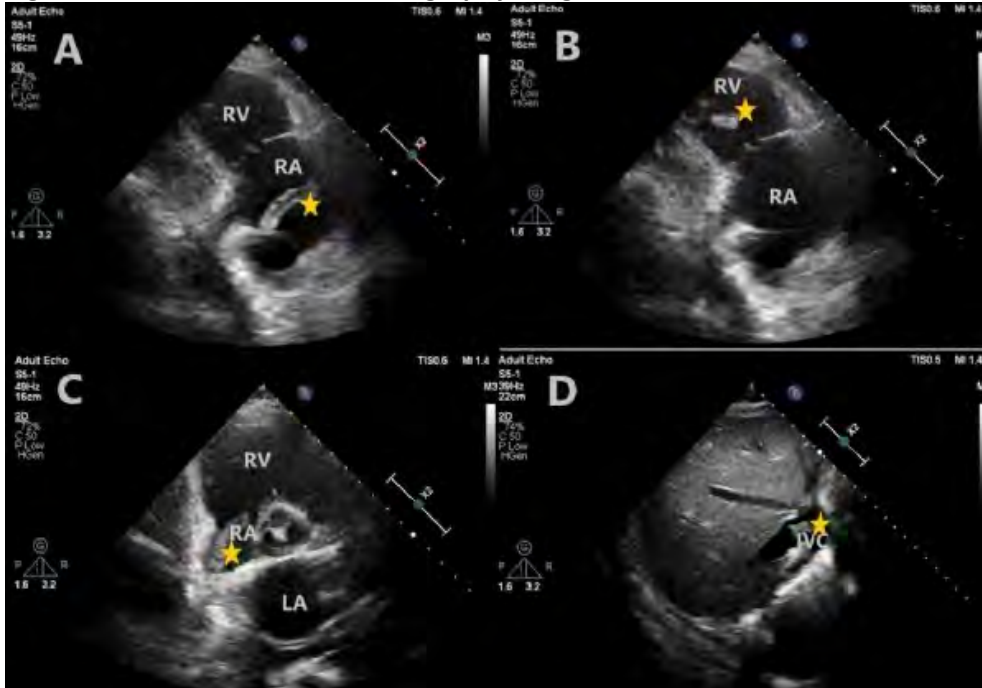
Elexus Hotel Girne, K.K.T.C.  
18-22 Eylül 2024

**Figure 1: Computed Tomography Pulmonary Angiography Image**



The presence of a thrombus is indicated by the star symbol. RPA:Right Pulmonary Arter, LPA: Left Pulmonary Arter

**Figure 2: Transthoracic echocardiography images**



A:Free floating thrombus in RA, B:Free floating thrombus in RV, C:Thrombus in RA in parasternal short axis plane. D:Thrombus in IVC. The presence of a thrombus is indicated by the star symbol. RA:Right Atrium, RV: Right Ventricle, LA:Left Atrium, IVC:Inferior Vena Cava



# KARDİYOVASKÜLER AKADEMİ KONGRESİ

## & INTERNATIONAL ACADEMY OF YOUNG CARDIOLOGISTS

Elexus Hotel Girne. K.K.T.C.  
18-22 Eylül 2024

### [OP-34] The Association Between Stroke Severity and LDL-C / HDL-C Ratio in Acute Ischemic Stroke Patients

Unal Ozturk<sup>1</sup>, Cansu Ozturk<sup>2</sup>

<sup>1</sup>Health Sciences University of Turkey, Gazi Yasargil Education and Research Hospital, Department of Neurology, Diyarbakir, Turkey

<sup>2</sup>Health Sciences University of Turkey, Gazi Yasargil Education and Research Hospital, Department of Cardiology, Diyarbakir, Turkey

**Background:** Acute ischemic stroke (AIS) is the most common type of stroke, accounting for about 80% to 90% of all stroke. AIS is a leading cause of death and disability worldwide. The most significant risk factors for the development of AIS are hypertension, diabetes mellitus, stenosis of the internal carotid arteries, cardiovascular disease, smoking and hyperlipidemia. Previous studies have shown that the level of plasma LDL in patients with acute coronary syndrome were significantly increased. LDL-C / HDL-C were significant parameter for estimating the risk of ischemic heart disease, and the diagnostic value is superior to the traditional lipid markers. The aim of this study is researching the association between stroke severity and LDL-C / HDL-C ratio in acute ischemic stroke patients.

**Methods:** This study included 119 patients with AIS. The severity of the neurological disorders was evaluated on the NIHSS. Neurological deficit severity evaluation with NIHSS were recorded on admission to the neurology clinic. Patients were divided into two groups based on the calculated NIHSS score (Group A, NIHSS score <16; Group B, NIHSS score ≥16). Clinical, demographic and laboratory parameters for all patients were recorded. We investigated the relation between the LDL-C / HDL-C ratio and stroke severity in acute ischemic stroke patients.

**Results:** The patients were divided into two groups according to the NIHSS score: Group A (NIHSS score <16, n=78), Group B: (NIHSS score ≥16, n=41). There is a significant difference between groups according to age, hypertension, diabetes, hyperlipidemia and biochemical parameters. Also, LDL-C / HDL-C ratio was significantly higher in Group-B patients (Table 1).

**Conclusions:** Our results suggest that LDL-C / HDL-C is associated with stroke severity on admission in patients with acute ischemic stroke. However, further studies are required.

**Keywords:** ischemic stroke, stroke severity, LDL/HDL ratio



# KARDİYOVASKÜLER AKADEMİ KONGRESİ

## & INTERNATIONAL ACADEMY OF YOUNG CARDIOLOGISTS

Elexus Hotel Girne, K.K.T.C.  
18-22 Eylül 2024

**Table 1**

Variables	Group-A (NIHSS score <16) (n=78)	Group-B (NIHSS score >=16) (n=41)	p value
Age (year)	45.24±19.22	69.05±12.57	<0.001
Gender (F/M)	42/36	15/26	0.085
Hypertension (n)	12	17	0.037
Diabetes Mellitus (n)	15	19	0.014
Smoking (n)	17	11	0.058
Hyperlipidemia (n)	23	22	0.026
Glucose	115.37±47.53	158.73±73.40	0.001
Creatinin	0.79±0.20	1.01±0.67	0.044
eGFR	89.17±5.76	76.18±8.93	0.043
Total protein	79.9±8.74	71.64±6.65	0.034
Albumin	38.66±10.73	33.43±4.37	<0.001
Sodium	136.62±3.38	137.51±3.50	0.178
Calcium	9.02±0.55	9.22±0.58	0.070
Total cholesterol	165.51±32.56	192.81±38.88	<0.001
LDL cholesterol	100.27±27.74	127.21±37.21	<0.001
HDL cholesterol	41.82±11.44	38.61±9.59	0.128
Triglyceride	117.46±50.87	135.83±69.49	0.103
Leucoyte	8.10±2.45	12.43±4.30	<0.001
HbA1c	5.81±3.57	7.68±4.75	0.002
Hematocrit	42.17±5.99	41.46±6.76	0.558
Platelet	243.34±106.76	258.56±102.14	0.455
LVEF (%)	58.62±3.95	51.27±6.49	0.027
LDL-C / HDL-C	2.84±1.33	3.38±1.92	0.011

*Demographic and laboratory variables of patients.*



# KARDİYOVASKÜLER AKADEMİ KONGRESİ

## & INTERNATIONAL ACADEMY OF YOUNG CARDIOLOGISTS

Elexus Hotel Girne. K.K.T.C.  
18-22 Eylül 2024

### **[OP-35] Successful Management of Coexisting Acute Coronary Syndrome and Pulmonary Embolism with High Mortality Risk**

Seyhmus Atan, Nil Özyüncü, İrem Müge Akbulut Koyuncu, Kerim Esenboğa, Nur Aydınalp  
*Department Of Cardiology, Ankara University Faculty Of Medicine, Ankara*

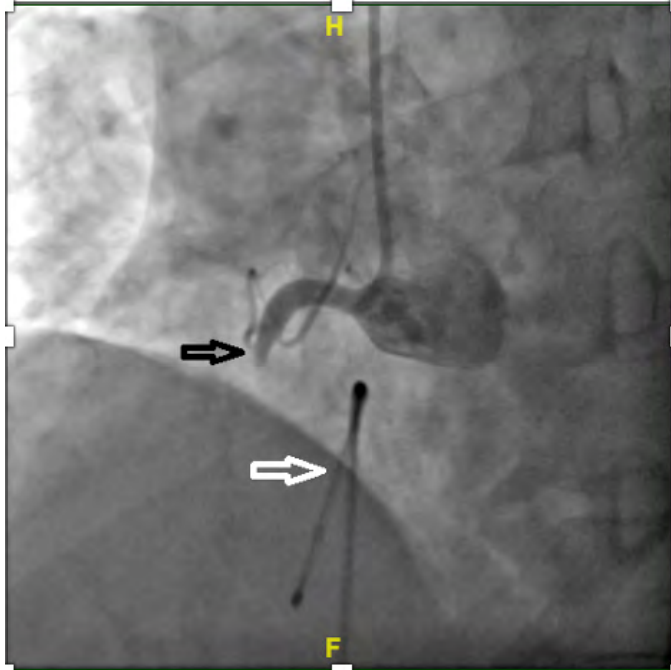
Acute ST-segment elevation myocardial infarction and pulmonary embolism are life-threatening cardiac emergencies. In the literature, acute coronary syndrome complicated by acute pulmonary emboli on follow-up is rare. In this case report, we presented a 73-year-old male patient presenting to the emergency department with two different acute clinical conditions 5 days apart. The first presentation was sudden onset of retrosternal chest pain and electrocardiography showed nodal rhythm and ST-segment elevation in leads D2, D3-AVF. The diagnosis was inferior acute myocardial infarction. Because of the nodal rhythm, a temporary pacemaker electrode was implanted under fluoroscopy. Coronary angiography revealed complete occlusion of the proximal right coronary artery and percutaneous coronary intervention was performed. Two days after discharge, he presented to the emergency department with presyncope, chest pain, and progressive dyspnoea. Pulmonary computed tomographic angiography revealed a massive thrombus in the pulmonary artery from the bifurcation level and filling defects consistent with pulmonary embolism. Since the patient was hemodynamically unstable, thrombolytic therapy was performed in the coronary intensive care unit and a successful clinical response was achieved. In this case report, we summarized a hemodynamically unstable patient who presented with two different life-threatening clinical conditions 5 days apart and was treated effectively by interventional cardiological and pharmaco-mechanical means.

**Keywords:** Acute, Coronary Syndrome, Pulmonary Embolism

---

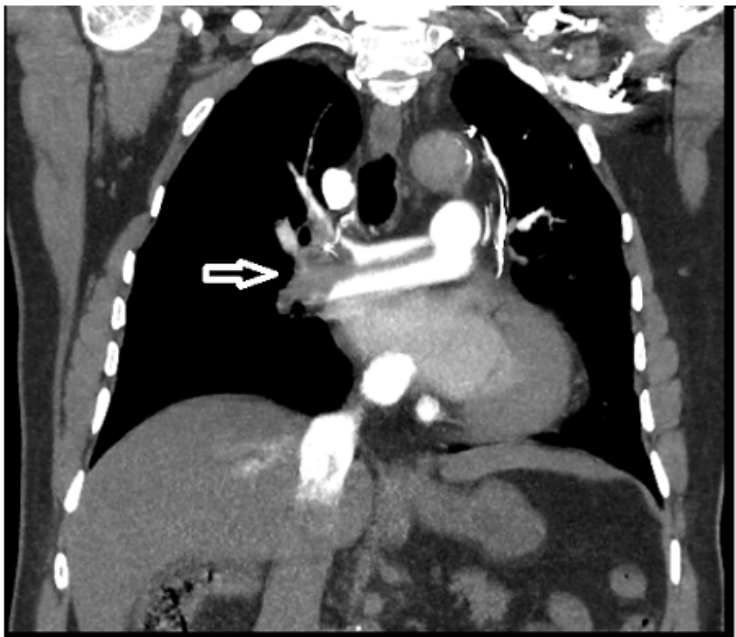

**Figure 1**



*Black arrow: Proximally totally occluded RCA, White arrow- TM-PM electrode in the right ventricular cavity*

**Figure 2**



*White arrow: Filling defect at the right-left pulmonary artery junction consistent with PTE.*



# KARDİYOVASKÜLER AKADEMİ KONGRESİ

## & INTERNATIONAL ACADEMY OF YOUNG CARDIOLOGISTS

Elexus Hotel Girne. K.K.T.C.  
18-22 Eylül 2024

### [OP-36] Shock index is an indicator of subclinical cardiotoxicity in patients receiving anthracycline chemotherapy

Muhammet Dural<sup>1</sup>, Furkan Yetmiş<sup>2</sup>, Cihat Çalışkan<sup>1</sup>

<sup>1</sup>Eskişehir Osmangazi University, Department of Cardiology, Eskişehir

<sup>2</sup>Muş State Hospital, Cardiology Department, Muş

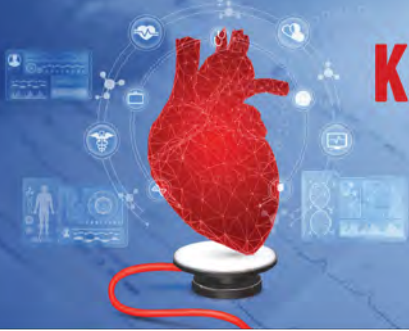The shock index (SI), modified shock index (MSI), and age shock index (ASI), which can be calculated at the bedside, have been used initially to evaluate patients with various clinical conditions that cause cardiovascular issues such as bleeding and pulmonary embolism. Changes in global longitudinal strain (GLS) are also considered an early sign of cancer therapy-related cardiac dysfunction. A reduction of >15% in GLS indicates the development of subclinical cardiotoxicity.

The aim of this study is to evaluate the relationship between shock indices calculated one month after chemotherapy and subclinical cardiotoxicity in patients receiving anthracycline chemotherapy over the first year.

This study included 51 breast cancer patients who received anthracycline chemotherapy at our center between February 10, 2020, and June 30, 2022. Echocardiography was performed at 1 month and 1 year after chemotherapy. Accordingly, the patients were followed for one year. Due to the relatively small number of patients, subclinical cardiotoxicity was defined as a >15% reduction in GLS. Systolic blood pressure (SBP), diastolic blood pressure (DBP), mean arterial pressure (MAP), and heart rates (HR) measured during the first month after chemotherapy were used as references to calculate the shock index (HR/SBP), modified shock index (HR/MAP), and age shock index (Age×SI) using appropriate formulas. Patients were divided into two groups based on whether they developed subclinical cardiotoxicity by the first-year echocardiographic evaluation compared to baseline GLS values. A total of 51 female breast cancer patients [mean age 49.3 ± 10.7 years] were included. Of these patients, 14 (27.5%) received Adriamycin, 30 (58.8%) received Doxorubicin, and 7 (13.7%) received Epirubicin. At the end of the first year, 12 patients (23.5%) were found to have developed subclinical cardiotoxicity. Baseline pro-BNP (67.6±50.0 vs 79.6±56.0, p=0.535) and total chemotherapy doses received (410.1±58.4 vs 388.6±101.3, p=0.490) were similar between the two groups. The ejection fraction (62.2±4.8 vs 65.0±3.4, p=0.036) and GLS value measured at the end of the first year (-18.7±1.6 vs -20.1±2.2, p=0.025) were significantly lower in the group that developed subclinical cardiotoxicity. SI (0.79±0.16 vs 0.64±0.13, p=0.002), MSI (1.0±0.19 vs 0.9±0.20, p=0.025), and ASI (38.4±11.3 vs 31.7±8.6, p=0.034) values were significantly higher in the subclinical cardiotoxicity group compared to the non-cardiotoxicity group. In the ROC curve analysis, the area under the curve (AUC) for shock index was calculated as 0.752 with 58.3% sensitivity and 92.3% specificity (p = 0.003). The predictive value of the shock index for demonstrating subclinical cardiotoxicity in patients receiving chemotherapy was determined to be >0.83.

The shock index may be a predictor in identifying the patient group at risk of developing subclinical cardiotoxicity among those receiving anthracycline chemotherapy.

**Keywords:** The shock index, subclinical cardiotoxicity, anthracycline chemotherapy

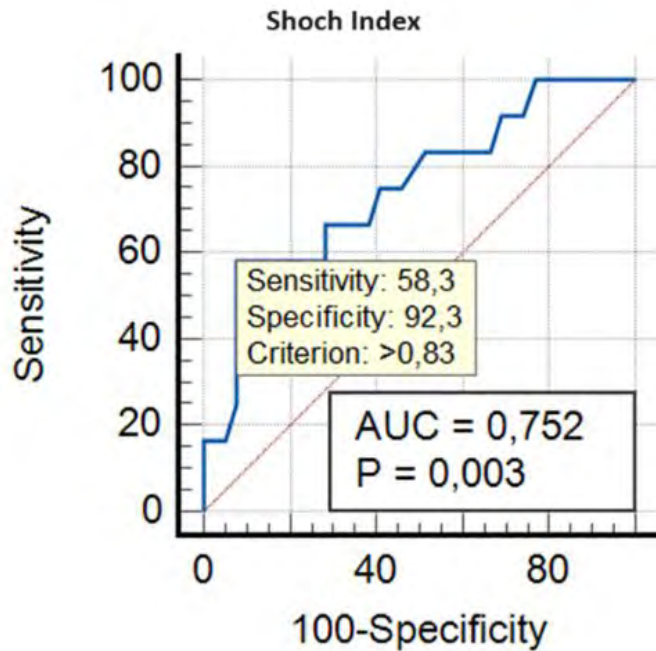


# KARDİYOVASKÜLER AKADEMİ KONGRESİ

## & INTERNATIONAL ACADEMY OF YOUNG CARDIOLOGISTS

Elexus Hotel Girne, K.K.T.C.  
18-22 Eylül 2024

### Roc curve analysis



### Hemodynamic and echocardiographic characteristics between groups developing and not developing subclinical cardiotoxicity

	Those developing cardiotoxicity (n=12)	Those not developing cardiotoxicity (n=39)	p value
Bazal_EF	65.4±2.0	65.5±2.8	0.924
Bazaş_HR	79.2±8.3	78.3±13.6	0.823
1_month_EF	64.6±2.6	65.0±2.6	0.678
1_month_GLS	21.6±1.9	20.4±2.3	0.117
1_month_HR	82.3±13.1	78.5±13.9	0.408
SI	0.79±0.16	0.64±0.13	0.002
ASI	38.4±11.3	31.7±8.6	0.034
MSI	1.08±0.19	0.93±0.20	0.025
1_year_EF	62.2±4.8	65.0±3.4	0.036
1_year_GLS	18.7±1.6	20.1±2.2	0.025
1_year_HR	79.7±10.6	77.3±10.4	0.495

SI: Shock Index EF: Ejection Fraction GLS: Global Longitudinal Strain HR: Heart Rate, ASI: Age-shock Index  
MSI: Modified Shock Index

### [OP-37] Bidirectional Ventricular Tachycardia in Fulminant Myocarditis: A Rare Presentation





# KARDİYOVASKÜLER AKADEMİ KONGRESİ

## & INTERNATIONAL ACADEMY OF YOUNG CARDIOLOGISTS

Elexus Hotel Girne, K.K.T.C.  
18-22 Eylül 2024

Emre Eynel<sup>1</sup>, Ahmet Can Çakmak<sup>1</sup>, Direnç Yılmaz<sup>2</sup>

<sup>1</sup>Department of Cardiology, Sakarya University Education and Research Hospital

<sup>2</sup>Department of Cardiology, Sancaktepe İlhan Varank Education and Research Hospital

**Objective:** Fulminant myocarditis is a rare but potentially fatal inflammatory cardiac disease characterized by rapid onset and sudden hemodynamic deterioration, which can lead to sudden death. Herein, we present a case of myocarditis presenting with bidirectional ventricular tachycardia and electrical storm, progressing to cardiogenic shock and death.

**Case Presentation:** A 30-year-old female presented with chest pain and new-onset palpitations lasting several days. There was no family history of cardiac disease, and she had no known chronic illnesses. She had a history of smoking but denied any medication or substance use. There were no symptoms of viral illness during administration. On physical examination, she was conscious with a blood pressure of 100/60 mmHg and a heart rate of 140 bpm. Bilateral basal rales were heard on lung auscultation. Oxygen saturation was 95% on room air. Laboratory findings were within normal limits, including complete blood count, high-sensitivity C-reactive protein, and white blood cell count. Electrolyte levels were normal. However, troponin levels were significantly elevated. The initial electrocardiogram revealed bidirectional VT (Figure 1). Transthoracic echocardiography showed an ejection fraction of 30% with anterolateral predominant global hypokinesia. Coronary angiography revealed normal coronary arteries. The patient was treated with intravenous metoprolol and lidocaine infusion and underwent attempted synchronized electrical cardioversion three times. Intravenous magnesium was administered as well. Overdrive pacing was initiated, achieving temporary resolution of the arrhythmia. During this period, the patient developed dyspnea and worsening rales. Hourly urine output decreased to 70 mL, and blood pressure dropped to around 90/60 mmHg. A slow infusion of furosemide was started, further reducing urine output. Signs of shock began to develop. Inotropic therapy was initiated, and an intra-aortic balloon pump was inserted. Subsequent monitoring showed polymorphic VT episodes (Figure 2). Additional intravenous magnesium was administered, and an amiodarone infusion was initiated. However, the patient continued to experience hemodynamically compromising monomorphic and polymorphic VT episodes. She did not respond to electrical cardioversion and subsequently developed resistant hypotension under IABP and inotropic agents including norepinephrine and dopamine, leading to cardiac arrest. Cardiopulmonary resuscitation efforts were unsuccessful.

**Conclusion:** Bidirectional VT is a rare arrhythmia often associated with digitalis intoxication but can also accompany ischemic heart disease, myocarditis, hypokalemia, or familial catecholaminergic polymorphic VT. As illustrated in our case, this arrhythmia can manifest as an electrical storm. It is crucial to consider the possibility of this arrhythmia in patients with myocarditis and promptly evaluate them for early hemodynamic support.

**Keywords:** myocarditis, bidirectional, ventricular, tachycardia

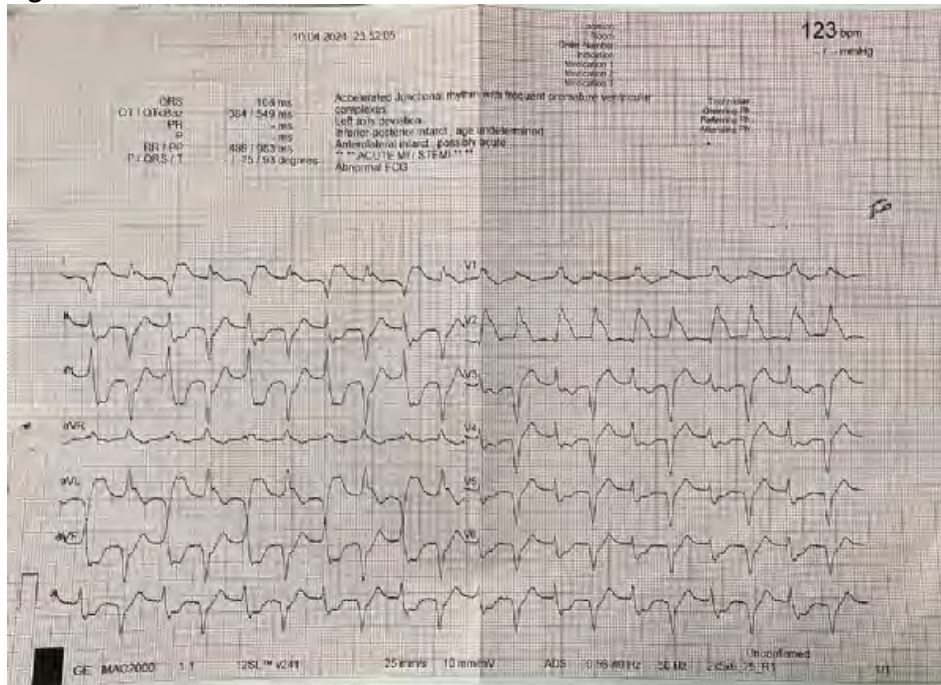


# KARDİYOVASKÜLER AKADEMİ KONGRESİ

## & INTERNATIONAL ACADEMY OF YOUNG CARDIOLOGISTS

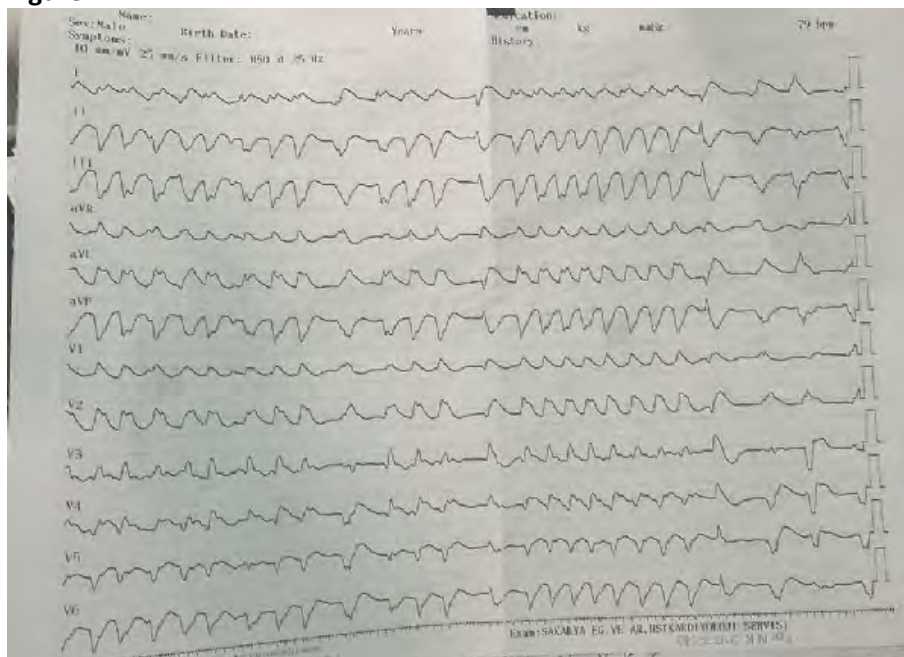
Elexus Hotel Girne, K.K.T.C.  
18-22 Eylül 2024

Figure 1



Electrocardiogram taken at admission showing Bidirectional Ventricular Tachycardia

Figure 2



Electrocardiogram taken during hemodynamic deterioration in follow-up: Polymorphic Ventricular Tachycardia



# KARDİYOVASKÜLER AKADEMİ KONGRESİ

## & INTERNATIONAL ACADEMY OF YOUNG CARDIOLOGISTS

Elexus Hotel Girne. K.K.T.C.  
18-22 Eylül 2024

### [OP-38] Cardioprotective effects of Dapagliflozin Against Radiotherapy Induced Cardiac Damage

Mevlüt Serdar Kuyumcu<sup>1</sup>, Mehmet Hakan Uzun<sup>2</sup>, Aziz Erden<sup>3</sup>, Sebahat Uluşan<sup>3</sup>, Seda Nur Aydoğdu<sup>3</sup>, Elif Özkan<sup>4</sup>, Alper Özseven<sup>4</sup>, Kanat Güllü<sup>5</sup>, Selim Sert<sup>6</sup>, Hüseyin Emre Cebeci<sup>6</sup>, Muhammet Ali Ekiz<sup>6</sup>, Adnan Karaibrahimoğlu<sup>6</sup>

<sup>1</sup>Isparta Süleyman Demirel University, Faculty of Medicine, Department of Cardiology

<sup>2</sup>Kütahya City Hospital, Department of Cardiology

<sup>3</sup>Isparta Süleyman Demirel University, Faculty of Medicine

<sup>4</sup>Isparta Süleyman Demirel University, Faculty of Medicine, Department of Radiation Oncology

<sup>5</sup>Isparta Süleyman Demirel University, Faculty of Medicine, Department of Histology and Embryology

<sup>6</sup>Isparta Süleyman Demirel University, Faculty of Medicine, Department of Biostatistics and Medical Informatics

**Background:** With increasing incidence of cancer among the adult population, radiotherapy (RT) is frequently used as a critical component in the treatment of various cancer types. Due to the nature of ionizing radiation, damage usually occurs within the tissues in anatomical neighborhood with the primary tumor localisation. Thus, it is common for patients receiving RT for tumors located in thorax to develop concomitant cardiac damage

Dapagliflozin (DAPA), originally developed as an oral anti-diabetic medication, has shown to have potent cardioprotective effects in the DAPA-HF trial. Various experimental trials based on this effect have shown DAPA has cardioprotective effects against various cardiotoxic factors

In this study, we aimed to investigate cardioprotective effects of Dapagliflozin against radiotherapy induced cardiac damage.

**Methods:** A total of 40 male Wistar albino rats were divided into 4 groups consisting of 10 each (control = 10, dapagliflozin = 10, radiotherapy = 10, radiotherapy + dapagliflozin = 10). Meanwhile, radiotherapy and radiotherapy + dapagliflozin groups received a single dose of 20 Gray (Gy) X-ray to 4 x 4 cm area at 0.62 Gy/min, and dapagliflozin and radiotherapy + dapagliflozin groups were gavaged daily with 10 mg/kg dapagliflozin. At the second week of the study, rats were examined by echocardiography and electrocardiogram. Furthermore, histopathological method was used to evaluate the level of cardiotoxicity.

**Results:** The cardiac measurements and electrocardiogram (ECG) results of the animals were compared before and after treatment. While both EF and DF decreased in both groups; the EF value decrease was statistically lower in the post-treatment period in the RT + DAPA group than RT group ( $p < 0.001$ ). In addition, FS values deteriorated more in the post-treatment period in the RT group compared with the RT + DAPA group ( $P < .001$ ). End-systolic and end-diastolic volume measurement deterioration was statistically significantly lower in the RT + DAPA group than the RT group ( $P < 0.001$ ). Heart rate values were significantly higher in the post-treatment period in both RT and RT + DAPA groups ( $P < 0.001$ ). PR, QRS and QTc values were measured, and deterioration was found to be statistically higher in the RT group than the RT + DAPA group ( $p < 0.001$ ). In histochemical evaluations, intracellular inflammatory filtration evaluation was found to be significantly higher in the RT group ( $P < .001$ ). The general filtration value of the group was found to be "severe." Similarly, sarcomyolysis and necrotic changes were significantly higher and "severe" in the RT group ( $P < .001$ ). While no positive results were found in the control and DAPA groups, low and moderate results were obtained in the RT + DAPA group.

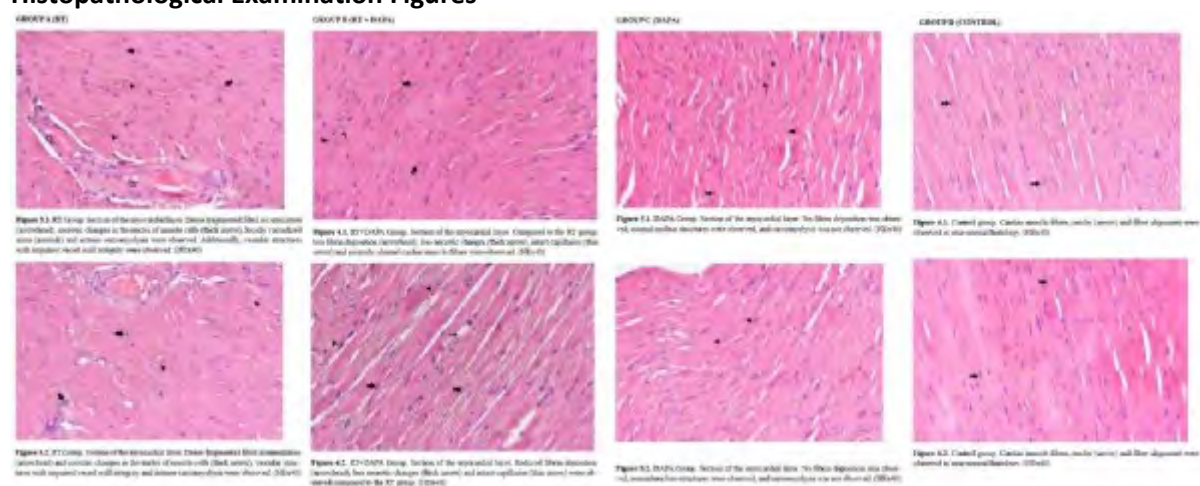


**Conclusions:** In our study, we observed the protective effects of DAPA against LV remodeling and dysfunction in RT-induced cardiomyopathy model.

**Fundings:** This research has been funded by TUBITAK.

**Keywords:** Cardiomyotoxicity, radiotherapy, dapagliflozin

### Histopathological Examination Figures



**Figure 3.1:** RT Group. Section of the myocardial layer. Dense fragmented fibril accumulation (arrowhead), necrotic changes in the nuclei of muscle cells (thick arrow), locally vacuolized areas (asterisk) and intense sarcomyolysis were observed. Additionally, vascular structures with impaired vessel wall integrity were observed. (HEx40)

**Figure 3.2:** RT Group. Section of the myocardial layer. Dense fragmented fibril accumulation (arrowhead) and necrotic changes in the nuclei of muscle cells (thick arrow), vascular structures with impaired vessel wall integrity and intense sarcomyolysis were observed. (HEx40)

**Figure 4.1:** RT+DAPA Group. Section of the myocardial layer. Compared to the RT group, less fibrin deposition (arrowhead), less necrotic changes (thick arrow), intact capillaries (thin arrow) and properly aligned cardiac muscle fibers were observed. (HEx40)

**Figure 4.2:** RT+DAPA Group. Section of the myocardial layer. Reduced fibrin deposition (arrowhead), less necrotic changes (thick arrow) and intact capillaries (thin arrow) were observed compared to the RT group. (HEx40)

**Figure 5.1:** DAPA Group. Section of the myocardial layer. No fibrin deposition was observed, normal nuclear structures were observed, and sarcomyolysis was not observed. (HEx40)

**Figure 5.2:** DAPA Group. Section of the myocardial layer. No fibrin deposition was observed, normal nuclear structures were observed, and sarcomyolysis was not observed. (HEx40)

**Figure 6.1:** Control group. Cardiac muscle fibers, nuclei (arrow) and fiber alignment were observed in near-normal histology. (HEx40)

**Figure 6.2:** Control group. Cardiac muscle fibers, nuclei (arrow) and fiber alignment were observed in near-normal histology. (HEx40)

# KARDİYOVASKÜLER AKADEMİ KONGRESİ

## & INTERNATIONAL ACADEMY OF YOUNG CARDIOLOGISTS

Elexus Hotel Gıme, K.K.T.C.  
18-22 Eylül 2024

### Study Protocol and Results Charts



Figure 1: Study Protocol Design. Figure 2.1: Basal and Week 2 Weight Charts Figure 2.2: Basal and Week 2 Ejection Fraction Charts Figure 2.3: Basal and Week 2 Fractional Shortening Charts Figure 2.4: Basal and Week 2 Left Ventricular End-Diastolic Dimension Charts Figure 2.5: Basal and Week 2 Left Ventricular End-Systolic Dimension Charts Figure 2.6: Basal and Week 2 Heart Rate Charts Figure 2.7: Basal and Week 2 QTC Duration Charts Figure 2.8: Basal and Week 2 PR Duration Charts Figure 2.9: Basal and Week 2 QR Duration Charts





# KARDİYOVASKÜLER AKADEMİ KONGRESİ

## & INTERNATIONAL ACADEMY OF YOUNG CARDIOLOGISTS

Elexus Hotel Girne, K.K.T.C.  
18-22 Eylül 2024

### Cardiac, Histochemical and ECG measurements of animals according to study groups

	Control	DAPA	RT	RT+DAPA			
	Mean±SD	Mean±SD	Mean±SD	Mean±SD	P groups	P measures	P groups*measure
First Measured Weight (gr)	323,20±58,66	310,00±55,70	325,50±15,09	325,10±25,34			
Last Measured Weight (gr)	320,80±57,91	281,60±47,25	308,70±28,18	257,00±18,62	0,515	<0,001*	0,024*
EF, baseline (%)	79,80±2,86	79,20±1,87	78,10±2,60	79,00±2,31			
EF, week 2 (%)	79,80±2,20	79,90±2,38	61,50±8,72	73,20±3,29	<0,001	<0,001	<0,001
FS, baseline (%)	47,40±3,24	47,40±4,14	48,70±3,92	48,80±4,44			
FS, week 2 (%)	47,20±3,52	48,00±4,24	39,70±5,79	42,40±5,56	0,200	<0,001*	<0,001*
End-diastolic volume, baseline (mL)	277,70±10,98	272,10±17,37	274,50±11,19	277,20±16,92			
End-diastolic volume, week 2 (mL)	276,40±9,97	268,20±17,22	310,30±37,53	282,80±12,99	0,033*	<0,001*	<0,001*
End-systolic volume, baseline (mL)	57,80±9,90	64,60±8,66	56,40±7,40	63,90±9,94			
End-systolic volume, week 2 (mL)	56,70±7,65	64,50±10,02	68,10±7,98	69,40±10,49	0,110	<0,001*	<0,001*
Heart rate, baseline (BPM)	321,70±24,76	342,50±29,69	345,10±14,69	341,90±25,24			
Heart rate, week 2 (BPM)	327,80±24,44	345,70±32,94	387,60±33,12	354,60±20,86	0,006*	<0,001*	<0,001*
QTc, baseline	172,00±18,38	168,00±14,16	169,60±12,29	173,90±16,76			



# KARDİYOVASKÜLER AKADEMİ KONGRESİ

## & INTERNATIONAL ACADEMY OF YOUNG CARDIOLOGISTS

Elexus Hotel Girne. K.K.T.C.  
18-22 Eylül 2024

(msn)							
QTc, week 2 (msn)	172,40±18,7	168,60±14,85	201,90±25,63	179,10±16,58	0.135	<0,001*	<0,001*
PR, baseline (msn)	42,70±6,53	41,20±4,54	42,60±4,01	44,10±6,26			
PR, week 2 (msn)	43,00±5,89	41,20±4,94	58,40±9,89	48,20±7,96	0,005*	<0,001*	<0,001*
QRS, baseline (msn)	14,30±2,21	14,20±1,81	14,60±2,95	14,80±2,04			
QRS, week 2 (msn)	14,50±2,17	14,50±1,90	19,90±4,77	16,70±2,31	0,019*	0,001*	0,001*
Inflammatory Cell Infiltration	0.2 ± 0.4 (0: 0-1)	0.2 ± 0.4 (0: 0-1)	2.8 ± 0.4 (3: 1-3)	1.0 ± 0.8 (0: 0-1)	0.001**		
Sarcomyolysis	0.0 ± 0.0 (0: 0-0)	0.0 ± 0.0 (0: 0-1)	3.2 ± 0.4 (3: 1-3)	1.0 ± 0.8 (0: 0-1)	<0.001*		
Necrotic Changes	0.0 ± 0.0 (0: 0-0)	0.0 ± 0.0 (0: 0-0)	3.0 ± 0.0 (3: 3-3)	1.4 ± 0.8 (0: 0-2)	<0.001*		

Data are given as mean ± standard deviation, number or median (interquartile range). BPM; beats per minute, EF; ejection fraction, FS; fractional shortening, ml; milliliters, msn; milliseconds, QTc; corrected QT interval, \*: Significant at the 0.05 level according to two-way Repeated Measure ANOVA \*\*: Significant at the 0.05 level according to one-way Measure ANOVA

**AuthorToEditor:** Dear Members of the Scientific Committee; Abstract page shows figures as low quality images. Links to high quality images are as below: <https://flic.kr/p/2q3qHAP> <https://flic.kr/p/2q3qHCn> In addition, our research hasn't been applied for publication elsewhere. With our best regards.



# KARDİYOVASKÜLER AKADEMİ KONGRESİ

## & INTERNATIONAL ACADEMY OF YOUNG CARDIOLOGISTS

Elexus Hotel Girne, K.K.T.C.  
18-22 Eylül 2024

### [OP-39] Hematological and Biochemical Parameters Predictive of Mortality in Heart Failure with Preserved Ejection Fraction (HFpEF) Patients

Selim Aydemir<sup>1</sup>, Sidar Şiyar Aydın<sup>2</sup>

<sup>1</sup>Department of Cardiology, Erzurum City Hospital, Erzurum, Turkey.

<sup>2</sup>Department of Cardiology, Atatürk University Faculty of Medicine, Erzurum, Turkey.

**Objective:** Heart failure (HF) is a medical condition defined by abnormalities in the structure or function of the ventricle. The prevalence of HF continues to increase worldwide. Heart failure with preserved ejection fraction (HFpEF) is the clinical condition in which signs and symptoms of HF occur as a result of high left ventricular (LV) filling pressure despite normal or near-normal LV ejection fraction (LVEF;  $\geq 50\%$ ). HFpEF accounts for approximately 50% of HF patients. Patient management is difficult due to complex symptoms, comorbidities, and different responses to treatment. HF is a disease that advances gradually and is related to increased mortality. Predicting mortality contributes to a more effective treatment approach, prognosis prediction, and patient follow-up. Our study aimed to evaluate parameters predictive of mortality in HFpEF patients.

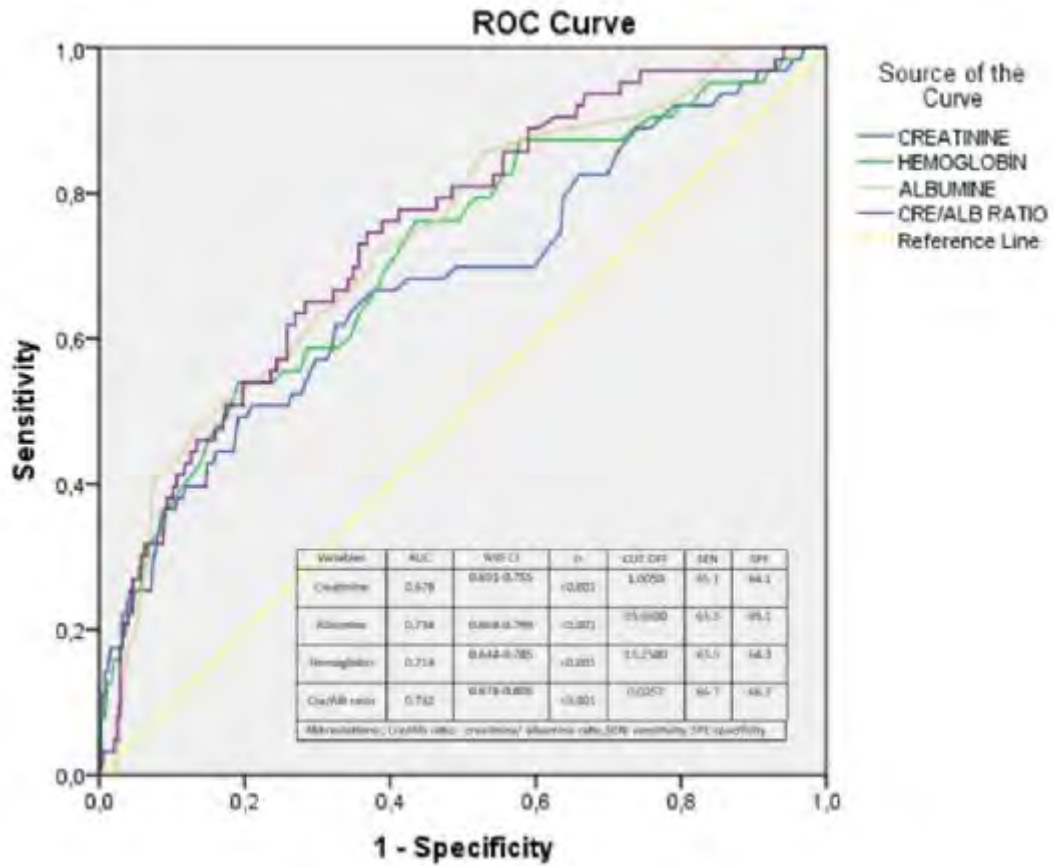
**Method:** We conducted a retrospective study including 724 patients who presented with clinical symptoms and findings at our clinic and were diagnosed with HFpEF using echocardiographic and laboratory data. The patient's demographic data, laboratory tests, medications used, and mortality status were recorded from the patient files from the hospital's electronic information system. Parameters with a significant relationship with mortality were identified and included in Cox regression analysis to investigate independent predictors. The predictive performance of the parameters for mortality was evaluated using receiver operating characteristic (ROC) curves. P value  $<0.05$  was considered significant.

**Results:** Our study included 724 patients who met the criteria. The average age of the patients was  $63.6 \pm 12.4$  years, and 41.6% were male. The prevalence of hypertension (HT) among the patients was 85.1%, diabetes mellitus (DM) was 20.9%, coronary artery disease (CAD) was 59.8%, atrial fibrillation (AF) was 51.1%, and cerebrovascular event (CVE) was 3.7%. The average follow-up period was 335 days. Mortality of HFpEF patients was 8.7% (63 patients). In the univariate and multivariate Cox regression analysis among the parameters significant in terms of mortality, hemoglobin [OR:0.784 95% CI (0.652-0.941),  $p=0.009$ ], albumin [OR: 0.944 95%CI (0.906-0.984),  $p=0.006$ ] and creatinine [OR:1.472 95%CI ((1.095-1.978),  $p=0.010$ )] was observed to independently predict mortality. The ROC Curve analysis revealed area under the curve values (AUC) values for hemoglobin, albumin, creatine, and the creatinine/albumin ratio [0.714, 0.734, 0.678, 0.742,  $p<0.001$ , respectively].

**Conclusion:** In our study, low hemoglobin, hypoalbuminemia, and high creatinine independently predicted mortality in HFpEF patients. The creatinine/Albumine ratio, derived from these parameters, demonstrated the highest predictive value. Simple, practical parameters used in routine can provide clinical benefits for prognosis, treatment strategy, patient follow-up, and management.

**Keywords:** HFpEF, Mortality, Creatinine/ Albumine ratio

### Receiver operating characteristic (ROC) curve analysis



Diagonal segments are produced by ties.





# KARDİYOVASKÜLER AKADEMİ KONGRESİ

## & INTERNATIONAL ACADEMY OF YOUNG CARDIOLOGISTS

Elexus Hotel Girne, K.K.T.C.  
18-22 Eylül 2024

### [OP-40] Predicting Mortality in Complicated Infective Endocarditis Using the RISK-E Score

Arzu Neslihan Akgün<sup>1</sup>, Senem Has Hasırcı<sup>2</sup>, Ezgi Polat Ocaklı<sup>1</sup>

<sup>1</sup>Ankara Etlik Şehir Hastanesi

<sup>2</sup>Başkent Üniversitesi Hastanesi

**Introduction:** Infective endocarditis (IE) affects the heart's endocardial surface, and can lead to systemic embolization (1). In our country, the mortality rates are 25-30%, and more than 50% of patients require cardiac surgery, and this is higher in left-sided infections (2,3). Olmos et al. developed the Risk-Endocarditis (RISK-E) score to predict perioperative mortality in patients undergoing cardiac surgery for left-sided IE (3). It excludes embolic complications and culture-negative IE. Our study includes these patients to assess the association of the RISK-E score with mortality and embolic events in complicated IE cases.

**Material-Method:** We retrospectively analyzed 32 IE patients admitted at Başkent University Hospital. IE confirmed according to the modified Duke Criteria (4). Complications were pseudoaneurysm, perforation, periannular abscess, and cerebrovascular septic emboli (CVE). The RISK-E score has 8 variables; age ( $\leq 51$ : 0; 52-63: 9; 64-72: 13 and  $\geq 73$  years: 14 points), prosthetic infection (6points), periannular complications (5points), Staphylococcus aureus +fungi infections (9points), acute renal failure (5points), septic shock (7points), cardiogenic shock (15points) and thrombocytopenia (7points).

**Results:** The mean age of the patients was  $63.5 \pm 14.8$  years. It was higher in deceased patients ( $p=0.247$ ). The average CRP level was higher in deceased patients ( $p=0.061$ ). A total of 37.5% experienced CVE. There was no statistically significant relationship was found between the RISK-E score and CVEs ( $p=0.083$ ). The left-sided IE was diagnosed in 87.5% of patients. There was no statistically significant difference observed between left and right sided IE in terms of RISK-E score ( $p=0.508$ ). The mean vegetation size was 1.42mm. There was no statistically significant relationship between the RISK-E score and vegetation size ( $p=0.629$ ). The blood culture was negative in 7 patients. There was no significant association between blood culture results and mortality ( $p=0.402$ ) or RISK-E scores (positive:  $29.5 \pm 14.2$ , negative:  $20.8 \pm 11.1$ ;  $p=0.418$ ). The average RISK-E score was found to be  $27.6 \pm 13.9$ . According to the RISK-E score, the mean postoperative mortality percentage was 38.9%. We found the overall mortality rate to be 46.9%. The mean RISK-E score was  $36.8 \pm 12.7$  in deceased patients and  $19.6 \pm 9.3$  in survivors, showing a significant association with mortality ( $p < 0.001$ ).

**Discussion:** The RISK-E score has been shown to be useful in evaluating total mortality in our study. Our mortality was higher than expected. We believe this is due to the inclusion of complicated IE cases and advanced age of the patients.

It is important to note a positive correlation between RISK-E score, CRP levels, and vegetation size. However, these factors are not included in the calculation of the RISK-E score.

**Conclusion:** The significant association between the RISK-E score and overall mortality holds clinical importance in both practice and research.

**Keywords:** infective endocarditis, risk factors, mortality, embolic events

**AuthorToEditor:** Infective endocarditis (IE) is a disease with hospital mortality ranging from 15% to 30%. Each patient's risk and timing of surgery vary, requiring individualized decision-making. Many scores have been used only to evaluate surgical mortality. Currently, there is no scoring system to assist in showing the total mortality of IE patients in clinical practice. The RISK-E score was developed by Olmos and colleagues at three tertiary care centers in Spain. The RISK-E score does not include embolic complications and culture-negative infective endocarditis patients. In our study, we included patients



# KARDİYOVASKÜLER AKADEMİ KONGRESİ

## & INTERNATIONAL ACADEMY OF YOUNG CARDIOLOGISTS

Elexus Hotel Girne. K.K.T.C.  
18-22 Eylül 2024

with embolic complications and culture-negative infective endocarditis. We demonstrated its utility in assessing total mortality, but it is evident that large-scale studies involving a significant number of patients are needed to support these findings.



# KARDİYOVASKÜLER AKADEMİ KONGRESİ

## & INTERNATIONAL ACADEMY OF YOUNG CARDIOLOGISTS

Elexus Hotel Girne. K.K.T.C.  
18-22 Eylül 2024

### **[OP-41] Effect of dapagliflozin on the no-reflow phenomenon in patients with acute myocardial infarction and type II diabetes mellitus**

Ala Quisi<sup>1</sup>, Nur Selin Nacar<sup>2</sup>, Ömer Genç<sup>3</sup>, Abdullah Yıldırım<sup>4</sup>, Gökhan Alıcı<sup>4</sup>, Çağlar Emre Çağlıyan<sup>2</sup>

<sup>1</sup>Medline Adana Hospital, Department of Cardiology, Adana, Turkey

<sup>2</sup>Çukurova University Faculty of Medicine, Department of Cardiology, Adana, Turkey

<sup>3</sup>Basaksehir Cam & Sakura City Hospital, Department of Cardiology, Istanbul, Turkey

<sup>4</sup>Adana City Training and Research Hospital, Department of Cardiology, Adana, Turkey

**Objective:** This study aimed to assess the effect of dapagliflozin on the no-reflow phenomenon in patients with type II diabetes mellitus (T2DM) and acute myocardial infarction (AMI) who underwent percutaneous coronary intervention (PCI).

**Methods:** This single-center, cross-sectional observational study included a total of 829 consecutive T2DM patients who were diagnosed with AMI and underwent PCI within 24 hours of the onset of symptoms. Patients using dapagliflozin for more than one year were included in the analysis. The no-reflow phenomenon was defined as inadequate myocardial perfusion (coronary flow <Thrombosis in Myocardial Infarction grade III) within a segment of the coronary circulation without angiographic evidence of mechanical vessel obstruction, dissection, or residual stenosis after PCI.

**Results:** Four hundred and thirty-four patients were diagnosed with ST-segment elevation myocardial infarction (STEMI), and 395 patients were diagnosed with non-ST-segment elevation myocardial infarction (NSTEMI). The no-reflow phenomenon was observed in 16.6% of STEMI patients and in 14.9% of patients with NSTEMI. Forward conditional logistic regression analysis demonstrated that the estimated glomerular filtration rate, SYNTAX score I, and dapagliflozin use were independent predictors of the no-reflow phenomenon in STEMI patients. However, dapagliflozin use was the only independent predictor of the no-reflow phenomenon in NSTEMI patients.

**Conclusion:** Dapagliflozin use was significantly associated with lower rates of no-reflow phenomenon in T2DM patients who were diagnosed with AMI and underwent PCI.

**Keywords:** Acute myocardial infarction, no-reflow phenomenon, dapagliflozin, sodium-glucose co-transporter 2 inhibitor

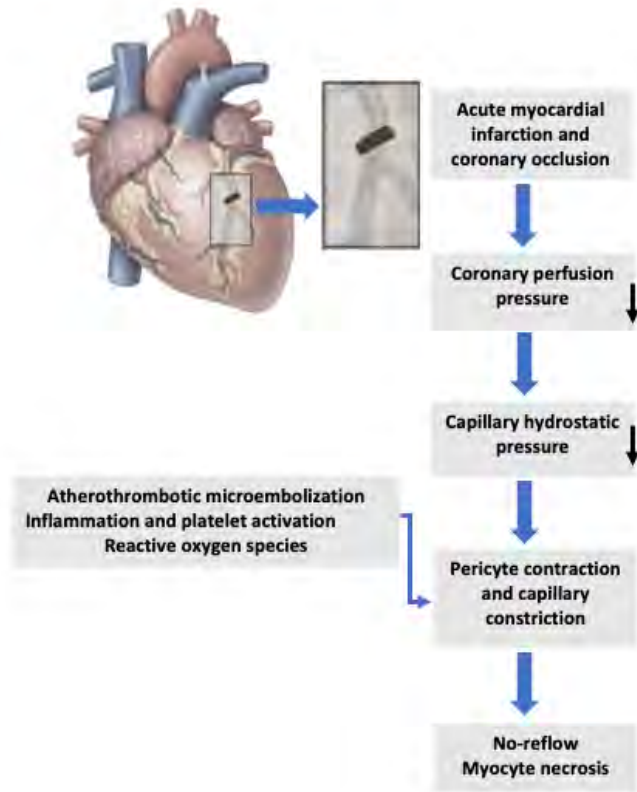


# KARDİYOVASKÜLER AKADEMİ KONGRESİ

## & INTERNATIONAL ACADEMY OF YOUNG CARDIOLOGISTS

Elexus Hotel Girne, K.K.T.C.  
18-22 Eylül 2024

### Mechanism of no-reflow during acute myocardial infarction



### Regression Analysis of No-Reflow Phenomenon in STEMI patients

Variable	Univariate Analysis		Multivariate Analysis	
	OR (95% CI)	P Value	OR (95% CI)	P Value
Age (yr)	1.035 (1.011 - 1.060)	0.005	-	-
LVEF (%)	0.959 (0.930 - 0.989)	0.008	-	-
Hemoglobin (g/dL)	0.885 (0.772 - 1.016)	0.082	-	-
Estimated GFR (ml/min/1.73 m <sup>2</sup> )	0.974 (0.956 - 0.991)	0.004	0.940 (0.900 - 0.982)	0.006
LDL cholesterol (mg/dL)	1.008 (1.001 - 1.015)	0.021	-	-
CRP (mg/dL)	1.038 (1.010 - 1.068)	0.008	-	-
SYNTAX score I	1.104 (1.070 - 1.139)	0.001	1.338 (1.179 - 1.520)	<0.001
Dapagliflozin use	0.490 (0.253 - 0.947)	0.034	0.030 (0.004 - 0.228)	0.001

**AuthorToEditor:** Tablo sayısı 1 tabloyla sınırlandırıldığı için NSTEMI hastalarındaki regresyon analizi tablosunu yükleyemedik. Detaylarını sunumda paylaşacağız.

### [OP-42] Impact Of Hemodialysis On Left Atrial Functions





# KARDİYOVASKÜLER AKADEMİ KONGRESİ

## & INTERNATIONAL ACADEMY OF YOUNG CARDIOLOGISTS

Elexus Hotel Girne, K.K.T.C.  
18-22 Eylül 2024

Muge Akbulut, Bilge Naz Ateş, Cansın Tulunay Kaya  
Ankara University

### The Impact Of Hemodialysis On Left Atrial Functions

**Introduction:** Left ventricular hypertrophy and dysfunction are prevalent cardiac complications in patients undergoing chronic hemodialysis (HD). Diastolic dysfunction is also common due to abnormal volume and pressure load. The left atrium (LA), a heart chamber highly sensitive to diastolic dysfunction and volume overload, is of particular interest. However, the impact of hemodialysis on left atrial functions is less well understood compared to its effects on the left ventricle. In the present study, we aimed to evaluate the effect of a hemodialysis session on left atrial functions in chronic hemodialysis patients. **Materials:** We included fifty-five patients with end stage renal disease on chronic hemodialysis treatment in the study. A comprehensive trans-thoracic echocardiography was performed immediately before and after a hemodialysis session. **Results:** The mean LA reservoir, conduit, and contractile strain values prior to HD were 21.14, -10.99, and -10.45 respectively. Following the HD session, the mean LA reservoir, conduit and contractile strain values were 18.08, -11.2, and -9.1 respectively. The mean LA reservoir strain was significantly reduced following the HD session ( $p=0.032$ ). However, no meaningful change was observed in conduit and contractile functions after HD ( $p=0.855$  &  $p=0.093$ , respectively). **Conclusion:** Hemodialysis affects left atrial functions. Following a hemodialysis session, the left atrial reservoir function significantly decreases. In contrast, left atrial conduit and contractile functions, the measures of active deformation, do not alter significantly following a hemodialysis session in patients with end stage renal disease.

**Keywords:** left atrial function, hemodialysis, speckle tracking echocardiography

**Table 1.**

	Prior to HD	After HD
LA volume (minimum, ml)	27,01±11,83	21,85±13,76
LA volume (maximum, ml)	54,6±16,47	43,75±21,73
LA EF (%)	51,8±10,28	51,02±11,06
LA Sr (reservoir, %)	21,14±13,52	18,08±8,45
LA Sr (conduit, %)	-10,99±6,58	-11,2±7,51
LA Sr (contractile, %)	-10,45±11,41	-9,1±6,22
LA Sr rate (reservoir, %)	27±13,82	22,59±10,71
LA Sr rate (conduit, %)	-11,49±8,42	-10,75±7,88

*Left atrial functions prior to and after the hemodialysis session.*



# KARDİYOVASKÜLER AKADEMİ KONGRESİ

## & INTERNATIONAL ACADEMY OF YOUNG CARDIOLOGISTS

Elexus Hotel Girne, K.K.T.C.  
18-22 Eylül 2024

### [OP-43] A case Report: All in One:Challenges and Innovations in TAVI and PBV Procedures

Yakup Alsancak, Ahmet Seyfettin Gürbüz, Muhammed Fatih Kaleli, Mehmet Akif Düzenli  
*Necmettin Erbakan University Faculty of Medicine Department of Cardiology*

More than one-third of patients with valvular heart disease are affected by multivalvular disease, posing unique diagnostic and treatment challenges. In this case report, we present the case of an elderly man who had both mitral stenosis and aortic stenosis and was at high surgical risk.

A 69-year-old male patient presented to the emergency department with chest pain and dyspnea. He had hypertension and coronary artery disease. Atrial fibrillation was noted on electrocardiogram, with fine inspiratory crackles in both lung fields. Classified as NYHA Class IV, he was sent to the intensive care unit. On transthoracic echocardiography: severe tricuspid regurgitation; aortic stenosis with max gradient 42 mmHg, mean gradient 24 mmHg, and AVA 1.0 cm<sup>2</sup>; mild aortic regurgitation; mitral stenosis with max gradient 20 mmHg, mean gradient 11 mmHg, and MVA 0.6 cm<sup>2</sup>; mild mitral regurgitation. Rheumatic origin suspected for both valvular conditions. Pulmonary artery pressure estimated at 100 mmHg; left atrium measured 12 cm x 8.5 cm. Despite massive diuresis with loop diuretics, the patient's symptoms persisted. Discussions among cardiology, cardiovascular surgery, and anesthesiology concluded with a STS short-term operative mortality score of 16.4% and Euroscore of 20%. Surgery for mitral and aortic valves was considered but deemed unsuitable due to the patient's pulmonary edema, frailty, and high surgical risk. Initially, TAVI was chosen for aortic stenosis, with PMV planned subsequently in the same procedure. Due to severe aortic valve calcification, a 25 mm balloon pre-dilatation was performed. Subsequently, a 26 mm balloon-expandable valve was placed, but severe aortic regurgitation persisted despite two additional balloon dilations. Therefore, a new 30.5 mm balloon-expandable valve was inserted within the initial TAVI valve. Following successful valve-in-valve placement, mild aortic regurgitation remained. Mitral balloon valvuloplasty began with septostomy under transesophageal echocardiography guidance. Due to the patient's enlarged left atrium, the mitral balloon could not pass through the mitral valve due to length constraints. Access was achieved using an Agilis catheter, with the mitral valve traversed using an MPA catheter and bent wire into the left ventricle. Initially, a 12x40 mm peripheral balloon was used for mitral dilation, followed by successful passage of a 23x20 mm aortic balloon through the mitral valve for high-pressure pre-dilatation. After post-dilatation, mild-to-moderate mitral regurgitation was noted. The patient recovered well, with reduced pulmonary edema. Follow-up echocardiography showed a bioprosthetic aortic valve with gradients of 23 mmHg (max) and 11 mmHg (mean), minimal paravalvular aortic regurgitation, and a mitral valve area of 1.2 cm<sup>2</sup>. Mild mitral regurgitation persisted, while severe tricuspid regurgitation remained unchanged, and pulmonary hypertension decreased to 90 mmHg.

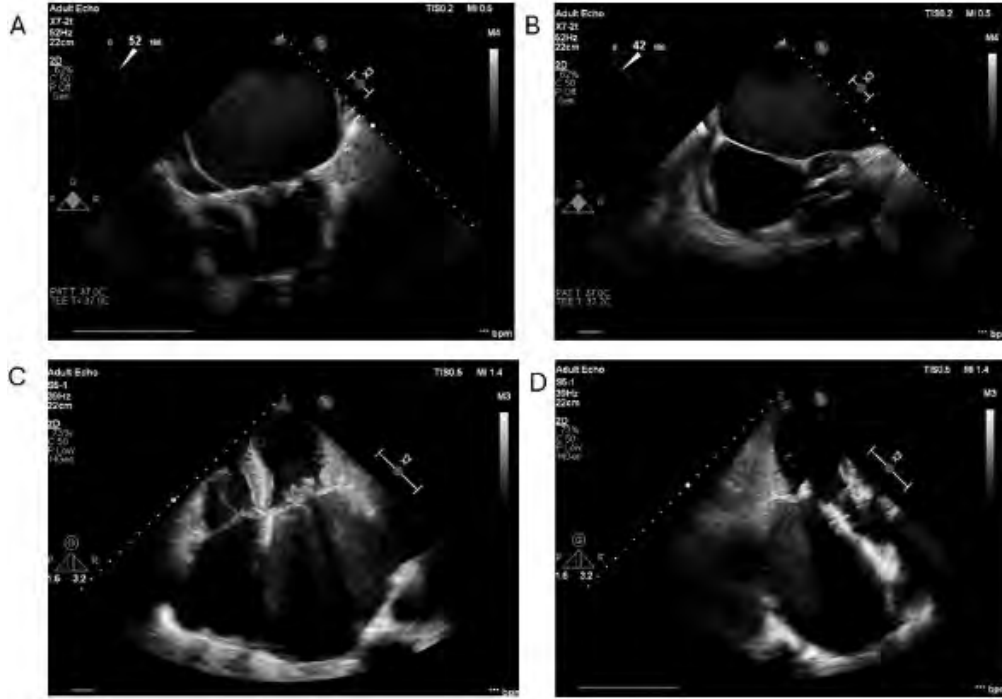
**Keywords:** aortic stenosis, mitral stenosis, tavi, pmv

# KARDİYOVASKÜLER AKADEMİ KONGRESİ

## & INTERNATIONAL ACADEMY OF YOUNG CARDIOLOGISTS

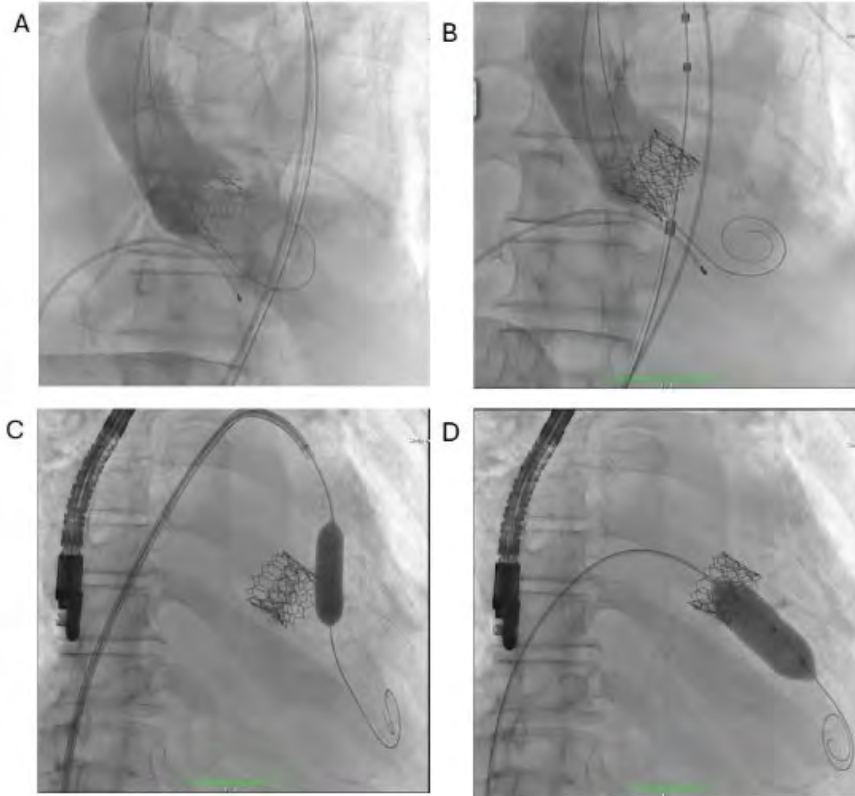
Elexus Hotel Girne, K.K.T.C.  
18-22 Eylül 2024

Figure 1



A: Transesophageal echocardiography provided images of mitral stenosis before PMV. B: Transesophageal echocardiography provided images of aortic stenosis before TAVI C: Transthoracic echocardiography image of the mitral valve post-PMV D: Transthoracic echocardiography image of the bioprosthetic aortic valve.

**Figure 2**



*A: Severe aortic regurgitation following the initial aortic valve implantation. B: Mild aortic regurgitation following successful valve-in-valve operation C: A 12x40 mm peripheral balloon was used to dilate the mitral valve. D: A 23x20 mm aortic balloon was used to dilate the mitral valve.*

**AuthorToEditor:** Multivalvular disease requires multidisciplinary assessment tailored to each patient's unique situation. Typically, a 67-year-old patient with both mitral and aortic stenosis would undergo surgery. In our case report, we opted for intervention on both valves following consultation with cardiovascular surgeons. Our plan for TAVI and PBM interventions is significant due to its rarity in simultaneous operations, offering valuable insights for managing TAVI complications. Mitral balloon valvuloplasty can be complex, especially in cases of enlarged left atrium. We addressed these challenges by utilizing specialized equipment available in our lab for mitral valve dilation. Our case report includes educational strategies for mitral balloon valvuloplasty, complemented by high-quality echocardiography and angiography images for presentation. We believe this intriguing and challenging case report will serve as a guide for our colleagues.





# KARDİYOVASKÜLER AKADEMİ KONGRESİ

## & INTERNATIONAL ACADEMY OF YOUNG CARDIOLOGISTS

Elexus Hotel Girne, K.K.T.C.  
18-22 Eylül 2024

### [OP-44] Primer LAD PCI Sırasında Koroner Arter Perforasyonu Gelişen Hastanın Yönetimi

Çisem Oktay, Mehmet Kış  
DOKUZ EYLÜL UNIVERSITY

#### Management of a Patient with Coronary Artery Perforation During Primary LAD PCI

Coronary artery perforation (CAP) is a rare complication during percutaneous coronary intervention with a mortality rate of 0.2-0.5%. CAP, one of the most feared complications, can cause pericardial effusion and tamponade, cardiogenic shock and mortality. The accumulation of effusion in coronary artery perforations often develops rapidly, often causes hypotension and can be followed by pericardiocentesis, and in rare cases, cardiac surgery may be required. We wanted to share a case of Ellis stage 3 CAP in a patient undergoing percutaneous coronary intervention for STEMI.

A 53-year-old male patient was admitted to the emergency department with compressive chest pain. Electrocardiography revealed ST segment elevation in anterior leads and reciprocal ST segment depressions and he was taken to the catheter laboratory with a diagnosis of anterior MI. In our patient, perforation occurred after the LAD total occluded lesion was crossed with a floppy guide-wire and balloon dilatation was performed. It was observed that the perforation had regressed in the control imaging after prolonged balloon inflation in the proximal area and waiting for cardiovascular surgery consultation.

After ballooning over the pilot 50 wire, which was delivered to the LAD as a second wire, it was seen that flow was achieved. Subsequently, stent implantation was performed in the LAD. Upon observation of thrombus in the LAD diagonal, rewiring was performed and TIMI 3 flow was achieved with the balloon. After 3 months of follow-up, the patient had angina and control angiography was performed. LAD TIMI 3 flow was observed and the stent was patent. Medical treatment was organized and the patient did not have any complaints during follow-up.

One of the most important complications of the PCI procedure is CAP. Surgery or graft stents are treatment options. However, while waiting for these interventions, prolonged balloon dilatation proximal to the perforation may be an option.

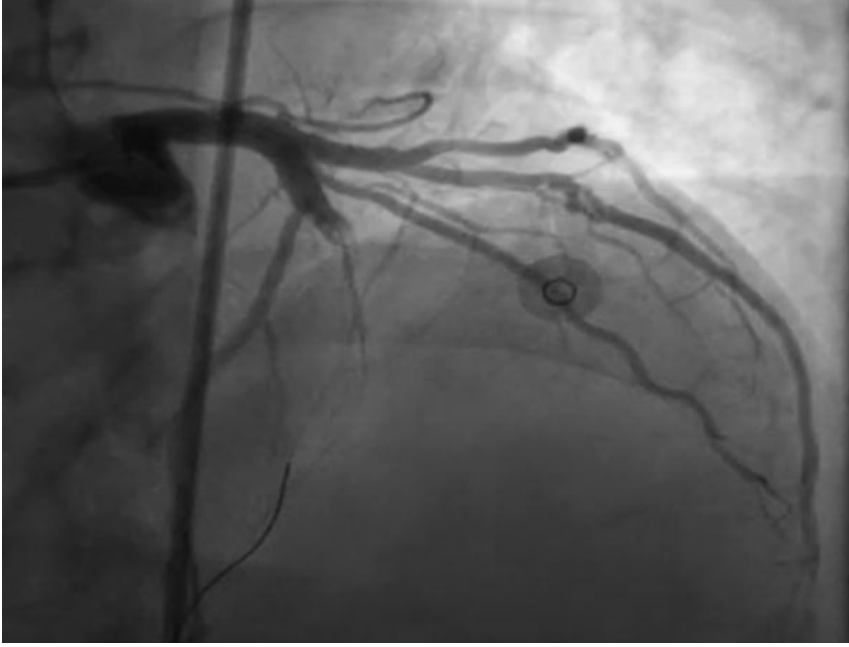
**Keywords:** Coronary artery perforation, anterior STEMI, balloon

# KARDİYOVASKÜLER AKADEMİ KONGRESİ

## & INTERNATIONAL ACADEMY OF YOUNG CARDIOLOGISTS

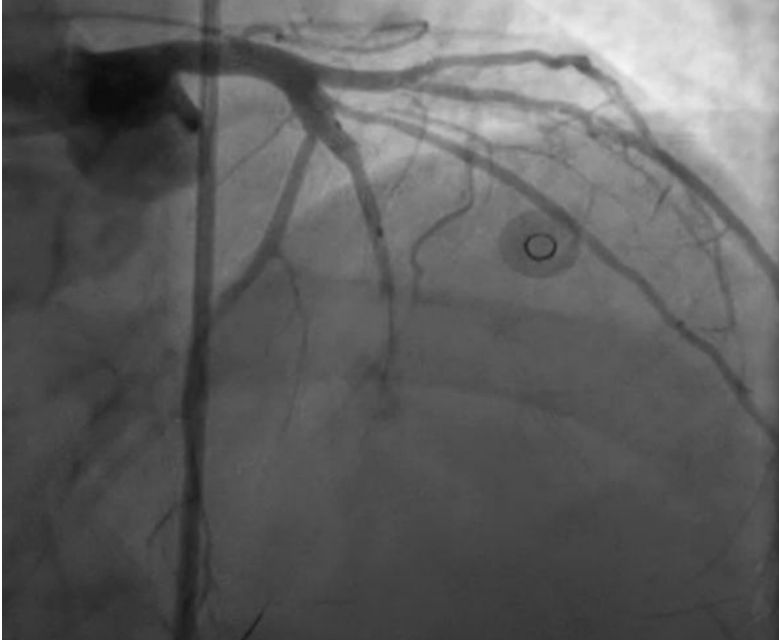Elexus Hotel Girne, K.K.T.C.  
18-22 Eylül 2024

Resim 1



*Lad total oklude lezyondan fgw ile geçildi*

Resim 2



*LAD septale yönelen tel üzerinden yapılan 2.0\*15 mm balon(14 atm) sonrasında Ellis evre 3 perforasyon izlendi*

**AuthorToEditor:** poster bildirisi yada sözlü sunum olabilir



# KARDİYOVASKÜLER AKADEMİ KONGRESİ

## & INTERNATIONAL ACADEMY OF YOUNG CARDIOLOGISTS

Elexus Hotel Girne, K.K.T.C.  
18-22 Eylül 2024

### **[OP-45] Successful Treatment of Coronary Perforation Following Percutaneous Intervention Due to STEMI Caused by Early LIMA-LAD Anastomotic Stenosis: A Case Report**

Berk Mutlu, Mustafa Umut Somuncu

*Aydın Adnan Menderes Üniversitesi, Kardiyoloji Ana Bilim Dalı, Aydın*

A 68-year-old female presented to the cardiology clinic for preoperative evaluation, showing normal functional capacity but class I angina. Her ECG and ECHO was normal. Due to symptom positivity and deep ST depressions on a preoperative stress test, angiography was performed, revealing approximately 90% stenosis in the LAD, with no significant stenosis in other coronary arteries. Given the osteal nature of the LAD lesion, significant diameter difference with the main coronary artery, and risk of shifting to CX and IM arteries, the cardiology-cardiovascular council recommended a LIMA-LAD bypass operation. Eight hours postoperatively, the patient experienced chest pain, leading to ventricular tachycardia and fibrillation. Despite defibrillation and medication, malignant arrhythmias persisted. The patient's ECG showed new ST elevations in V3-V6 leads. Due to hemodynamic instability and inotropic needs, coronary angiography was performed, revealing a 95% thrombotic lesion at the LIMA-LAD graft anastomosis site and TIMI I flow in the distal LAD. Decision was made to stent the LIMA-LAD graft.

The LIMA lesion was crossed with a floppy wire, and predilatation was performed with a 2.0x20 mm balloon at 10 ATM. A 2.75x21 mm DES then implanted at 12 ATM. Post-implantation imaging revealed significant extravasation of contrast, indicating an Ellis type 3 coronary perforation. The presence of a postoperative drain prevented progression to tamponade. Then 2.5x20 mm PK Papyrus Graft stent was implanted. Control imaging confirmed cessation of perforation and TIMI 3 flow restoration. There are several points to discuss in our case. There is no definitive evidence-based information in the guidelines for these situations. LAD osteal lesions can now be treated percutaneously with newly developed stenting techniques, and the question of which patients should be treated surgically and which percutaneously should be discussed. LIMA-LAD graft stenosis rates are the lowest among bypass grafts, with early stenosis being very rare in the first 3 months and case reports available in the literature. In our case, restenosis occurred 8 hours postoperatively, and early angiography and intervention were effective in preventing mortality. Redo surgery and percutaneous treatment of early graft occlusions after bypass are also controversial, with studies in the literature indicating higher mortality for redo surgery. In our case, stenting was performed 10 hours post-bypass, and the stent placed in the anastomosis area resulted in perforation. Contrary to known causes of perforation, in our case, the reason for perforation was thought to be the new anastomosis. The biggest advantage for the patient and our team was the presence of drains, preventing progression to tamponade. The treatment and management of early ACS in the post-bypass period should be considered and decided on a patient-by-patient basis, and case reports on this subject could guide treatments.

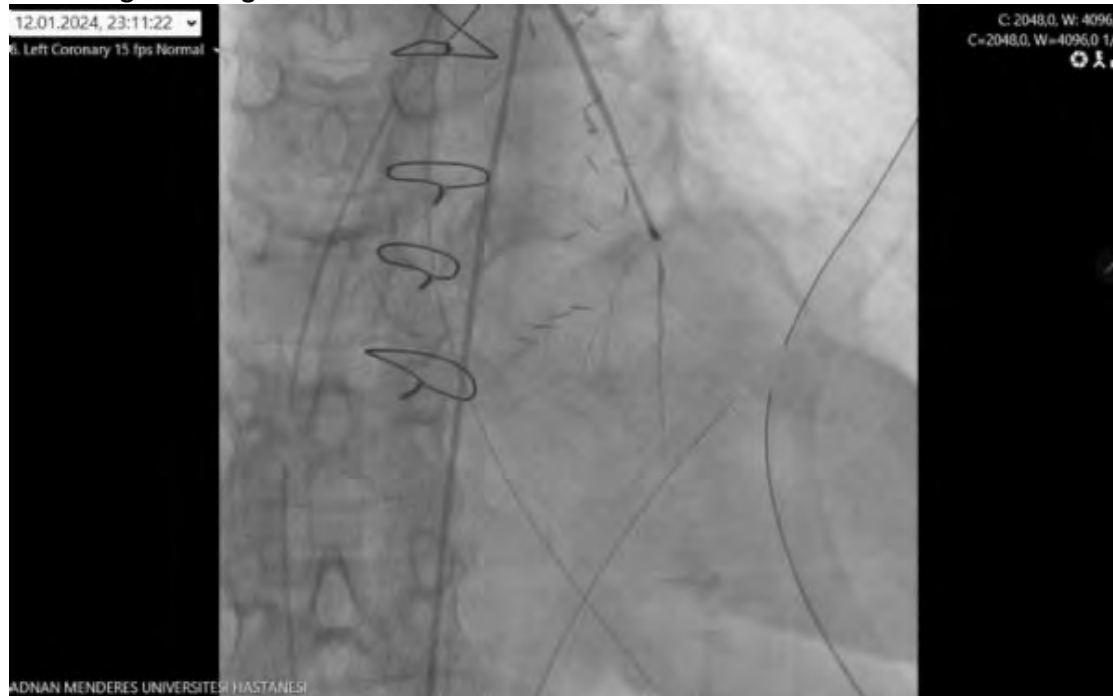**Keywords:** LIMA-LAD, ANASTOMOSIS, PERFORATION

# KARDİYOVASKÜLER AKADEMİ KONGRESİ

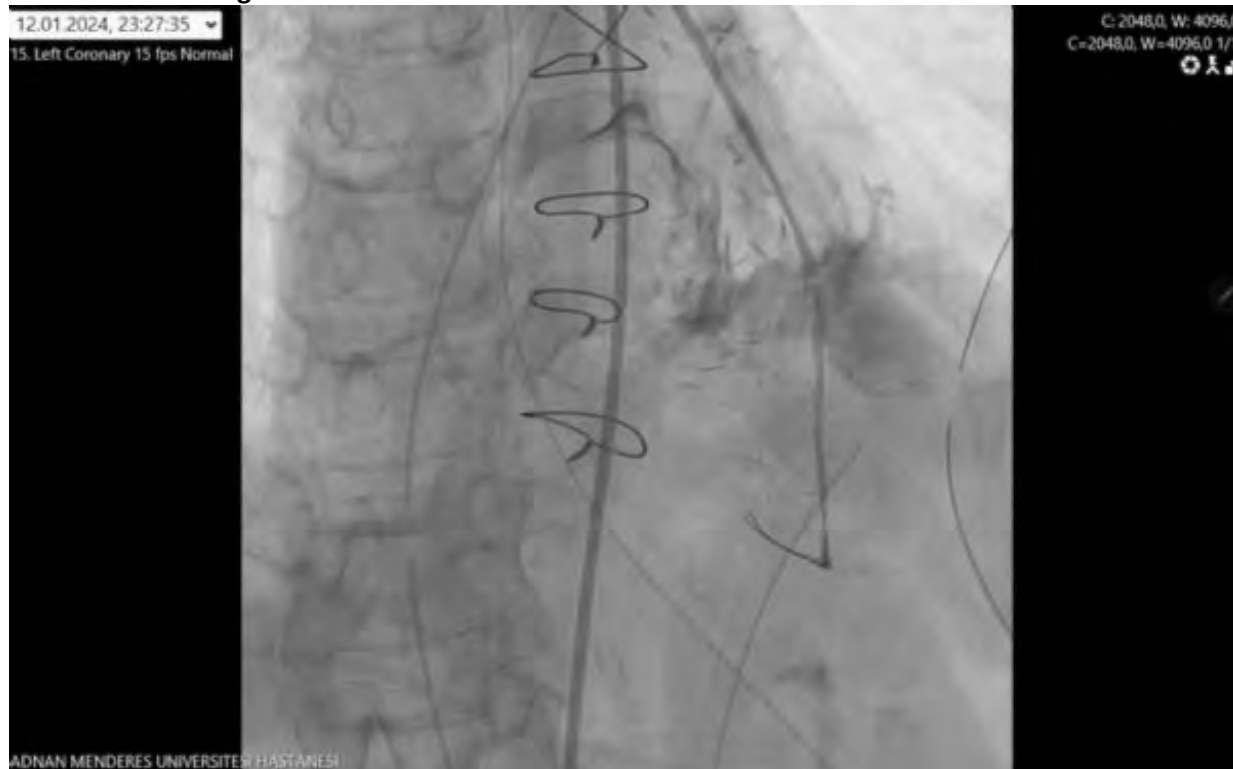## & INTERNATIONAL ACADEMY OF YOUNG CARDIOLOGISTS

Elexus Hotel Girne, K.K.T.C.  
18-22 Eylül 2024

After cabg first image of LIMA LAD Anastomosis



PERFORATION image







# KARDİYOVASKÜLER AKADEMİ KONGRESİ

## & INTERNATIONAL ACADEMY OF YOUNG CARDIOLOGISTS

Elexus Hotel Girne, K.K.T.C.  
18-22 Eylül 2024

### [OP-46] The relationship between wrist circumferences and coronary artery diameters

Çağlar Alp, Rukiye Gönen Özdemir, Mehmet Tolga Doğru  
*kırıkkale tıp fakültesi*

**Objective:** Coronary artery diameters are crucial in determining the stent size to be used during acute coronary syndromes. Especially in cases of ostial lesions where there is no other reference vessel, it becomes challenging. The aim of our study is to investigate the correlation between coronary artery diameters and anthropometric measurements in patients without normal coronary artery structure (obstructive or ectatic coronary artery disease).

**Materials-Methods:** This retrospective study included 102 patients who underwent coronary angiography and did not show any signs of plaque or ectasia angiographically. Patients were divided into three groups based on their wrist circumference. The clinical and angiographic images of the patients were evaluated from the hospital automation system.

**Results:** A statistically significant difference was observed among the wrist circumference groups. Positive correlations were found between wrist circumference measurements and the diameters of the left main coronary artery, circumflex artery, and left anterior descending artery. The correlation coefficients were  $r: 0.390$ ,  $p < 0.001$  for the left main coronary artery,  $r: 0.244$ ,  $p = 0.013$  for the left anterior descending artery,  $r: 0.303$ ,  $p = 0.002$  for the circumflex artery, and  $r: 0.223$ ,  $p = 0.024$  for the right main coronary artery (Spearman,  $p < 0.05$ ). According to the results obtained in our study, 80% of patients with a wrist circumference above 15.5 have a left main coronary artery diameter of above 4.0 cm.

**Conclusion:** In this study, a statistically significant positive correlation was found especially between wrist circumference and the diameter of the left main coronary artery (LMCA). This positive correlation could be an important feature in determining the stent size to be used in LMCA ostial lesions where intravascular ultrasound (IVUS) cannot be used. With more comprehensive studies, a formulation between wrist circumference and LMCA diameter can be obtained.

**Keywords:** angiography, coronary artery diameters, wrist circumference



# KARDİYOVASKÜLER AKADEMİ KONGRESİ

## & INTERNATIONAL ACADEMY OF YOUNG CARDIOLOGISTS

Elexus Hotel Girne, K.K.T.C.  
18-22 Eylül 2024

### [OP-47] Value of ACEF Score in Predicting Postoperative Atrial Fibrillation

Atilla Koyuncu<sup>1</sup>, Ersan Oflar<sup>2</sup>

<sup>1</sup>Atilla Koyuncu, Bakırköy Dr Sadi Konuk Training and Research Hospital

<sup>2</sup>Ersan Oflar, Bakırköy Dr Sadi Konuk Training and Research Hospital

**Introduction:** Postoperative atrial fibrillation (POAF) is the most common complication after cardiac surgery, with a rate of 20-40 percent. The development of POAF is associated with longer hospital stays, worse clinical adverse events, and recurrent atrial fibrillation. The value of the Age, Creatinine, and Ejection Fraction (ACEF) score was first demonstrated in patients undergoing coronary artery bypass graft surgery. The present study was conducted to evaluate the predictive value of ACEF score for POAF.

**Material and methods:** Two hundred and eighty-seven patients undergoing coronary artery bypass graft surgery between 2020 and 2022 were included in the study. POAF was defined as new-onset atrial fibrillation that developed during hospitalization. Patients were divided into two groups according to the development of POAF.

**Results:** The mean age of the study population was 59.70±9.78 years. Patients who developed POAF were older, had higher ACEF scores and were less likely to have hyperlipidemia. ROC curve analysis showed that ACEF value of 1.10 had 76.9% sensitivity and 46.6% specificity for the prediction of POAF (AUC:0.651, p=0.001, 95%CI:0.570-0.732) (Figure 1). The results of logistic regression analysis showed that compared with age (OR: 1.057, p=0.001, 95% CI: 1.024-1.091), ACEF score had a higher OR (OR: 6.973, p<0.001, 95% CI: 2.592-18.762).

**Discussion:** Our results showed that ACEF score was an independent predictor of POAF. Compared with age, LVEF and creatinine, it had a better value for predicting POAF.

The pathophysiology of POAF is complex. Cardiovascular risk factors and comorbidities increase the risk of POAF. In addition, myocardial injury, right atriotomy, direct injury to the atrial myocardium, inflammation, myocardial ischemia, and ischemia-reperfusion injury, sympathetic activation are some of the proposed mechanisms associated with the occurrence of surgery associated POAF. The occurrence of POAF is important because, although it is usually a self-limiting event, it has been shown to be associated with both short- and long-term adverse cardiac events. In several studies higher values of ACEF score was associated with an increased risk of atrial fibrillation patients after radiofrequency ablation. Our results showed that ACEF score was an independent predictor for the development of POAF. Large-scale studies are needed to better delineate the value of the ACEF score in surgery-associated atrial fibrillation.

**Keywords:** Atrial Fibrillation, ACEF score, Cardiac Surgery

# KARDİYOVASKÜLER AKADEMİ KONGRESİ & INTERNATIONAL ACADEMY OF YOUNG CARDIOLOGISTS

Elexus Hotel Gıme, K.K.T.C.  
18-22 Eylül 2024

FIGURE 1

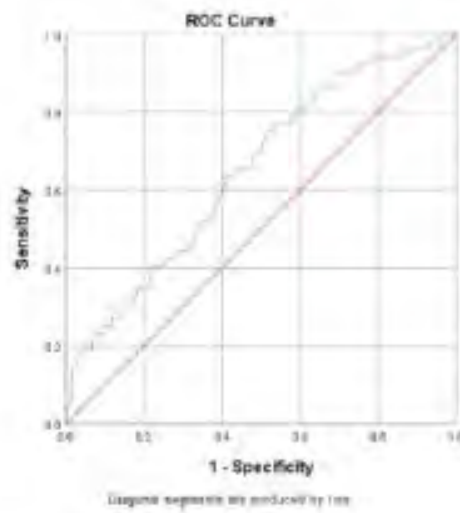


Figure 1: ROC curve for ACEF score in the prediction of POAF.



# KARDİYOVASKÜLER AKADEMİ KONGRESİ

## & INTERNATIONAL ACADEMY OF YOUNG CARDIOLOGISTS

Elexus Hotel Girne, K.K.T.C.  
18-22 Eylül 2024

**table 1**

	POAF (-) n=235	POAF (+) n= 52	p
Age (years)	58.75±9.74	63.94±8.89	<0.001
Gender (n,%)			
Female	51 (21.7)	17 (32.7)	
Male	184 (78.3)	35 (67.3)	
COPD (n,%)	46 (19.6)	13 (25)	0.390
DM (n,%)	90 (38.3)	18 (34.6)	0.620
HL (n,%)	129 (54.9)	19 (36.5)	0.017
Family history of CAD (n,%)	95 (40.4)	15 (28.8)	0.120
LVEF (%)	52.31±7.83	49.63±8.63	0.050
Hgb (g/dl)	12.50±1.62	12.04±1.43	0.050
TSH (mIU/l)	1.78±1.70	2.27±2.54	0.248
Albumin (mg/dl)	4.20±0.38	4.18±0.37	0.889
CRP (mg/dl)	12.45±16.76	14.35±24.77	0.664
HgA1c (%)	6.76±1.99	6.60±1.52	0.939
Creatinine (mg/dl)	0.90±0.34	0.93±0.30	0.326
ICU stay (day)	3.47±28	3.58±2.68	0.780
ACEF score	1.15±0.26	1.34±0.37	0.001

*Table 1: Clinical and biochemical characteristics of two groups.*





# KARDİYOVASKÜLER AKADEMİ KONGRESİ

## & INTERNATIONAL ACADEMY OF YOUNG CARDIOLOGISTS

Elexus Hotel Girne, K.K.T.C.  
18-22 Eylül 2024

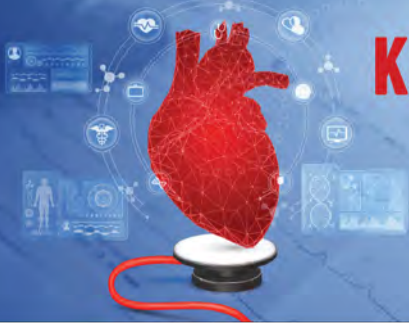### **[OP-48] p.R220L is a Pathogenic Novel GLA Gene Mutation Responsible for a Cardiac Phenotype of Fabry Disease**

İpek Aydın

*Istanbul University Institute of Cardiology*

A 54-year-old male patient had been followed for 16 years due to hypertrophic cardiomyopathy. He was admitted to our clinic with increased exertional dyspnea for the last two months. The patient's medical history was notable for longstanding hypertrophic cardiomyopathy. He admitted to the hospital with complaints of chest pain and shortness of breath over a period of 7 years and undergoing coronary angiography three times with a pre-diagnosis of non-ST-segment elevation myocardial infarction. All three coronary angiography were found to be normal. The patient eventually visited our clinic. The physical examination revealed nothing remarkable; the patient's blood pressure was 126/74 mm Hg, pulse was rhythmic with 82 beats/min, respiratory rate was 18 breaths/min and oxygen saturation was 99% on ambient air. Blood testing was notable for a creatinine of 1.48 mg/dl. N-terminal pro-B-type natriuretic peptide and high-sensitive cardiac troponin levels elevated to 1240 pg/ml (normal range 0 to 157 pg/ml) and 0.129 ng/mL (normal range <0.014). Results of hemoglobin, hemoglobin A1C, hepatobiliary panel, lipid panel, and thyroid function studies were normal. The electrocardiogram (ECG) demonstrated left ventricular hypertrophy. Transthoracic echocardiography showed normal left ventricular ejection fraction of 60%, left ventricular end-diastolic diameter of 4.6 cm, concentric hypertrophy involving particularly the mid and apical portions of the left ventricle, as well as right ventricular free wall along with thickening of the mitral and aortic valves resulting in mild valvular regurgitation. In the apical 4-chamber view, the hyperechogenic endocardium and the hypoechogenic thin border between the myocardium and the endocardium in the interventricular septum is defined as the "binary sign". Cardiac magnetic resonance imaging (MRI) and genetic testing were planned in order to elucidate the unexplained left ventricular hypertrophy. The common gene panel in patients with hypertrophic cardiomyopathy was screened. In genetic analysis NM\_000169.2:c.659G>T (p.R220L) (p.Arg220Leu) mutation was detected in GLA gene. Since this mutation was not previously identified, it was evaluated as a mutation of uncertain clinical significance. Therefore,  $\alpha$ -galactosidase A ( $\alpha$ -GLA) enzyme level and plasma globotriaosylsphingosine (Lyso-gb3) level were measured with the pre-diagnosis of Fabry disease. We found that  $\alpha$ -GLA enzyme level of 2.50 nmol / mg / h (normal range > 23.10) was significantly low and Lyso-gb3 10.40 ng / mL (normal range <1.30) levels were high. Cardiac MRI showed left ventricular hypertrophy; vertical long axis, and midventricular short-axis late gadolinium-enhanced images demonstrated extensive anterior and inferolateral wall segment enhancement. Horizontal long axis pre-contrast T1 map: The region of interest measured at the inferolateral wall shows reduced T1 value. Enzyme replacement therapy was initiated after being evaluated at the Fabry disease council.

**Keywords:** fabry disease, hypertrophic cardiomyopathy, imaging



# KARDİYOVASKÜLER AKADEMİ KONGRESİ

## & INTERNATIONAL ACADEMY OF YOUNG CARDIOLOGISTS

Elexus Hotel Girne, K.K.T.C.  
18-22 Eylül 2024

### [OP-49] Systemic Immune-Inflammatory Index as a Predictor of Long-Term Mortality in Patients with Permanent Pacemakers

Levent Pay<sup>1</sup>, Mert Ilker Hayiroğlu<sup>2</sup>, Tufan Çinar<sup>3</sup>, Gökse Çinier<sup>4</sup>, Gizem Yüksel<sup>5</sup>, Kıvanç Keskin<sup>2</sup>, Cahit Coşkun<sup>2</sup>, Gökçem Ayan<sup>2</sup>, Vedat Çiçek<sup>6</sup>, Ahmet Çağdaş Yumurtaş<sup>7</sup>, Ahmet Ilker Tekkeşin<sup>4</sup>

<sup>1</sup>Department of Cardiology, Istanbul Haseki Training and Research Hospital, Istanbul, Turkey

<sup>2</sup>Department of Cardiology, Dr Siyami Ersek Thoracic and Cardiovascular Surgery Training Hospital, Istanbul, Turkey

<sup>3</sup>Department of Medicine, University of Maryland Medical Center Midtown Campus, Maryland, USA

<sup>4</sup>Department of Cardiology, Cam and Sakura City Hospital, Istanbul, Turkey

<sup>5</sup>Department of Cardiology, Istanbul Training and Research Hospital, Istanbul, Turkey

<sup>6</sup>Department of Cardiology, Sultan 2. Abdulhamid Han Educational and Research Hospital, Turkey

<sup>7</sup>Department of Cardiology, Harakani State Hospital, Kars, Turkey

**Background:** The Systemic Immune-Inflammatory Index (SII), calculated from neutrophil, platelet, and lymphocyte counts, reflects the equilibrium among inflammatory, immune, and thrombotic states. Initially employed in 2014 to predict the prognosis of hepatocellular carcinoma, SII has since been utilized to predict outcomes in various cardiovascular diseases. However comprehensive connection between patients with permanent pacemakers and SII has not been extensively studied. Hence in this study, we aimed to examine the prognostic benefit of Systemic Immune-Inflammatory index in terms of long-term all-cause mortality in patients with permanent pacemaker implantation.

**Methods:** 1282 patients who underwent permanent pacemaker implantation were included in this study and were divided into two groups according to the presence of long-term mortality. SII scores for patients were calculated as: platelet count x neutrophil count/ lymphocyte count. The relationship between these groups and SII scores were assessed.

**Results:** There were 196 patients in the long-term mortality (+) group and 1086 patients in the long-term mortality (-). The group with long-term mortality was comprised of older individuals (69 (60 – 76) vs. 76 (69 – 81);  $p < 0.001$ ). Patients with long-term mortality were more likely to have a history of chronic renal failure (145 (13.4) vs. 59 (30.1);  $p < 0.001$ ), coronary artery disease (293 (27.0) vs. 75 (38.3);  $p = 0.001$ ), and coronary artery bypass grafting (101 (9.3) vs. 36 (18.4);  $p < 0.001$ ). Patients with long-term mortality had higher neutrophil counts (7.3 (6.1 – 8.9) vs. 7.9 (6.4 – 9.5);  $p = 0.001$ ) and lower albumin (3.9 (3.8 – 4.1) vs. 3.8 (3.6 – 4.0);  $p < 0.001$ ) and lymphocyte levels (1.9 (1.5 – 2.4) vs. 1.7 (1.2 – 2.0);  $p < 0.001$ ). Finally, patients with long-term mortality exhibited higher SII values (711 (501 – 1024) vs. 896 (634 – 1479);  $p < 0.001$ ). Table 1 shows comparison of demographic and clinical characteristics of patients according to long-term mortality after pacemaker implantation. Receiver operating characteristic (ROC) analysis indicated that an SII cut-off level of 816 or higher predicted long-term mortality with 60% sensitivity and 60% specificity (Figure 1).

**Conclusion:** Systemic Immune-Inflammatory index at the time of device implantation has prognostic value in the evaluation of long-term mortality in patients with permanent pacemakers. SII could potentially be used as a screening tool to identify patients with permanent pacemakers who are at increased risk of adverse outcomes.

**Keywords:** Systemic Immune-Inflammatory index, pacemaker, prognosis, long-term mortality

# KARDİYOVASKÜLER AKADEMİ KONGRESİ

## & INTERNATIONAL ACADEMY OF YOUNG CARDIOLOGISTS

Elexus Hotel Girne, K.K.T.C.  
18-22 Eylül 2024

Figure 1

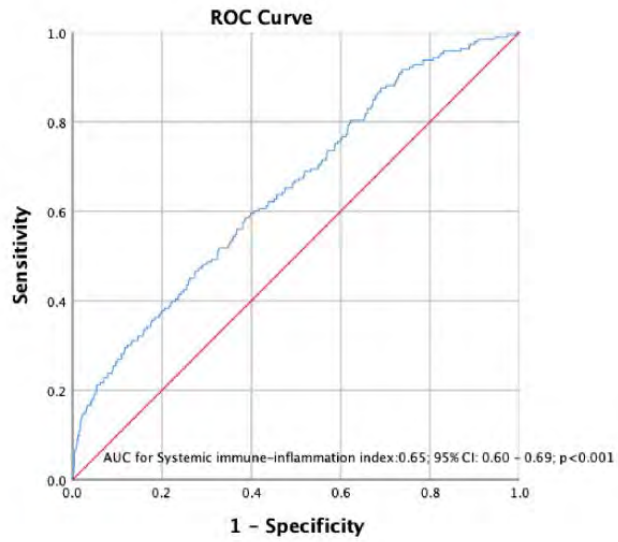


Figure 1: ROC curve analysis of Systemic Immune-Inflammatory index to predict long-term mortality.

# KARDİYOVASKÜLER AKADEMİ KONGRESİ

## & INTERNATIONAL ACADEMY OF YOUNG CARDIOLOGISTS

Elexus Hotel Girne, K.K.T.C.  
18-22 Eylül 2024

**Table 1**

	Long term mortality (-) n=1086	Long term mortality (+) N=196	P value
Age, y	69 (60 – 76)	76 (69 – 81)	<0.001
Male gender	535 (49.3)	116 (59.2)	0.011
Hypertension	697 (64.2)	135 (68.9)	0.205
Diabetes Mellitus	288 (27.4)	73 (37.2)	0.005
Hyperlipidemia	412 (37.9)	69 (35.2)	0.467
Smoking	268 (24.8)	49 (25.0)	0.951
Chronic renal failure	145 (13.4)	59 (30.1)	<0.001
Chronic obstructive pulmonary disease	85 (7.8)	20 (10.2)	0.277
Cerebrovascular accident	44 (4.1)	6 (3.1)	0.487
Coronary artery disease	293 (27.0)	75 (38.3)	0.001
Percutaneous coronary intervention	120 (11.0)	31 (15.8)	0.057
Coronary artery bypass grafting	101 (9.3)	36 (18.4)	<0.001
Laboratory variables at implantation			
Hb (g/dl)	12.7 (11.7 – 13.9)	12.5 (11.9 – 13.7)	0.546
Neutrophils (cells/ $\mu$ L)	7.3 (6.1 – 8.9)	7.9 (6.4 – 9.5)	0.001
Platelet count (/mm <sup>3</sup> )	194 (155 – 243)	205 (159 – 258)	0.016
Lymphocytes	1.9 (1.5 – 2.4)	1.7 (1.2 – 2.0)	<0.001
SII	711 (501 – 1024)	899 (634 – 1479)	<0.001
Urea	18 (15 – 23)	20 (13 – 28)	0.231
Creatinine (mg/dL)	1.0 (0.8 – 1.2)	1.0 (0.8 – 1.2)	0.563
TSH	1.3 (0.8 – 2.2)	1.2 (0.8 – 2.2)	0.478
Glucose (mg/dl)	102 (92 – 122)	106 (92 – 132)	0.267
Sodium	140 (138 – 142)	139 (137 – 141)	0.212
Potassium	4.4 (4.1 – 4.7)	4.4 (4.3 – 4.7)	0.195
Calcium (corrected)	9.2 (8.8 – 9.5)	9.1 (8.7 – 9.6)	0.473
Magnesium	2.0 (1.8 – 2.1)	2.0 (1.9 – 2.2)	0.244
Albumin	3.9 (3.8 – 4.1)	3.8 (3.6 – 4.0)	<0.001
Echocardiography variables at implantation			
Ejection fraction, %	62 (60 – 62)	62 (52 – 63)	<0.001
LAAP, mm	38 (35 – 42)	40 (37 – 45)	<0.001
Follow-up, months	64 (29 – 100)	37 (12 – 64)	

**Table 1:** Comparison of demographic and clinical characteristics of patients according to long term mortality after pacemaker implantation

Continuous variables are presented as median (interquartile range)  
Nominal variables presented as frequency (%)

*Table 1: Comparison of demographic and clinical characteristics of patients according to long-term mortality after pacemaker implantation*





# KARDİYOVASKÜLER AKADEMİ KONGRESİ

## & INTERNATIONAL ACADEMY OF YOUNG CARDIOLOGISTS

Elexus Hotel Girne. K.K.T.C.  
18-22 Eylül 2024

### **[OP-50] Exercise Sensitivity, Physical Activity and Kinesiophobia in Patients with Chronic Coronary Syndrome: A Cross Sectional Study**

İrem Huzmeli<sup>1</sup>, Oğuz Akkuş<sup>2</sup>, Nihan Katayıfçı<sup>1</sup>, İsmail Kara<sup>1</sup>, Ramazan Yasdıbaş<sup>2</sup>

<sup>1</sup>Mustafa Kemal University, Health Science Faculty, Antakya, Türkiye

<sup>2</sup>Mustafa Kemal University, Faculty of Medicine, Department of Cardiology, Antakya, Türkiye

**Background:** Exercise sensitivity, kinesiophobia and physical activity levels should be determined to effectively manage exercise-based treatment programs in patients with chronic coronary syndrome (CCS).

**Aim:** Compare exercise sensitivity, kinesiophobia and physical activity levels of CCS and healthy individuals.

**Methods:** 43 patients diagnosed with CCS and 45 healthy individuals were included in this cross-sectional study. Exercise sensitivity, physical activity levels (using the Short Form Physical Activity Questionnaire, using IPAQ) and kinesiophobia (using the Tampa Kinesiophobia Scale, Heart, using TSK-H) were assessed in both groups.

**Results:** Patients mostly disagreed with the idea that feeling pain ( $p=0.001$ ), energy depletion ( $p=0.033$ ) and fatigue ( $p=0.007$ ) during exercise would scare them. Patients frequently emphasized that chest pain ( $p=0.021$ ), feeling of tightness in the chest ( $p=0.037$ ) dizziness ( $p=0.046$ ) palpitations ( $p=0.001$ ) shortness of breath ( $p=0.008$ ), fainting ( $p=0.001$ ) would frightened them during exercise. All participants agreed that blurred vision that may occur during exercise frightened them ( $p = 0.084$ ). TSK-H was higher in CCS compared to healthy controls and the difference was statistically significant ( $p = 0.007$ ). The percentage of high kinesiophobia (58.1% in CCS and 40% in healthy) was similar between groups ( $p=0.068$ ) The physical activity level of the patients was lower than healthy controls ( $p<0.001$ ) and 58.1% were inactive Exercise sensitivity score was significantly correlated with IPAQ score ( $r = -0.360$ ;  $P = 0.018$ ) and TKS-H score ( $r = 0.529$ ;  $P < 0.001$ ) in CCS patients. According to linear regression analyses, exercise sensitivity explains 25% of kinesiophobia and physical activity.

**Conclusion:** The findings of this study have significant implications for the management of CCS. Patients with CCS may exhibit fear and sensitivity to exercise, particularly in relation to potential symptoms such as blurred vision, chest pain, chest tightness, dizziness, palpitations, shortness of breath, and fainting. These fears can contribute to high levels of kinesiophobia and low levels of physical activity. Understanding and addressing exercise sensitivity, kinesiophobia, and physical activity levels can help design effective therapeutic programs and increase patient participation in exercise regimens.

**Keywords:** Exercise sensitivity, physical activity, kinesiophobia, cardiovascular rehabilitation



# KARDİYOVASKÜLER AKADEMİ KONGRESİ

## & INTERNATIONAL ACADEMY OF YOUNG CARDIOLOGISTS

Elexus Hotel Girne, K.K.T.C.  
18-22 Eylül 2024

### Exercise Sensitivity Items and Results Between Patients and Healthy Participants

	Healthy Group n:45 N(%)	CCS Group n:43 N(%)	p
1. I get scared if I feel pain in my body during exercise			
Strongly disagree	13(28.9)	18(41.9)	0.00 1
Disagree	8(17.8)	20(46.5)	
Neutral	4(8.9)	2(4.7)	
Agree	10(22.2)	2(4.7)	
Strongly agree	10(22.2)	1(2.3)	
2. It scares me if I feel like I don't have much energy during exercise			
Strongly disagree	13(28.9)	9(20.9)	0.03 3
Disagree	12(26.7)	25(58.1)	
Neutral	7(15.6)	4(9.3)	
Agree	7(15.6)	4(9.3)	
Strongly agree	6(13.3)	1(2.3)	
3. The feeling of fatigue that may occur during exercise scares me			
Strongly disagree	15(33.3)	6(14)	0.00 7
Disagree	13(28.9)	29(67.4)	
Neutral	6(13.3)	4(9.3)	
Agree	6(13.3)	3(7)	
Strongly agree	5(11.1)	1(2.3)	
4. The blurred vision that may occur during exercise scares me			
Strongly disagree	0(0)	1(2.3)	0.08 4
Disagree	1(2.2)	0(0)	
Neutral	6(13.3)	7(16.3)	
Agree	20(44.4)	28(65.1)	
Strongly agree	18(40)	7(16.3)	
5. If I experience chest pain or feeling of tightness during exercise, this worries me			
Strongly disagree	0(0)	1(2.3)	0.02 4
Disagree	0(0)	5(11.6)	
Neutral	5(11.1)	1(2.3)	
Agree	18(40)	23(53.5)	
Strongly agree	22(48.9)	13(30.2)	
6. It would scare me if I felt tingling or numbness during			0.03



# KARDİYOVASKÜLER AKADEMİ KONGRESİ

## & INTERNATIONAL ACADEMY OF YOUNG CARDIOLOGISTS

Elexus Hotel Girne, K.K.T.C.  
18-22 Eylül 2024

exercise	1(2.2) 0(0)	0(0) 3(7)	7
Strongly disagree	10(22.2)	8(18.6)	
Disagree	18(40)	26(60.5)	
Neutral	16(35.6)	6(14)	
Agree			
Strongly agree			
7. I'd be worried if I felt dizzy during exercise			
Disagree	3(6.7)	2(4.7)	0.04
Neutral	3(6.7)	2(4.7)	6
Agree	17(37.8)	29(67.4)	
Strongly agree	22(48.9)	10(23.3)	
8. I would be scared if my heart rate increased or I had palpitations during exercise			
Strongly disagree	2(4.4)	0(0)	0.00
Disagree	8(17.8)	4(9.3)	1
Neutral	9(20)	4(9.3)	
Agree	7(15.6)	27(62.8)	
Strongly agree	19(42.2)	8(18.6)	
9. Having shortness of breath during exercise concerns me			
Strongly disagree	0(0)	1(2.3)	0.00
Disagree	3(6.7)	7(16.3)	8
Neutral	6(13.3)	1(2.3)	
Agree	16(35.6)	26(60.5)	
Strongly agree	20(44.4)	8(18.6)	
10. I get scared if I feel faint during exercise			
Strongly disagree	0(0)	1(2.3)	0.00
Disagree	0(0)	2(4.7)	1
Neutral	2(4.4)	1(2.3)	
Agree	12(26.7)	28(65.1)	
Strongly agree	31(68.9)	11(25.6)	

CCS: Chronic coronary syndrome,  $p < 0.05$



# KARDİYOVASKÜLER AKADEMİ KONGRESİ

## & INTERNATIONAL ACADEMY OF YOUNG CARDIOLOGISTS

Elexus Hotel Girne. K.K.T.C.  
18-22 Eylül 2024

### [OP-51] Cardiac magnetic resonance evaluation of myocardial fibrosis in type 2 diabetes mellitus patients with preserved left ventricular systolic function and its correlation with HbA1c level and diabetes duration

Sibel Catalkaya<sup>1</sup>, Ayşe Füsün Bekircavuşoğlu<sup>2</sup>, Ahmet Yıldırım<sup>1</sup>, Can Özkan<sup>1</sup>, Selvi Öztas<sup>1</sup>

<sup>1</sup>Bursa City Hospital Department of Cardiology

<sup>2</sup>Bursa City Hospital Department of Radiology

**Objectives:** The purpose of this study was to investigate the prevalence of myocardial fibrosis in patients with type 2 diabetes mellitus (T2DM) with preserved left ventricular systolic function using cardiac magnetic resonance (CMR) T1 mapping and evaluate its association with diabetes duration and HbA1c level.

**Methods:** A total of 19 subjects (11 women, mean age  $55 \pm 9$  years) with type 2 diabetes mellitus (8 short term  $< 5$  years and 11 long term  $> 5$  years) and preserved systolic LV-function who underwent pre- and post-contrast T1 mapping and late gadolinium enhancement (LGE) imaging were retrospectively analyzed. Patients with structural heart disease, history of coronary artery disease and chronic kidney disease were excluded. Image interpretation was performed using post-processing software (syngo.via, Siemens Healthineers, Erlangen, Germany). For each patient LV chamber and function quantification as well as T1 mapping parameters and ECVs were determined based on the 16-segment model of the American Heart Association. T1 mapping and ECV parameters were compared between short- and long-term diabetes patients as well as patients with well controlled ( $HbA1c < 7,5g/dl$ ) and those with poorly-controlled diabetes ( $HbA1c > 7,5g/dl$ ).

**Results:** Clinical characteristics of the patients are shown in Table 1. The average native T1 value for the entire study group was  $1027,6 + 28,6$  (Ref.  $930 + 21$ ) and overall ECV value was  $26,9 + 3,3$  (Ref.  $25,3 + 3,5$ ). Segmental analysis showed a tendency for increasing values from basal to apical for native T1 (mean basal  $1019,1 + 40,8$ , mid  $1023,1 + 56,7$ , apical  $1046,8 + 58,3$ ) however no considerable regional differences for ECV (mean basal  $27,1 + 3,9$ , mid  $26,3 + 4,3$  apikal  $27,3 + 4,9$ ). Correlation analyses of T1 and ECV values of each LV segment according to diabetes duration and HbA1c are illustrated in Table 2; segmental analysis showed no statistically significant correlation of native T1- and post-contrast ECV values with both diabetes duration and HbA1c level.

**Conclusions:** T1 mapping cardiac MRI can detect diffuse fibrosis in type 2 diabetes mellitus patients. Our results suggest, that myocardial fibrosis is not related to either diabetes duration or HbA1c level. Subclinical myocardial fibrosis can therefore occur in early stages of type 2 diabetes mellitus even with well controlled HbA1c levels.

**Keywords:** Myocardial fibrosis, Type 2 Diabetes mellitus, Cardiac MRI, T1 mapping, ECV





# KARDİYOVASKÜLER AKADEMİ KONGRESİ

## & INTERNATIONAL ACADEMY OF YOUNG CARDIOLOGISTS

Elexus Hotel Girne, K.K.T.C.  
18-22 Eylül 2024

Native T1 and ECV values according to diabetes duration and HbA1c level

	DM ≤ 5 years; n=6	DM > 5 years; n=11	p-value	HbA1c ≤ 7.5 n=7	HbA1c > 7.5 n=11	p-value
<b>T1 values</b>						
Basal anterior	1035 ± 61.3	994.5 ± 38.4	0.101	1013 ± 42	1004 ± 55.4	0.723
Basal anteroseptal	1047 ± 24	1025 ± 40.7	0.245	1023 ± 53.2	1038 ± 22.4	0.492
Basal inferoseptal	1031 ± 28.6	1031 ± 44.3	0.987	1016 ± 43.5	1041 ± 34.1	0.188
Basal inferior	1046 ± 23.4	1034 ± 29.7	0.409	1041 ± 22.5	1036 ± 31.3	0.710
Basal inferolateral	999 ± 40	1001 ± 47.8	0.908	1000 ± 35.2	1001 ± 50.7	0.971
Basal anterolateral	1015 ± 34.2	996 ± 24.6	0.195	998 ± 27.1	1005 ± 30.5	0.631
Mid anterior	1033 ± 43.9	1011 ± 65.1	0.463	992 ± 56.4	1035 ± 55.7	0.127
Mid anteroseptal	1030 ± 17.8	1028 ± 69.1	0.953	1005 ± 48.1	1044 ± 58.1	0.160
Mid inferoseptal	1070 ± 44	1042 ± 65.7	0.352	1036 ± 68.1	1061 ± 54.8	0.412
Mid inferior	1039 ± 52.6	1028 ± 37.8	0.333	1039 ± 49.9	1028 ± 39.2	0.298
Mid inferolateral	1029 ± 53.7	994 ± 63.6	0.405	1010 ± 49.9	995 ± 65.2	0.821
Mid anterolateral	1034 ± 47.2	1012 ± 58.1	0.435	1011 ± 53.1	1025 ± 57	0.622
Apical anterior	1058 ± 29.1	1040 ± 72.7	0.583	1051 ± 80	1043 ± 49.8	0.813
Apical septal	1093 ± 64.2	1041 ± 67.6	0.075	1087 ± 60.9	1038 ± 62.3	0.650
Apical inferior	1072 ± 27.5	1006 ± 49	0.039	1038 ± 35.7	1040 ± 50.9	0.684
Apical lateral	1080 ± 69.9	1016 ± 60.4	0.190	1100 ± 64.6	1022 ± 61.1	0.052
<b>ECV values</b>						
Basal anterior	26.8 ± 4.4	27.5 ± 4.7	0.777	28.5 ± 5.9	26.4 ± 3.3	0.347
Basal anteroseptal	27.5 ± 3.8	28 ± 3.1	0.850	28 ± 4.4	27 ± 2.8	0.373
Basal inferoseptal	26.6 ± 2.1	27.7 ± 4.0	0.738	27.2 ± 2.6	28.3 ± 3.7	0.516
Basal inferior	28. ± 2	27.9 ± 3.8	0.962	26.6 ± 2.1	27.7 ± 4.0	0.890
Basal inferolateral	27.2 ± 2.8	26.5 ± 3.9	0.682	26.9 ± 2.8	26.6 ± 4.1	0.598
Basal anterolateral	25.1 ± 1.9	26 ± 6.4	0.765	26 ± 5.0	25.5 ± 5.7	0.866
Mid anterior	25.6 ± 3.3	24.7 ± 2.8	0.557	25 ± 4.1	25 ± 2.2	0.952
Mid anteroseptal	28.3 ± 4.0	26 ± 3	0.570	26 ± 8.5	24 ± 3.7	0.292
Mid inferoseptal	29.1 ± 5.9	26.1 ± 2.7	0.155	28.2 ± 5.9	26.4 ± 2.6	0.379
Mid inferior	26.5 ± 4	26.5 ± 3.8	0.705	28 ± 3.7	26 ± 3.9	0.522
Mid inferolateral	26.1 ± 2.4	25 ± 5.0	0.629	24.1 ± 5.8	26.2 ± 2.9	0.320
Mid anterolateral	28.3 ± 5.1	25.4 ± 3.8	0.193	28.8 ± 5.5	24.8 ± 2.7	0.054
Apical anterior	25.6 ± 2.1	26.6 ± 5.3	0.672	25.8 ± 3.2	26.6 ± 5.3	0.733
Apical septal	28.3 ± 4.0	27.7 ± 4.8	0.646	29.4 ± 3.1	27.2 ± 5.1	0.339
Apical inferior	27.6 ± 3.2	27.5 ± 3.7	0.923	27 ± 4.9	26 ± 4.1	0.891
Apical lateral	27.8 ± 3.8	27 ± 6.3	0.775	28.8 ± 4.5	26.2 ± 6.1	0.353

Baseline characteristics of the patients



# KARDİYOVASKÜLER AKADEMİ KONGRESİ

## & INTERNATIONAL ACADEMY OF YOUNG CARDIOLOGISTS

Elexus Hotel Girne, K.K.T.C.  
18-22 Eylül 2024

	Diabetes duration < 5 years n = 6	Diabetes duration > 5 years n = 12	p value
Clinical characteristics			
Age in years	52.3 + 9.4	53.8 + 7.5	0.682
Gender, male, n (%)	1 (16.6)	7 (58.3)	.152
BMI	29 + 2.5	30.6 + 5.8	.538
Laboratory parameters			
WBC (103/ $\mu$ L)	6.9 + 1.3	8.4 + 2	0.129
Hb (g/dL)	12.5 + 1.6	14.3 + 1.5	0.037
Creatinine mg/dL	0.8 + 0.26	0.69 + 0.15	0.268
GFR (mL/min/1.73m <sup>2</sup> )	87.5 + 24.2	103.7 + 11.7	0.286
LDL (mg/dL)	111.3 + 23.1	96.1 + 33.1	0.338
HDL (mg/dL)	50 + 17.7	49 + 14.5	0.911
Triglyceride (mg/dL)	168.6 + 53.2	237 + 47.7	0.462
MRI parameters			
EDV (ml)	134.6 + 39.9	121.1 + 30.7	0.438
SV (ml) CO (l/min)	78.5 + 23	67.7 + 17.4	0.280
SV (ml) CO (l/min)	6.6 + 1.8	5.4 + 1.3	0.131
LV mass	101.7 + 18.5	121.3 + 43.5	0.202
EF (%)	60.2 + 6.8	58.4 + 2.0	0.392

*Clinical, laboratory and MRI parameters*



# KARDİYOVASKÜLER AKADEMİ KONGRESİ

## & INTERNATIONAL ACADEMY OF YOUNG CARDIOLOGISTS

Elexus Hotel Girne. K.K.T.C.  
18-22 Eylül 2024

### [OP-52] Evaluation of right ventricular function in patients with subacute thyroiditis

Gazi Çapar<sup>1</sup>, Naci Şenkal<sup>2</sup>, Alpay Medetalibeyoğlu<sup>2</sup>, Tufan Tükek<sup>2</sup>

<sup>1</sup>HEALTH SCIENCES UNIVERSITY ISTANBUL BASAKSEHIR CAM & SAKURA CITY HOSPITAL CARDIOLOGY CLINIC

<sup>2</sup>ISTANBUL UNIVERSITY ISTANBUL FACULTY OF MEDICINE DEPARTMENT OF INTERNAL MEDICINE

Subacute thyroiditis is an inflammatory condition of the thyroid gland that often follows a viral infection. It can lead to various symptoms such as neck pain, fever, fatigue, and thyroid hormone abnormalities. While subacute thyroiditis primarily affects the thyroid gland, its impact on the heart can be indirect, especially if thyroid hormone levels become significantly imbalanced. Thyroid hormones play a crucial role in regulating heart function. Both hypothyroidism and hyperthyroidism can affect the cardiovascular system. In the case of subacute thyroiditis, the thyroid gland typically becomes overactive initially due to the inflammation, leading to a temporary increase in thyroid hormone levels. This hyperthyroid state can potentially affect the heart in several ways ( like tachycardia, arrhythmias, increased cardiac output, worsening heart failure... ). Hyperthyroidism can lead to increased cardiac output and increased cardiac workload can lead to right heart strain. This strain occurs when the right ventricle is required to pump blood against increased pulmonary vascular resistance, leading to right ventricular hypertrophy or dilation which may affect right ventricular function. Hypothyroidism, on the other hand, can lead to decreased cardiac output, bradycardia, and alterations in vascular resistance, which can also affect right ventricular function. In conclusion, subacute thyroiditis can impact right ventricular systolic function through various mechanisms, including thyroid hormone-mediated effects on contractility, hemodynamic changes, arrhythmias, and inflammation. Understanding this relationship is crucial for appropriate management and monitoring of individuals with subacute thyroiditis, particularly those at risk of cardiovascular complications.

**Keywords:** thyroiditis, ventricle, subacute, right





# KARDİYOVASKÜLER AKADEMİ KONGRESİ

## & INTERNATIONAL ACADEMY OF YOUNG CARDIOLOGISTS

Elexus Hotel Girne, K.K.T.C.  
18-22 Eylül 2024

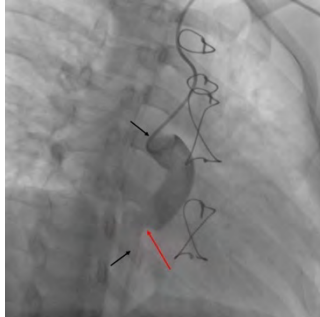
### **[OP-53] Performing sympathetic renal denervation procedure for the patient with persistent resistant hypertension following aortic coarctation intervention**

Cem Doğan, Ravza Betül Akbaş, Süleyman Çağan Efe, Anıl Avcı, Gülümser Sevgin Halil, Regayip Zehir Kartal Koşuyolu Heart and Research Hospital

Randomized, sham-controlled trials have confirmed the efficacy and safety of catheter-based renal denervation in treating resistant hypertension. A 26-year-old female patient complained of having high blood pressure. The patient's medical history included a record of ascending-descending bypass surgery for a diagnosis of post-ductal type aortic coarctation in 2017. Two years after the surgery, narrowing was observed in the graft, leading to the placement of a stent in the coarctation region of the patient's aorta. Following the intervention, the patient with persistent hypertension had their antihypertensive medication regimen adjusted. In 2023, the patient with resistant hypertension was evaluated in the council, and it was decided to proceed with sympathetic renal denervation intervention. In May 2023, the patient underwent renal sympathetic denervation procedure using the simplicity Spyral RF (radiofrequency) catheter system. Shortly after the procedure, the patient's blood pressure became regulated, and she is currently only using nebivolol 10 mg.

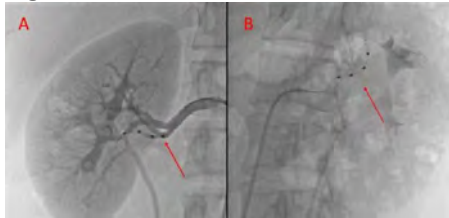**Keywords:** coarctation, denervation, hypertension

**Figure-1**



*Fluoroscopic images of CoA stent procedure.*

**Figure-2**



*: 2 A- Angiography and denervation of the right renal artery B- Angiography and denervation of the left renal artery*





# KARDİYOVASKÜLER AKADEMİ KONGRESİ

## & INTERNATIONAL ACADEMY OF YOUNG CARDIOLOGISTS

Elexus Hotel Girne, K.K.T.C.  
18-22 Eylül 2024

### [OP-54] Could GDF-15 measured at admission predict the development of fragmented QRS in patients with acute coronary syndrome undergoing primary percutaneous coronary intervention

Emrah Ozdemir

*Biruni University, Medical Faculty, Department of Cardiology, Istanbul*

**Introduction:** Atherosclerosis is a chronic inflammatory disease of vascular intima usually effecting the branching points of the vascular tree where shear stress changes mostly take place. Atherosclerosis related diseases are leading causes of mortality and morbidity all around the world. Growth differentiation factor 15 (GDF-15) is a distinct member of the transforming growth factor- $\beta$  (TGF- $\beta$ ) superfamily which is a potent regulator of vascular remodelling and play a key role in atherosclerosis. Fragmented QRS (fQRS), defined as additional spikes within the QRS complex, is a convinient marker of myocardial scar which could be easily evaluated by 12 lead ECG recording. It is also a predictor of mortality and arryhtmic events in patients with reduced left ventricular function. In this prospective study, we analysed the effect of the admission GDF-15 levels and development of the fragmented QRS in acute coronary syndrome patients undergoing primary percutaneous coronary intervention (PCI).

**Methods:** In this prospective cross-sectional study, patients admitted to the emergency department with chest pain and diagnosed with acute coronary syndrome (ACS) were evaluated. Who have previously diagnosed coronary artery disease, known or newly developed any kind of bundle branch block or fQRS were excluded. 117 patients (71 male, 46 female) were included. All patients' demographic-clinical data were collected, SYNTAX score were calculated, blood samples were taken for biochemical analyses, and measurement of GDF-15. Each patient was treated with appropriate PCI technique. All included patients were evaluted at the 1st month of PCI and ECG, transthoracic echocardiography were performed. Collected data was analysed.

**Results:** At the first month follow-up visit; newly developed fQRS were seen in 33 patients. Patients grouped according to the presence of fQRS. GDF-15 level ( $1233.06 \pm 235.11$  vs.  $2381.90 \pm 342.67$ ;  $p < 0.001$ ), SYNTAX score ( $7.80 \pm 1.23$  vs.  $12.45 \pm 2.51$ ;  $p < 0.001$ ), SYNTAX 2 score ( $9.68 \pm 5.71$  vs.  $22.5 \pm 6.71$ ) were significantly higher and EF ( $51.25 \pm 5.69$  vs.  $46.72 \pm 3.54$ ;  $p = 0.021$ ) was significantly lower in fQRS(+) group. Wire crossing times were similar between 2 group ( $45.67 \pm 7.34$  vs.  $46.11 \pm 6.48$ ;  $p = 0.769$ ). GF-15 level at admission was found to be an independent risk factor for fQRS development at first month [ $p < 0.001$ ,  $\beta: 1.028$ , OR (95% CI): 1.014-1.056]. ROC analysis revealed that, a cut-off value of 1754.00 for GDF-15 was associated with 80.81% sensitivity and 80.84% specificity in prediction of development of fQRS at first month (AUC: 0.829[%95 CI: 0.753-0.906]) (figure 1)

**Conclusion:** This study provided that, GDF-15 level at admission could be used to predict development of fQRS at first month of PCI in ACS patients.


**Keywords:** GDF-15, fragmented QRS, SYNTAX score, acute coronary syndrome

# KARDİYOVASKÜLER AKADEMİ KONGRESİ

## & INTERNATIONAL ACADEMY OF YOUNG CARDIOLOGISTS

Elexus Hotel Girne, K.K.T.C.  
18-22 Eylül 2024

figure 1



*roc analysis*



# KARDİYOVASKÜLER AKADEMİ KONGRESİ

## & INTERNATIONAL ACADEMY OF YOUNG CARDIOLOGISTS

Elexus Hotel Girne, K.K.T.C.  
18-22 Eylül 2024

### **[OP-55] Endovascular treatment of mesenteric artery aneurysm using flow diverting ROAD-SAVER stent to preserve the flow of side branches**

Abdulrahman Naser<sup>1</sup>, Müslüm Şahin<sup>2</sup>

<sup>1</sup>Department of Cardiology, Kırklareli Training and Research Hospital, Kırklareli, Türkiye

<sup>2</sup>Department of Cardiology, Medicalpark Pendik Hospital, Istanbul, Türkiye

A 56-year-old male patient applied with the complaint of abdominal pain that had been continuing for the last three months. He had hyperlipidemia and smoking in her past medical history. GIS endoscopy revealed ischemic foci in the colon/ischemic colit. Computed tomography (CT) examination revealed aneurysmatic dilatation in the proximal SMA, containing mural thrombus and reaching 13 mm in diameter at its widest point. The patient's ECG was in sinus rhythm, and echocardiography revealed normal shape and function without intracardiac thrombus. The patient was anticoagulated and his abdominal pain disappeared during follow-up. In the CT scan performed 2 years later, it was observed that the aneurysm had grown to 19 mm at its widest point.

Percutaneous catheter-based intervention was planned. Under local anesthesia a 6F sheath was placed in the left brachial artery, and angiographic images (Figure-1) were obtained with a 5F JR-4 diagnostic catheter to detail the aneurysm and side branches. Then, the superior mesenteric artery (SMA) was cannulated with the 6F Multipurpose guiding catheter, and a 0.035 hydrophilic wire was advanced into the pancreato-duodenal artery. The hydrophilic wire was then replaced with a non-hydrophilic Teflon wire via the microcatheter, and the 7F destination catheter was advanced over this (non-hydrophilic Teflon wire) wire and engaged in the SMA. An 8.0\*27 mm covered stent was implanted in the proximal part of the aneurysm, and a 7.0\*25 mm double-layer micromesh ROAD-SAVER flow diverter stent was implanted in the distal part (Figure-2). The procedure was successfully completed without acute side branch loss. The patient is followed clinically asymptomatic for the 7 months after the procedure. Superior mesenteric artery aneurysms (SMAAs) are rare clinical entities, causes in abdominal pain. SMAAs occur most commonly in adults and have a male predominance. SMA aneurysms are clinically important due to serious complications such as embolism and rupture, which can lead to acute mesenteric ischemia and fatal massive bleeding. According to recently published Society of Vascular Surgery guidelines, repair is recommended for all SMAAs. Although open surgical approaches are the mainstay in the treatment of SMAAs, endovascular techniques remain a reasonable alternative. In the context of percutaneous endovascular treatment, graft stents and coil embolization are currently used. In this case, we used the Road-saver stent, which is generally used in the treatment of carotid artery stenosis with its ability to prevent plaque prolapse and direct flow.

**Keywords:** Endovascular treatment, Mesenteric artery aneurysm, Flow diverting ROAD-SAVER stent

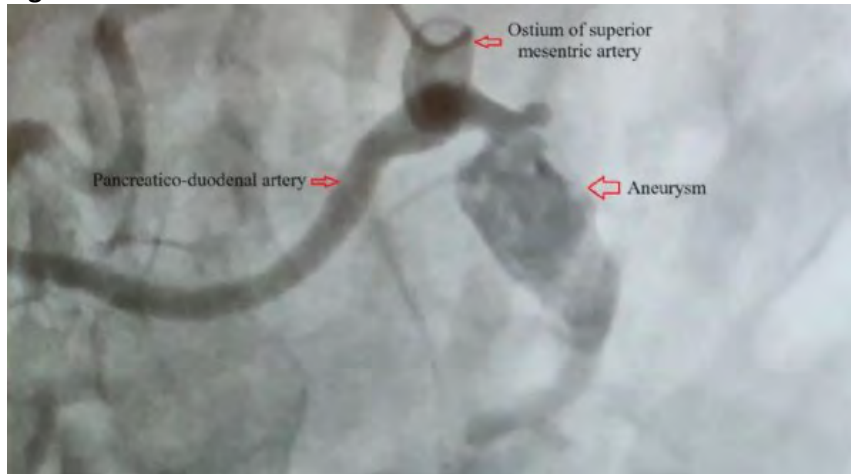


# KARDİYOVASKÜLER AKADEMİ KONGRESİ

## & INTERNATIONAL ACADEMY OF YOUNG CARDIOLOGISTS

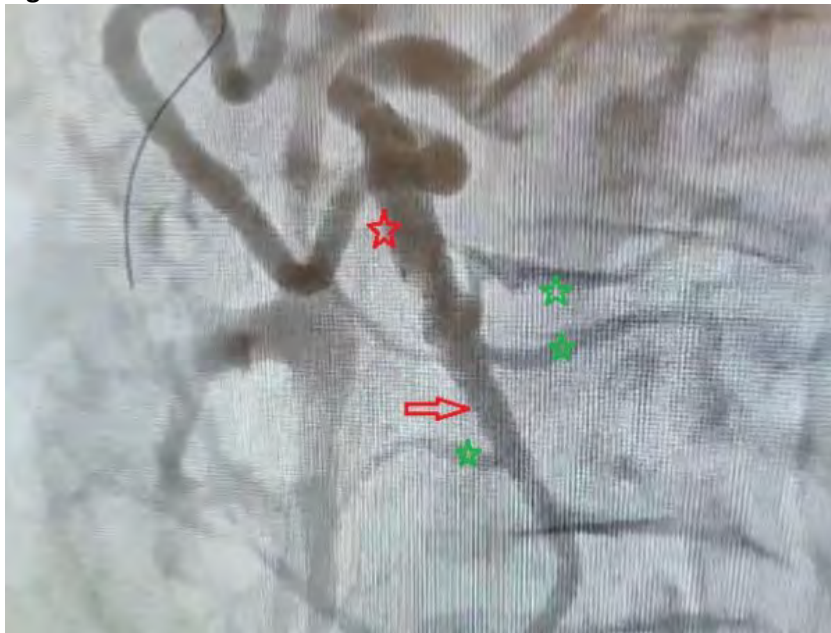Elexus Hotel Girne, K.K.T.C.  
18-22 Eylül 2024

**Figure-1**



*Diagnostic angiographic view of superior mesenteric artery aneurysm*

**Figure-2**



*Image after endovascular intervention. Red star indicating graft stent, red arrow indicating ROAD-SAVER stent, yellow stars indicating side branches (Jejunal branches)*

**AuthorToEditor:** Road-saver dual-layer stents are generally used in the treatment of carotid artery stenosis, with its ability to prevent plaque prolapse and direct flow. In the present case we successfully used this innovative technological stent in the treatment of superior mesenteric artery aneurysm.





# KARDİYOVASKÜLER AKADEMİ KONGRESİ

## & INTERNATIONAL ACADEMY OF YOUNG CARDIOLOGISTS

Elexus Hotel Girne, K.K.T.C.  
18-22 Eylül 2024

### [OP-57] Impact of the baseline renal function status on the long-term prognosis in patients underwent transcatheter aortic valve implantation

Fatih Erkam Olgun, Melike Zeynep Kenger, Aykun Hakgör  
Istanbul Medipol University Medipol Mega Hospital

**Background and aim:** It is known that the presence of chronic renal failure (CRF) increases the incidence of procedural and in-hospital adverse events, although this varies according to the stage of the disease. However, there is a lack of evidence on the long-term prognostic impact of concomitant CRF in patients undergoing transcatheter aortic valve implantation (TAVI). In this study, we investigated the effect of pre-procedural renal function status on 2-year overall all-cause mortality in patients undergoing TAVI.

**Methods:** This retrospective-observational study included 395 patients (mean age  $78.2 \pm 8.3$  years, 201 [50.9%] women) who underwent TAVI for severe AS at a single-center. Glomerular filtration rate (GFR) (mL/min/1.73m<sup>2</sup>) of all patients was calculated individually based on preoperative blood tests obtained for TAVI preparation and the study population was divided into 3 groups according to baseline GFR: <30, 31-59 and  $\geq 60$ . All in-hospital adverse events were meticulously recorded and patients who reached the survival outcome were evaluated periodically for a complete 2-year follow-up. The effect of different GFR groups on 2-year all-cause survival of these patients was investigated using appropriate statistical methods.

**Results:** Figure 1 shows the comparison of various characteristics of the 3 different groups with ordinal relationship between them according to the baseline GFR of the patients included in the study. There were no significant differences between the groups in terms of procedural characteristics, vascular complications and in-hospital mortality, but the GFR <30 group had longer hospitalization, more frequently permanent pacemaker implantation required, and a higher incidence of paravalvular aortic regurgitation  $\geq 2$ nd grade. The 2-year all-cause mortality rates between the groups were 36.6%, 26% and 18%, respectively ( $p=0.015$ ).

According to univariate Cox-regression analysis investigating the predictors of 2-year all-cause mortality as the primary outcome in the study population, age, LVEF, body mass index, presence of chronic obstructive pulmonary disease (COPD) and being in the GFR <30 group were found to be associated with the primary outcome. Being in the GFR=31-59 group was associated with a non-statistically significant increased 2-year mortality compared to being in the GFR  $\geq 60$  group (HR:1.45, 95%CI [0.88-2.39],  $p=0.141$ ). However, with reference to the GFR  $\geq 60$  group, being in the GFR <30 group was found to be an independent predictor of 2-year mortality according to multivariate analysis (HR:1.94, 95%CI [1.05-3.57],  $p=0.033$ ) (Table 1). The 24-month Kaplan-Meier survival curves plotted according to the baseline GFR groups are shown in Figure 2.

**Conclusions:** CRF is associated with poor long-term outcomes in patients undergoing TAVI. In particular, GFR less than 30 mL/min/1.73m<sup>2</sup> is an independent predictor of all-cause mortality at 2-year follow-up in patients undergoing TAVI, as supported by this study.

**Keywords:** Transcatheter aortic valve implantation, chronic renal failure, long-term prognosis, glomerular filtration rate



# KARDİYOVASKÜLER AKADEMİ KONGRESİ

## & INTERNATIONAL ACADEMY OF YOUNG CARDIOLOGISTS

Elexus Hotel Girne, K.K.T.C.  
18-22 Eylül 2024

Figure 1

Table-1: Comparison of various characteristic features of the study group in-terms of CRF stage.

Variable	GFR <30 (mL/min/1.73m <sup>2</sup> ) (N=41, 10.2%)	GFR= 31-59 (mL/min/1.73m <sup>2</sup> ) (N=104, 25.9%)	GFR ≥60 (mL/min/1.73m <sup>2</sup> ) (N=250, 62.3%)	p value
<b>Baseline Characteristics</b>				
Age	80.5±7.3	79.1±7.8	77.4±8.6	0.039
Gender (female)	19 (46.3%)	54 (51.9%)	128 (51.2%)	0.821
BMI (kg/m <sup>2</sup> )	27.6±4.1	28±4.9	26.6±4.1	0.014
Hypertension	39 (95.1%)	88 (84.6%)	213 (85.2%)	0.208
Diabetes	23 (56.1%)	41 (39.4%)	77 (30.8%)	0.005
Atrial Fibrillation	18 (43.9%)	40 (38.5%)	79 (31.6%)	0.198
COPD	20 (48.8%)	36 (34.6%)	98 (39.2%)	0.287
Previous CVA	2 (4.9%)	5 (4.8%)	15 (6%)	0.887
CAD	29 (70.7%)	71 (68.3%)	168 (67.2%)	0.899
Previous Cardiac Surgery	10 (24.4%)	16 (15.4%)	36 (14.4%)	0.264
STS score	12.3±5.3	10.4±4.4	8.9±4.5	<0.001
<b>Echocardiographic Measures</b>				
LVEF (%)	48±13.5	47.8±14	52.7±10.8	0.001
Peak Gradient (mmHg)	68.7±21.4	70.6±19.4	75.7±20.4	0.028
Mean Gradient (mmHg)	45±13.5	45.3±13.2	48.6±13.5	0.056
Aortic Valve Area (m <sup>2</sup> )	0.73±0.15	0.71±0.14	0.71±0.15	0.602
AR ≥2 degree	23 (56.1%)	48 (46.2%)	107 (42.8%)	0.275
MR ≥2 degree	34 (82.9%)	71 (68.3%)	157 (62.8%)	0.036
TR ≥2 degree	35 (85.4%)	76 (73.1%)	195 (78.3%)	0.256
sPAP (mmHg)	48.1±12.1	44.3±10.7	42.7±10.5	0.009
LA diameter (mm)	45.8±5.3	44±6.5	42.8±5.9	0.004
<b>Procedural Features</b>				
VIV TAVI	1 (2.4%)	4 (3.8%)	11 (4.4%)	0.834
General Anesthesia	5 (12.2%)	18 (17.3%)	52 (20.8%)	0.376
Self-expanding THV	25 (61%)	69 (66.3%)	142 (56.8%)	0.245
THV Size (mm)	29 (26 – 29)	29 (26 – 29)	26 (26 – 29)	0.474
THV Implantation Success	41 (100%)	103 (99%)	243 (97.2%)	0.333
Shear size (F)	14 (14 – 18)	16 (14 – 18)	16 (14 – 18)	0.025
Predilatation	14 (34.1%)	37 (35.6%)	68 (27.2%)	0.247
Postdilatation	7 (17.1%)	31 (29.8%)	60 (24%)	0.247
Hospitalisation (days)	5 (4 – 8)	5.5 (4 – 9)	4 (3 – 6)	<0.001
<b>Advers events and outcomes</b>				
Major vascular complication	5 (12.2%)	11 (10.6%)	25 (10%)	0.910
Minor vascular complication	4 (9.8%)	12 (11.5%)	28 (11.2%)	0.953
Stroke	0 (0%)	5 (4.8%)	7 (2.8%)	0.295
Permanent pacemaker implantation	8 (19.5%)	5 (4.8%)	18 (7.2%)	0.010
PVAR ≥2 degree	9 (25.7%)	29 (30.2%)	41 (17.6%)	0.035
In-hospital mortality	7 (17.1%)	9 (8.7%)	18 (7.2%)	0.113
Mortality during follow-up	8 (19.5%)	18 (17.3%)	27 (10.8%)	0.126
Overall 2-year mortality	15 (36.6%)	27 (26%)	45 (18%)	0.015

Figure 1 shows the comparison of various characteristics of the 3 different groups with ordinal relationship between them according to the baseline GFR of the patients included in the study. Abbreviations: CRF: chronic renal failure, BMI: body mass index, COPD: chronic obstructive pulmonary disease, CVA: cerebrovascular attack, CAD: coronary artery disease, STS: Society of Thoracic Surgeons, LVEF: left ventricle ejection fraction, AS: aortic stenosis, AR: aortic regurgitation, MR: mitral regurgitation, TR: tricuspid regurgitation, sPAP: systolic pulmonary artery pressure, LA: left atrium, VIV TAVI: valve-in-valve transcatheter aortic valve implantation, THV: transcatheter heart valve, F: french, GFR: glomerular filtration rate, PVAR: paravalvular aortic regurgitation.

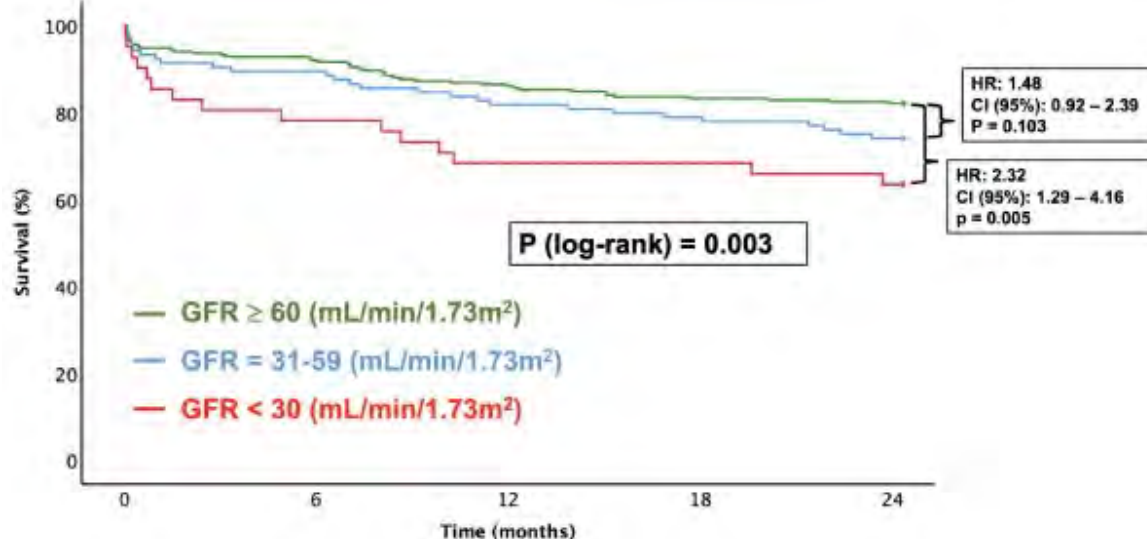
# KARDİYOVASKÜLER AKADEMİ KONGRESİ

## & INTERNATIONAL ACADEMY OF YOUNG CARDIOLOGISTS

Elexus Hotel Girne, K.K.T.C.

18-22 Eylül 2024

Figure 2



The 24-month Kaplan-Meier survival curves plotted according to the calculated baseline GFR groups are shown in Figure 2.

Table 1

	Unadjusted HR (95% CI)	p value	Adjusted HR (95% CI)	p value
Age, years	1.054 (1.023 – 1.085)	<0.001	1.042 (1.012 – 1.073)	0.005
LVEF (%)	0.974 (0.959 – 0.990)	0.001	0.975 (0.958 – 0.991)	0.003
BMI (kg/m <sup>2</sup> )	0.938 (0.890 – 0.989)	0.018	0.944 (0.894 – 0.997)	0.037
COPD	1.701 (1.122 – 2.577)	0.012	1.485 (0.967 – 2.280)	0.071
GFR ≥ 60 (mL/min/1.73m <sup>2</sup> ) (reference)	-	-	-	-
GFR = 31 - 59 (mL/min/1.73m <sup>2</sup> ) (categorical)	1.488 (0.923 – 2.397)	0.103	1.454 (0.883 – 2.396)	0.141
GFR < 30 (mL/min/1.73m <sup>2</sup> ) (categorical)	2.323 (1.295 – 4.168)	0.005	1.940 (1.054 – 3.570)	0.033

Univariate and multivariate logistic regression analyses for overall 2-year mortality. BMI: body mass index, GFR: glomerular filtration rate, LVEF: left ventricle ejection fraction, COPD: chronic obstructive pulmonary disease.





# KARDİYOVASKÜLER AKADEMİ KONGRESİ

## & INTERNATIONAL ACADEMY OF YOUNG CARDIOLOGISTS

Elexus Hotel Girne, K.K.T.C.  
18-22 Eylül 2024

### [OP-58] The relationship between Neutrophil-Lymphocyte Ratio and Platelet-Lymphocyte Ratio and mortality in patients undergoing carotid artery stenting

Ali Yaşar Kılınç, Ziya Apaydın  
Haseki Training And Research Hospital

**Introduction:** Atherosclerosis is an inflammatory disease and is one of the common causes of carotid artery stenosis. Neutrophils and platelets play an important role in the pathogenesis of atherosclerosis. Studies have shown that the mortality and clinical adverse event rates are higher in patients who have had atherosclerotic disease (such as coronary artery disease, stroke, peripheral artery disease) and those with high neutrophil-lymphocyte ratio (NLR) and platelet-lymphocyte ratio (PLR). Carotid artery stenting (CAS) is a minimally invasive treatment method. There are many studies in literature regarding the relatively high long-term mortality in patients undergoing CAS. The reasons for this situation are, most of the patients are older and their comorbidity burden is high. Although there are studies on predictors of long-term mortality after CAS, data on this subject are limited. We investigated the relationship between NLR and PLR and 1-year mortality in patients who underwent CAS.

**Methods:** Patients over the age of 18 who underwent CAS were included in study and analyzed retrospectively. Considering the 1-year mortality rates, the patients were divided into two groups: those who developed mortality (mortality group) and those who did not (survival). Patients who developed procedure-related mortality were excluded from the study. Laboratory parameters of groups were compared.

Independent samples t-test and chi-square test was used to compare among two groups. Statistical significance was accepted when two-sided p value was lower than 0.05.

**Results:** A total of 128 patients were included in our study. 92 (71.9%) of the patients were male. The average age of the patients was  $67.8 \pm 7.8$ . Mortality occurred in 26 patients (20.3%) during the 1-year follow-up period. The mean age in the survival group was  $67.2 \pm 7.6$ , and  $70.1 \pm 8.2$  in mortality group ( $p=0.144$ ). In survival group 28 of 102 patients (27.4%) were female, and 8 of 26 patients (30.8%) in the mortality group were female ( $p = 0.113$ ). Atherosclerosis risk factors such as diabetes, hypertension, tobacco use and chronic kidney disease were at similar rates in both groups.

Closed cell design stent was used in all patients. If necessary, a second stent or postdilatation was performed. Both postdilatation and second stent implantation rates were similar in both groups. Therefore, procedure-related variables that may be associated with mortality did not affect the outcomes.

In the survival group, the average NLR was  $1.07 \pm 0.34$  and the average PLR was  $133.7 \pm 49.1$ , while in the mortality group, the average NLR was  $1.84 \pm 0.91$  and the average PLR was  $176 \pm 60.1$  (both p values  $<0.01$ ). CRP level, another important inflammatory marker, was found to be similar in both groups.

**Conclusion:** NLR and PLR, which are parameters studied from routine blood tests that can be easily calculated before the procedure and do not require additional costs, were found to be high in patients who developed mortality after CAS.

**Keywords:** atherosclerosis, carotid artery stenting, lymphocyte, neutrophil, platelet  
*Hourglass appearance was observed in the stent balloon.*





# KARDİYOVASKÜLER AKADEMİ KONGRESİ

## & INTERNATIONAL ACADEMY OF YOUNG CARDIOLOGISTS

Elexus Hotel Girne, K.K.T.C.  
18-22 Eylül 2024

### [OP-60] Evaluation of left ventricular systolic function by mitral annular plane systolic excursion (MAPSE) after recanalization of chronic total occlusion

Hacı Ali Kürklü<sup>1</sup>, Nil Özyüncü<sup>2</sup>, Irem Müge Akbulut Koyuncu<sup>2</sup>

<sup>1</sup>Ankara Etlik Research Hospital

<sup>2</sup>Ankara University Faculty of Medicine

**Aim:** A chronic total occlusion (CTO) is defined as a completely occluded coronary artery with TIMI 0 flow, persisting for a duration of  $\geq 3$  months. The benefits of CTO revascularization through percutaneous coronary intervention (PCI) remain a topic of debate. We aimed to search for the effect of CTO revascularization on the LV functions. Mitral annular plane systolic excursion (MAPSE,  $< 12$  mm was defined as impaired) is an established echocardiographic parameter for LV longitudinal functions. It has good correlation with LV global longitudinal strain and may be useful when sonographic windows are poor for strain analysis. We hypothesized that, MAPSE may perform better than the classical functional parameters, such as ejection fraction (EF).

**Material-Methods:** In this multicenter observational study, a cohort of 69 symptomatic patients who underwent planned revascularization of a single major epicardial were prospectively enrolled. Significant ischemia had to be proven by SPECT, if the symptoms were atypical. Follow-up was for 3 months. Acute coronary syndrome,  $\geq 50\%$  stenosis in a non-CTO artery, unsuccessful CTO PCI, akinesia or aneurysm of the target artery area and patients with reduced EF ( $EF \leq 40\%$ ) were excluded from the study. Echocardiographic parameters, including MAPSE was recorded before PCI and also at the third month of PCI.

**Results:** The study enrolled 69 patients (mean age  $64.9 \pm 9.4$  years, 81% male) who underwent PCI for a chronic total occlusion (CTO) in a single epicardial coronary artery. All enrolled patients either had typical angina pectoris or exhibited significant ischemia in cases of angina-equivalent symptoms. Demographic and clinical characteristics, basal laboratory and echocardiographic results were presented in Table-1. All patients had successful revascularization (as others were excluded) and had no major complications at the end of 3 months. Symptomatic improvement was achieved in 78% of patients. When basal and 3rd month LV functions were analysed, MAPSE values revealed significant improvement ( $10,2 \pm 2,72$  vs  $11,6 \pm 1,95$ , respectively,  $p < 0,0001$ ), however EF values showed no change ( $53,2 \pm 3,86$  vs  $53,4 \pm 3,7$ ,  $p = 0,3$ ). MAPSE and EF change by time was presented in Figure-1.

**Conclusion:** In our trial we demonstrated the high rate of anginal recovery following single-vessel CTO revascularization in patients with clear PCI indications. It may underscore the importance of appropriate patient selection. Additionally, our findings indicate that functional recovery of the myocardium following ischemia relief may not reach clinical significance when assessed using conventional echocardiography methods, particularly in a short period of time. MAPSE may serve as a valuable tool to detect subclinical functional improvement more effectively than EF, especially when strain analysis cannot be performed or yields unreliable results due to image quality.

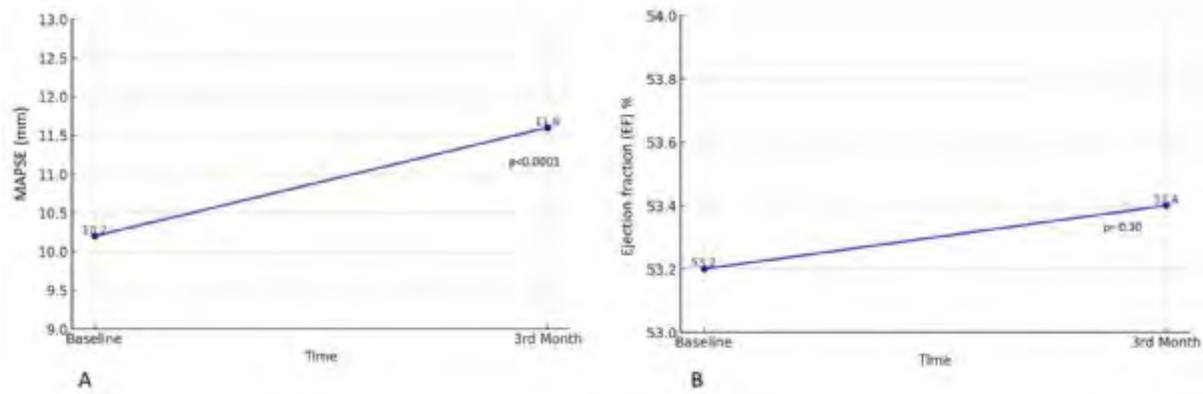
**Keywords:** mitral annular plane systolic excursion, chronic total occlusion, coronary artery disease

# KARDİYOVASKÜLER AKADEMİ KONGRESİ

## & INTERNATIONAL ACADEMY OF YOUNG CARDIOLOGISTS

Elexus Hotel Girne, K.K.T.C.  
18-22 Eylül 2024

### MAPSE and EF change graphics for basal and third month of revascularization



MAPSE and EF change graphics for basal and third month of revascularization. MAPSE values (A) improved significantly after successful revascularization, whereas EF values (B) revealed no change by time. MAPSE: Mitral annular systolic excursion, EF: ejection fraction

**Table1: Baseline Characteristics of The Study Population**

Characteristics	N=69
Age	64,9±9.4
Gender	
Male n, (%)	56 (81,2)
Female n, (%)	13 (18,8)
BSA m <sup>2</sup> #	1,87±0,15
HT n, (%)	50 (72,5)
DM n,(%)	41 (59,4)
HL n, (%)	28(40,6)
Smoking n, %	37(53,6)
Family history n,%	22(31,9)
Laboratory Result	
PFG mg/dl	101,1±10,4
Hemoglobin g/dl	14,0±2,13
Platelet	249±75.05
Creatinine (mg/dl)	0,89±0,19
TC mg/dl	192±51,4
LDL-C mg/dl	125±43,2
HDL-C (mg/dl)	43,3±13,0
Echocardiography	

# KARDİYOVASKÜLER AKADEMİ KONGRESİ

## & INTERNATIONAL ACADEMY OF YOUNG CARDIOLOGISTS

Elexus Hotel Girne. K.K.T.C.  
18-22 Eylül 2024

LVEDD mm	51,03±6,04
LVESD mm	29,02±4,19
EF%	53,2±3,86
MAPSE mm	10,23±2,72
CCS Angina Grading (I/II/III/IV)	0/28/34/7
Coronary Angiography	
CTO artery LAD/CX/RCA	27/11/31
Prior CABG n, (%)	0
Prior PCI to Target coronary artery n, (%)	33 (47,8)
Prior PCI (all) n, (%)	37 (53,6)
Prior MI in CTO area	13 (18,8)
Prior MI (all) n, (%)	17 (24,6)

*Table 1: Baseline Characteristics of The Study Population Data are expressed as means±SD, as n (%). BSA: # Calculation of left atrial volume ratio body surface area. BSA; body surface area; index HT: hypertension; DM: Diabetes Mellitus; HL: Hyperlipidemia; inhibitor FPG: Fasting plasma glucose; TC: total cholesterol; HDL-C: high-density cholesterol level; LDL-C: low-density cholesterol level; LVEDD: left ventricular end-diastolic diameter; LVESD: left ventricular end-systolic diameter; EF: ejection fraction; MAPSE: Mitral annular plane systolic excursion; CCS Angina Grading: Canadian Cardiovascular Society Grading of Angina Pectoris CABG: coronary artery bypass grafting; CTO chronic total occlusion; MI myocardial infarction; PCI percutaneous coronary intervention; LAD left anterior descending artery; LCX left circumflex artery; RCA right coronary artery*

**AuthorToEditor:** We are pleased to submit our work about the effects of CTO revascularization on LV functions. The benefits of CTO revascularization through PCI remain a topic of debate. Currently, the primary objective of CTO-PCIs is to achieve mainly symptom improvement and to some extent improve left ventricular (LV) functions in selected group of patients. We aimed to search for the effect of CTO revascularization on the LV functions, detected by Mitral annular plane systolic excursion (MAPSE), which is an established echocardiographic parameter for LV longitudinal functions, a sensitive marker for subtle ischemic changes. As a result, we demonstrated the high rate of anginal recovery following single-vessel CTO revascularization in patients with clear PCI indications. It may underscore the importance of appropriate patient selection. At the end of the third month MAPSE values significantly improved after the successful revascularization, however EF values did not reveal change. MAPSE may serve as a valuable tool to detect subclinical functional improvement more effectively than EF, especially when strain analysis cannot be performed or yields unreliable results due to image quality. We believe results of our trial may be important about this debatable topic

Figure-1

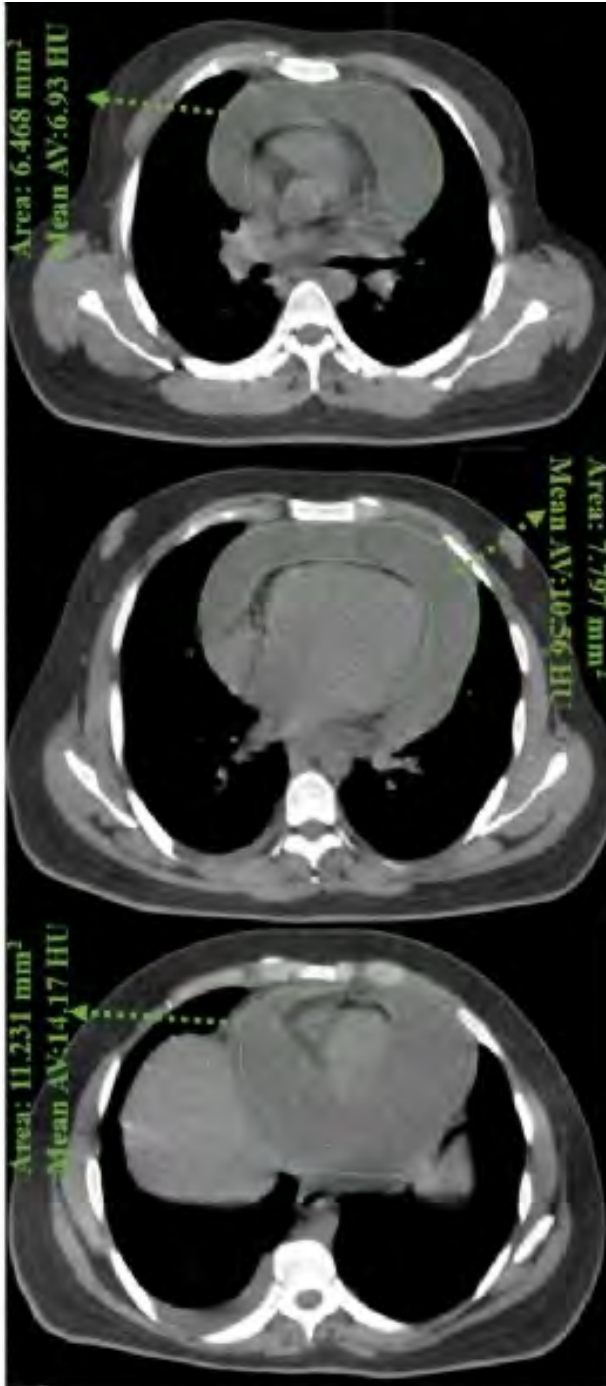
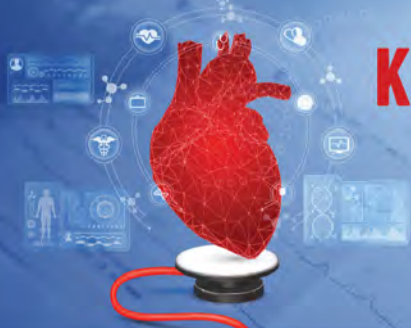

Figure 1. Measurement of the area and attenuation value of PE by CT in the upper, middle and lower regions during diastole.





# KARDİYOVASKÜLER AKADEMİ KONGRESİ

## & INTERNATIONAL ACADEMY OF YOUNG CARDIOLOGISTS

Elexus Hotel Girne, K.K.T.C.  
18-22 Eylül 2024

**Table 2 and Table 3**

**Table -2 Univariate and multivariate logistic regression analysis of pericardial tamponade predictors**

	Univariate Regression		Multivariate Regression	
	OR (95% CI)	P	OR (95 % CI)	P
Ejection fraction < %50	0.91 (0.64-1.29)	0.580		
Malign/Non-malign effusion	2.65 (0.14-48.3)	0.512		
Drained PE, mL	2.62 (0.25-27.7)	0.418		
Attenuation value in CT, HU	0.78 (0.64-0.96)	0.020	0.95 (0.85-1.07)	0.378
Max PE size on CT (diastole), mm <sup>2</sup>	1.14 (0.99-1.32)	0.046	1.18 (1.08-12.3)	<0.001
Min PE size on CT (diastole), mm <sup>2</sup>	0.68 (0.51-0.90)	0.007	0.75 (0.64-0.87)	<0.001
Max PLE size, right-sided, mm <sup>2</sup>	1.03 (0.90-1.19)	0.612		
Max PLE size, left -sided, mm <sup>2</sup>	1.08 (0.88-1.34)	0.429		
Max/Min PE size, (diastole)	1.17 (0.58-1.83)	0.470		
Max PE/ Max PLE size, right-sided	1.16 (0.81-1.67)	0.408		
Max PE/ Max PLE size, left-sided	0.99 (0.96-1.02)	0.460		

CI, confidence interval, CT, computed tomography, HU, hounsfield unit, OR, odds ratio, PE, pericardial effusion, PLE: pleural effusion.

**Table-3 ROC analysis of parameters predicting pericardial tamponade**

	AUC	95 % CI	p value
Max PE size on CT (diastole), mm	0.655	0.531-0.780	0.021
Min PE size on CT (diastole), mm	0.660	0.532-0.788	0.017

AUC, area under curve, CI, confidence interval, CT, computed tomograph, PE, pericardial effusion ROC, receiver operating characteristic.

**Table-1 Baseline characteristics of the study population**

Variables	Tamponade (-) (n=28)	Tamponade (+) (n=56)	P value
Age, years	46.6±21.2	55.4±21.1	0.075
Male, n(%)	13 ( %46 )	35 ( %62 )	0.171
DM, n(%)	8 ( %29 )	27 ( %48 )	0.426
HT, n(%)	5 ( %18 )	15 ( %28 )	0.104
CAD, n(%)	6 ( %21 )	24 ( %43 )	0.321
TB, n(%)	3 ( %0 )	3 ( %5 )	0.212
COVID -19, n(%)	3 ( %11 )	10 ( %18 )	0.394
Smoking, n(%)	6 ( %21 )	23 ( %41 )	0.171



# KARDİYOVASKÜLER AKADEMİ KONGRESİ

## & INTERNATIONAL ACADEMY OF YOUNG CARDIOLOGISTS

Elexus Hotel Girne, K.K.T.C.  
18-22 Eylül 2024

CFR, n(%)	3 ( %11 )	7 ( %12 )	0.812
Hepatic cirrhosis, n(%)	0 ( %0 )	1 ( %2 )	0.477
History of pericarditis, n(%)	9 ( %32 )	6 ( %10 )	0.061
History of malignancy, n(%)	6 ( %21 )	24 ( %43 )	0.059
Weight, kg	72.1±21.2	55.4±21.1	0.075
Height, cm	163.1±17.1	163.7±19.5	0.893
AF, n(%)	1 ( %4 )	13 ( %23 )	0.026
EF<%50, n ( % )	1 ( %4 )	6 ( %11 )	0.416
Malign PE, n ( % )	8 ( %26 )	24 ( %43 )	0.240
PE sample			0.165
Transudate, n ( % )	17 ( %61 )	25 ( %45 )	
Exudate, n ( % )	11 ( %39 )	31 ( %55 )	
CRP, mg/dL	66.5±85.5	66.8±72.1	0.988
Serum glucose, mg/dL	129±54	138±66	0.552
Serum total protein, g/L	64±7.8	61±7.7	0.069
Serum albumin, g/	38.1±5.6	35.1±5.7	0.029
Serum LDH, U/L	261±119	557±1133	0.240
Serum pH	7.41±0.55	7.38±0.08	0.035
PE glucose, mg/dL	64±20.6	58.6±23.4	0.301
PE total protein, g/L	31.8±8.7	31.9±7.9	0.948
PE albumin, g/L	23.8±7.5	23.6±7.5	0.875
PE LDH, U/L	847±860	1158±1234	0.236
PE, pH	7.37±0.58	7.23±0.95	0.457
Attenuation value in CT, HU	3.22±4.35	3.61±4.73	0.718
Max PE size on CT (diastole), mm <sup>2</sup>	22.74±8.41	27.4±8.18	0.017
Min PE size on CT (diastole), mm <sup>2</sup>	12.90±5.56	10.02±4.92	0.018
Max PLE size, right-sided, mm <sup>2</sup>	13.84±7.57	14.82±8.35	0.603
Max PLE size, left -sided, mm <sup>2</sup>	6.60±4.93	6.51±3.98	0.931
Max/Min PE size (diastole)	2.33±1.92	4.14±4.40	0.041
Max PE/ Max PLE size, right-sided	2.73±3.18	3.22±4.15	0.585
Max PE/ Max PLE size, left-sided	9.20±14.3	13.06±28.83	0.506
Drained PE, ml	816.9±549.3	735.9±511.1	0.522
PC site			0.150
Apex, n ( % )	14 ( %50 )	19 ( %34 )	



# KARDİYOVASKÜLER AKADEMİ KONGRESİ

## & INTERNATIONAL ACADEMY OF YOUNG CARDIOLOGISTS

Elexus Hotel Girne. K.K.T.C.  
18-22 Eylül 2024

Subcostal, n(%)	12 (%43)	34 (%61)	
Recurrent PE, n(%)	10 ( %36 )	8 ( %14 )	0.062
In-hospital mortality, n(%)	6 ( %21 )	14 ( %25 )	0.792
30-day mortality, n(%)	3 ( %11 )	10 ( %18 )	0.529
Long -term mortality, n(%)	5 ( %18 )	19 ( %34 )	0.199

*AF; atrial fibrillation, CAD; coronary artery disease, CFR; chronic renal failure, COVID-19; coronavirus disease 2019, CRP; C reactive protein, CT; computed tomography, DM; diabetes mellitus, EF; ejection fraction, HT;hypertension, HU; hounsfield unit, LDH; lactate dehydrogenase, PC; Pericardiocentesis, PE;pericardial effusion, PLE; pleural effusion, TB; tuberclosis.*

# KARDİYOVASKÜLER AKADEMİ KONGRESİ

## & INTERNATIONAL ACADEMY OF YOUNG CARDIOLOGISTS

Elexus Hotel Girne, K.K.T.C.  
18-22 Eylül 2024

### [OP-63] A New Marker To Predict No-Reflow Phenomenon: Leukocyte/Glucose Index

Onur Altinkaya<sup>1</sup>, Sıdar Şiyar Aydın<sup>2</sup>

<sup>1</sup>Department of Cardiology, University of Health Sciences, Erzurum City Hospital, Erzurum, Turkey.

<sup>2</sup>Department of Cardiology, Atatürk University Faculty of Medicine, Erzurum, Turkey.

**Objective:** Acute coronary syndromes (ACS) are one of the most common causes of morbidity and mortality worldwide. Primary percutaneous coronary intervention (PPCI) is the main treatment strategy to restore myocardial perfusion. Despite all efforts, the no-reflow phenomenon (NRP) may block coronary flow. In our study, we evaluated the predictive ability of leukocyte/glucose index for NRP.


**Method:** Our research is a retrospective analysis that involved patients treated with PPCI for ACS at our clinic. The average follow-up period was 498 days. We assessed the parameters significantly associated with NRP using Cox regression. ROC curve analysis determined the cut-off value, sensitivity, and specificity of independent predictive parameters that can predict NRP.

**Results:** Our study included 2279 patients who met the criteria. The average age of the patients was 64.1±13.1, and 75.5% were male. 68.7% of the patients had hypertension (HT), 18.6% had diabetes mellitus (DM), and 87.6 coronary artery disease (CAD), and 16.5% had heart failure (HF). It was observed that no-reflow developed in 2% of all patients (46 patients). Variables such as age, hemoglobin (Hb), platelet count, albumine, troponin, Leukocyte/glucose index showed a significant statistical association with NRP. Independent predictors of NRP identified in the multivariate regression analysis included age, troponin and Leukocyte/glucose index. The power of leukocyte/glucose index to predict NRP was observed to be better than age and the same as troponin.

**Conclusions:** Age, troponin and Leukocyte/glucose index were determined to be independent predictors in predicting NRP. We think that the Leukocyte/glucose index, a new marker derived from simple, useful and routinely used hematological and biochemical parameters, will contribute positively to the prognostic evaluation before PPCI.

**Keywords:** Acute Coronary Syndrome, No-reflow phenomenon, Primary percutaneous coronary intervention, Leukocyte/glucose index

### Receiver operating characteristic (ROC) curve analysis





# KARDİYOVASKÜLER AKADEMİ KONGRESİ

## & INTERNATIONAL ACADEMY OF YOUNG CARDIOLOGISTS

Elexus Hotel Girne, K.K.T.C.  
18-22 Eylül 2024

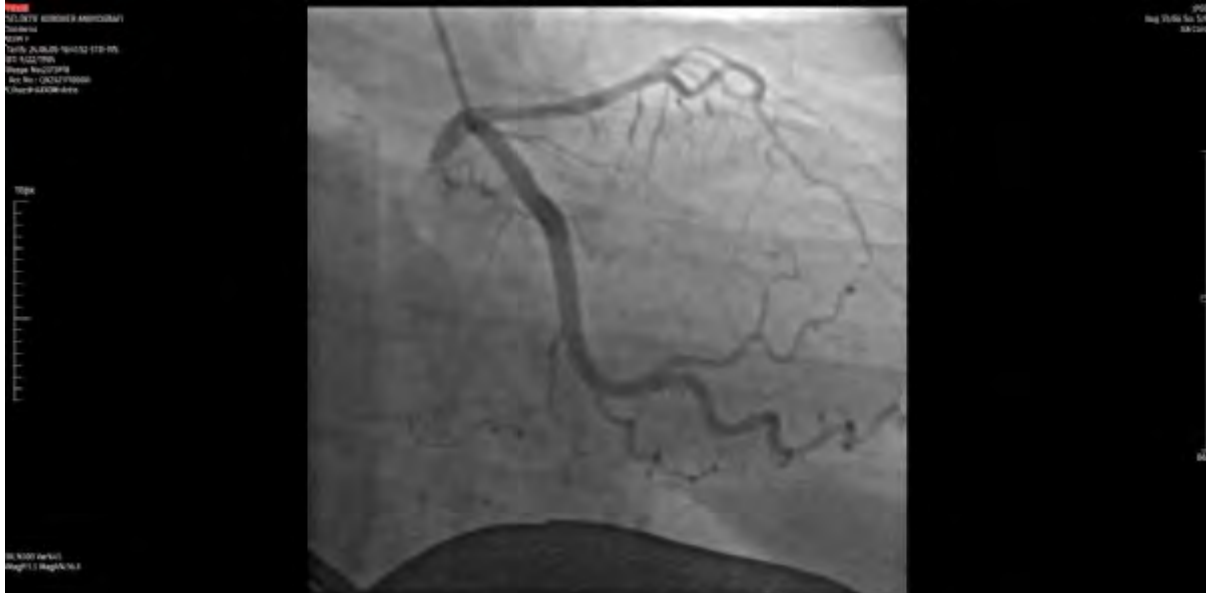### [OP-64] An Unpleasant Surprise During Pregnancy; Myocarditis or Ischemia?

Alihan Ayata, Aylin Safak Arslanhan, Sinan Saymaz, Cengiz Sabanoğlu  
UMRANIYE TRAINING AND RESEARCH HOSPITAL

39 years old female patient who was pregnant for 37 weeks admitted to E.R with chest pain. Vital parameters were normal. ECG revealed ST elevations on anterior derivations. On TTE; LVEF was %40 apical and anterior wall movement defects and moderate mitral regurgitation. Patient and her family informed with obstetrics and gynecology about the risks both for the fetus and mother in terms of C/S or CAG. After consent; patient was transferred to CAG laboratory; right radial way was used for arterial Access. CAG was normal except plaque formations which were seen on LAD. Patient 's follow-up continued in Coronary ICU for 2 days. Troponin levels were 72-617-350 ng/L at the next days. On third day patient went into labor emergency C/S was done by ObS and gyn under the antiagregan therapy. A completely healthy baby was delivered and the mother extubated successfully after the surgery. After patient's follow up completed in ICU; a CMR planned. CMR shown enhancement consistent with myocarditis. After that patient discharged with medical therapy. Patient came to the 1st month control after discharge; she had no symptoms; LVEF was %50-55 on control TTE and mitral regurgitation was mild.

**Keywords:** pregnancy, anterior st segment elevation, cardiac mri, myocarditis

cag

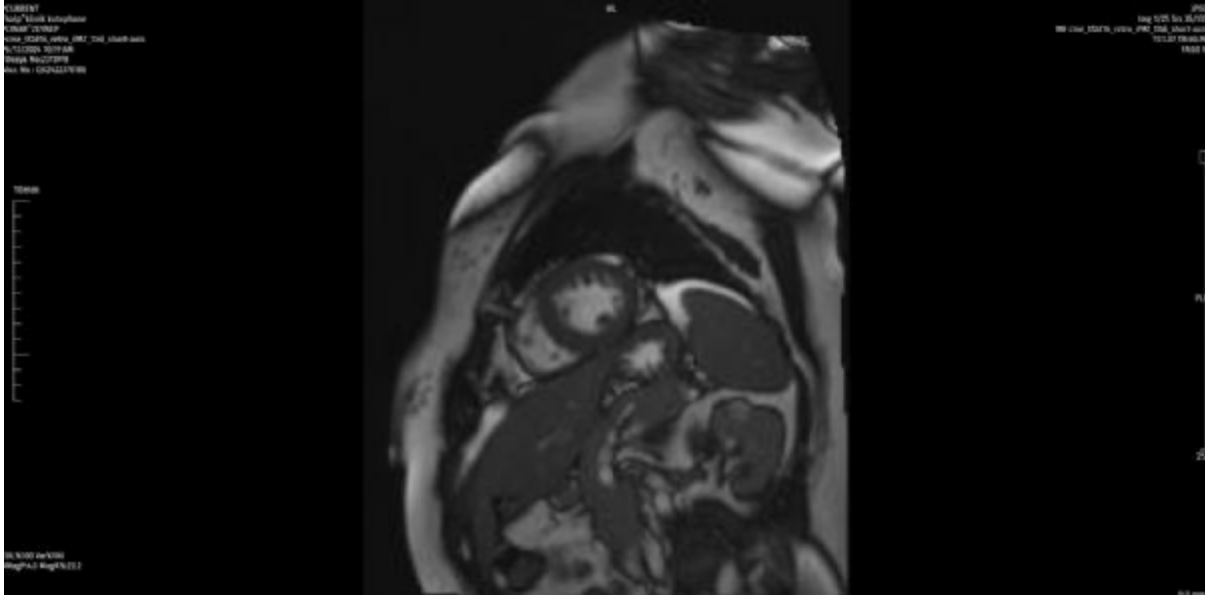


# KARDİYOASKÜLER AKADEMİ KONGRESİ

## & INTERNATIONAL ACADEMY OF YOUNG CARDIOLOGISTS

Elexus Hotel Girne, K.K.T.C.  
18-22 Eylül 2024

### cardiac mri



*non-ischaemic contrast enhancement on LV basal-mid superolateral segment*

**AuthorToEditor:** PAMI (Pregnancy associated myocardial infarction) occurs in 2.8 to 8.1 per 100 000 pregnancies. Which is 3-4 times higher than same age reproductive women. The incidence of PAMI is increasing and may relate to improved case detection and greater numbers of older women with underlying cardiovascular risk factors becoming pregnant. But there is no current literature about myocarditis (which is among the differential diagnosis) incidence on this group



# KARDİYOVASKÜLER AKADEMİ KONGRESİ

## & INTERNATIONAL ACADEMY OF YOUNG CARDIOLOGISTS

Elexus Hotel Girne, K.K.T.C.  
18-22 Eylül 2024

### **[OP-65] Left ventricular remodeling in patients with severely reduced ejection fraction undergoing revascularization considering myocardial viability**

Galib Imanov, Yasmin Rustamova, Shahin Khalilov, Isfendiyar Ismayilov, Vasadat Azizov  
*Azerbaijan Medical University, Baku, Azerbaijan*

**Background:** The main problem for patients with ischemic heart failure is the selection of treatment strategy based on the dynamics of the left ventricular remodeling parameters, which plays a crucial role in the prognosis of survival and quality of life. The benefit of myocardial viability detection remains controversial. The aim of the study was to compare the left ventricular remodeling parameters in patients with LVEF<35% undergoing revascularization both with CABG and PCI considering myocardial viability.

**Methods:** A total of 416 patients (mean [SD] age 63,55 (10,4) years for group I and 68,40 [12,6] for group II with LVEF<35% were enrolled. Left ventricular (LV) remodeling parameter assessed by transthoracic echocardiography were compared between two treatment groups, depending on the presence of myocardial viability using CMR. In group I revascularization (both CABG and PCI) was guided by the presence of viability. Group II was retrospective without viability assessment.

**Results:** In a total of 388 patients, the follow-up was on 24 months. In group I a significant decrease in the average values of LV end-diastolic, end-systolic volume (LVEDV, LVESV) and end-systolic diameter (LVEDD) was observed by the 18th month of observation and maintained this trend till 24 months (LVEDV 151,1±12,15ml at discharge vs 143,8 ± 9,01ml in 18 months, p = 0,0009; 137,5 ± 6,6 (p=0,0001) in 24 months. LVESV was 80,5 ± 8,07ml at discharge vs 77,5 ± 5,66 ml (p = 0,05) in 18 months and 73,47 ± 3,81ml (p=0,0001) in 24 months. The process of LV remodeling in patients of group II was slower and, ultimately, in many parameters no significant reduction was obtained compared with the data at the discharge. LVEDV was 158,8 ± 17,85 ml at discharge vs 151,7 ± 16,29 ml in 18 months, p>0,05; 146 ± 16,04 ml in 24 months (p = 0,0001). LVESV was 81,6 ± 7,87ml at discharge vs 78,6 ± 5,69 ml in 18 months p>0,05; 76,1 ± 5,39 in 24 months, p>0,05.

**Conclusion:** These findings substantiate the importance of myocardial revascularization in patients with severely reduced ejection fraction in the prevention of negative left ventricular remodeling, especially in the presence of viable myocardium.

**Keywords:** revascularization, remodeling, myocardial viability, CMR



# KARDİYOVASKÜLER AKADEMİ KONGRESİ

## & INTERNATIONAL ACADEMY OF YOUNG CARDIOLOGISTS

Elexus Hotel Girne. K.K.T.C.  
18-22 Eylül 2024

### **[OP-67] Successful LBBAP Therapy by Stylet-driven Ingevity lead for Complete Trifascicular Block in Ischemic HFmrEF patient: A case report**

Yakup Yunus Yamanturk, Ozgun Demiroglu  
*Cardiology Department, Artvin State Hospital, Turkey*

**Introduction:** Left Bundle Branch Area Pacing (LBBAP) is a recommended conduction system pacing method in recent years for patients requiring permanent pacing who also have a left ventricular ejection fraction of less than 50%. In recent years, various specialized implantation systems and leads for LBBAP have been developed. Various methods and leads have been developed for performing conduction system pacing/Left Bundle Branch Area Pacing (LBBAP) without the need for a specialized implantation system.

#### **CASE PRESENTATION**

An 82-year-old male patient with a known history of anterior STEMI presented to our clinic for routine follow-up. During the outpatient evaluation, his LVEF was measured at 45% (by transthoracic echocardiography - Biplane Simpson method). The ECG revealed an incomplete trifascicular block, and given that the patient was asymptomatic, a Holter ECG examination was planned. The patient was advised to seek medical attention in case of syncope and was managed with optimization of medical therapy and scheduled for follow-up.

One week later, the patient presented to the emergency department following a syncopal episode. The admission ECGs showed evidence of advanced/complete AV block. A decision was made to proceed with direct permanent pacemaker implantation. A Stylet-driven Ingevity lead was advanced through the left axillary vein towards the septal posterior of the right ventricle, targeting the septum. Pre-implantation pacing revealed a left anterior fascicular block morphology similar to the baseline ECG, with an R wave measurement of 9 mV (Figure 1,2). Thereafter, active lead fixation was performed. After atrial lead implantation, subsequent measurements showed ideal and stable R wave and pacing threshold values. The leads were screwed and the pulse generator was implanted in pocket. After thorough washing of the pacemaker pocket and application of antibiotics, the pocket layers and skin were sutured. The procedure was completed without complications.

#### **DISCUSSION AND CONCLUSION**

LBBAP (Left Bundle Branch Area Pacing) is emerging as an ideal permanent pacing method for patient populations requiring pacing with low or anticipated declining LVEF. Our case demonstrates that successful lead fixation to the LBB/LAF/LPF region can be achieved without the need for a specialized implantation system by adjusting the stylet curve in stylet-driven leads. The increasing development and dissemination of implantation techniques that reduce system dependency may contribute to more frequent use of LBBAP among cardiac pacing practitioners.

**Keywords:** conduction system pacing, ischemic cardiomyopathy, left bundle branch, syncope, trifascicular block

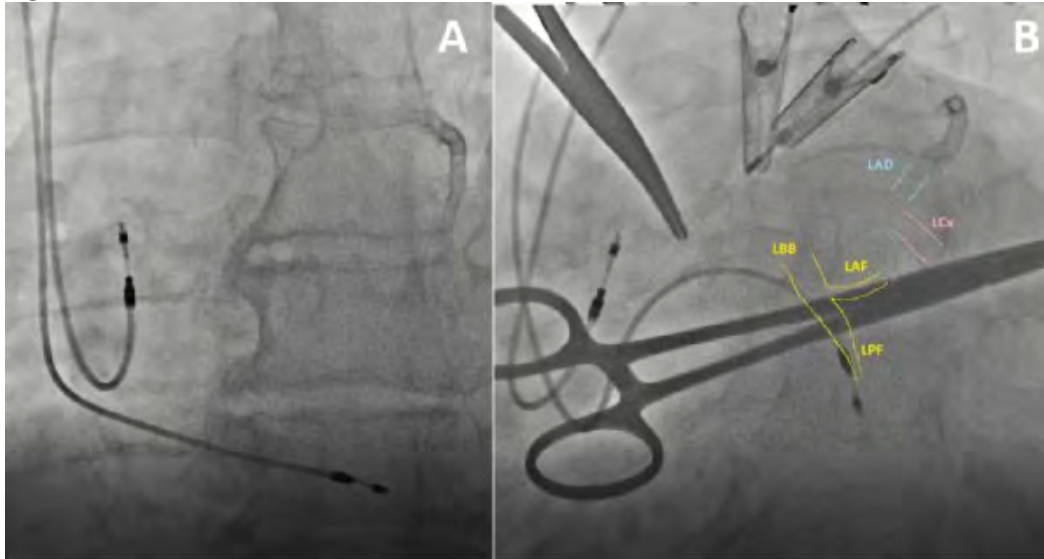


# KARDİYOVASKÜLER AKADEMİ KONGRESİ

## & INTERNATIONAL ACADEMY OF YOUNG CARDIOLOGISTS

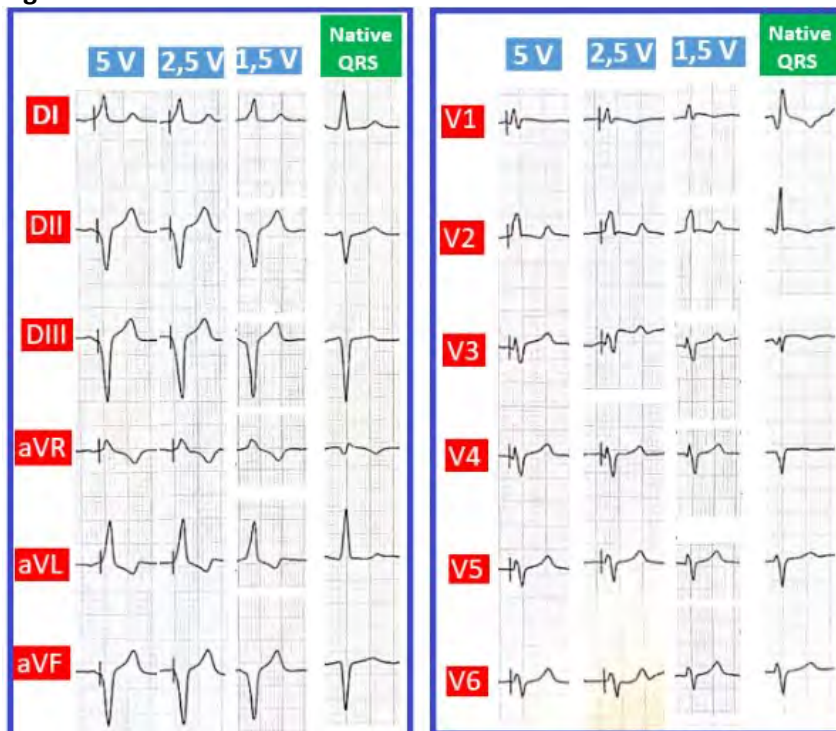
Elexus Hotel Girne, K.K.T.C.  
18-22 Eylül 2024

Figure 1



A. DR pacemaker lead is observed in AP neutral angulation position. B. Ingevity lead is fixed to the septum posterior in caudal angulation, specifically capturing the Left Posterior Fascicle of the LBB."

Figure 2



Pacing output - selective conduction pacing checking test from surface EGM



# KARDİYOVASKÜLER AKADEMİ KONGRESİ

## & INTERNATIONAL ACADEMY OF YOUNG CARDIOLOGISTS

Elexus Hotel Girne, K.K.T.C.  
18-22 Eylül 2024

### [OP-68] Unforeseen Beneficial Effect of Successful PVC Ablation: Achieving Migraine Attack Control Without Medication

Yakup Yunus Yamanturk<sup>1</sup>, Muhammed Emin Teker<sup>2</sup>, Gozde Cansu Yilmaz<sup>2</sup>, Muge Akbulut<sup>2</sup>, Basar Candemir<sup>2</sup>

<sup>1</sup>Cardiology Department, Artvin State Hospital, Turkey

<sup>2</sup>Cardiology Department, Ankara University, Ankara, Turkey

**Introduction:** Migraine is a primary headache disorder characterized by recurrent moderate to severe headaches, and circulatory changes are known to occur during migraines. However, the relationship between this finding and transient heart dysfunction is still unknown. Individuals with migraines have an increased risk of atrial fibrillation, myocardial infarction, and cardiovascular death compared to non-migraineurs. Another mechanism under debate regarding the pathophysiological relationship between migraine and cardiovascular diseases is the presence of a patent foramen ovale (PFO). This case pertains to a patient with PFO who had complete resolution of migraine attacks after premature ventricular contraction (PVC) ablation.

**Case:** A 52-year-old male with a history of migraine, essential hypertension, hyperlipidemia, and CAD presented to our clinic with complaints of palpitations and exertional dyspnea. Transthoracic echocardiography revealed globally depressed left ventricular (LV) systolic function and also patent foramen ovale (PFO). Holter-ECG monitoring documented 39,000 PVCs/24hr.

On the grounds that the patient's symptomatic PVCs, CAD risk factors, a coronary angiography and invasive electrophysiology study were planned. Coronary angiography revealed a non-critical 50-60% stenosis in proximal left anterior descending (LAD) artery (Figure 1,2). Following coronary angiography, the electrophysiology study proceeded to map the highly frequent monomorphic PVCs. The PVCs were found to originate from LV summit region, with earliest activation localized to left coronary cusp (LCC). Radiofrequency (RF) ablation was performed at both supraventricular and infraventricular LCC sites, resulting in successful termination of the PVCs (Figure 3).

Post-ablation follow-up echocardiograms and nuclear cardiac imaging ( Cardiac SPECT and MUGA) scans demonstrated normalization of LV ejection fraction (LVEF) to 60-65%, and the LAD stenosis was found not to cause significant ischemia (Figure 4-6). Notably, Holter-ECG monitoring at 1 month and 1 year post-ablation revealed a PVC burden of <0.1%, and the patient's cardiac symptoms completely resolved. Interestingly, it was also observed that migraine attacks were vanished 6 months after catheter ablation, and the patient no longer required migraine medical therapy.

**Conclusion:** The pathophysiology of migraine development related to PFO can be summarized as transient hypoxia-induced cerebral damage and paradoxical microthromboembolic events due to right-to-left paradoxical shunting. Our case highlights the effectiveness of catheter ablation for the treatment of frequent PVCs in patients with tachycardiomyopathy and a history of migraine headaches. Studies emphasizing the correlation between left ventricular systolic dysfunction and an increase in migraine attacks could support this

hypothesis. But definitive causative mechanisms linking PVCs and migraine headaches still need to be demonstrated by randomized trials.

**Keywords:** Catheter Ablation, Migraine, Premature Ventricular Contractions, Patent Foramen Ovale, Tachycardiomyopathy

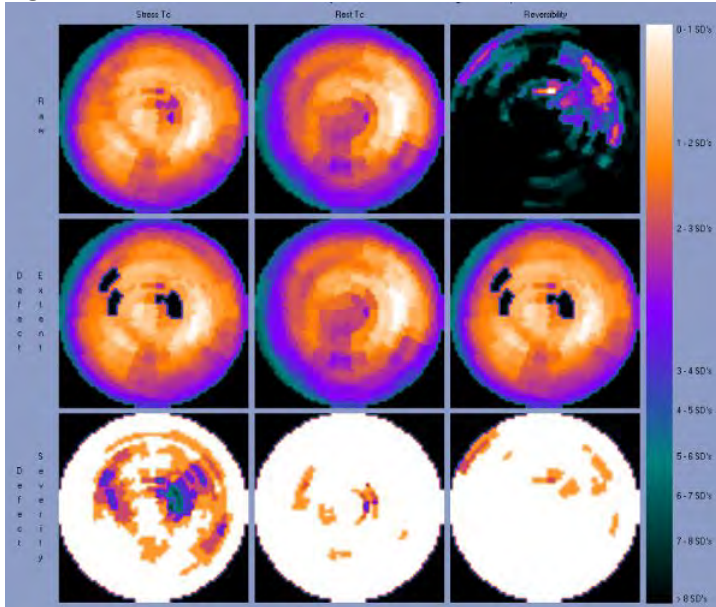


# KARDİYOVASKÜLER AKADEMİ KONGRESİ

## & INTERNATIONAL ACADEMY OF YOUNG CARDIOLOGISTS

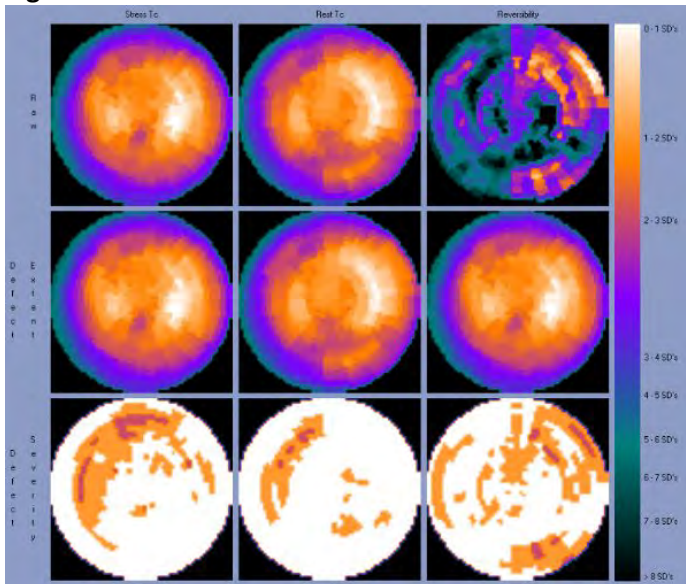
Elexus Hotel Girne, K.K.T.C.  
18-22 Eylül 2024

**Figure 4**



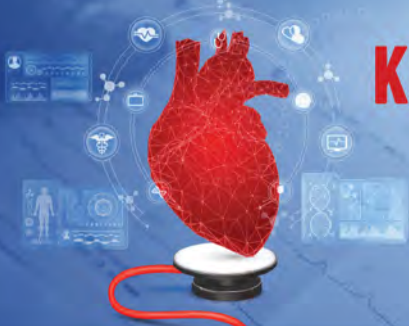*Polar map of Tc-99m sestamibi myocardial perfusion scintigraphy performed pre-ablation: LVEF was measured at 25%, and no ischemia was noted in the LAD territory*

**Figure 5**



*Polar map of Tc-99m sestamibi myocardial perfusion scintigraphy performed post-ablation: LVEF was calculated to be 65%.*

**AuthorToEditor:** We have all figures that mentioned in case description part but because of submission system restriction we have uploaded only Figure 4,5. Best Regards Dr Yamanturk



# KARDİYOVASKÜLER AKADEMİ KONGRESİ

## & INTERNATIONAL ACADEMY OF YOUNG CARDIOLOGISTS

Elexus Hotel Girne, K.K.T.C.  
18-22 Eylül 2024

### [OP-69] Effects of prosthetic heart valve-associated subclinical intravascular hemolysis on endothelium and cardiovascular system: a retrospective cohort study

Yakup Yunus Yamanturk<sup>1</sup>, Cagdas Ozdol<sup>2</sup>, Kerim Esenboga<sup>2</sup>, Demet Menekse Gerede Uludag<sup>2</sup>

<sup>1</sup>Cardiology Department, Artvin State Hospital, Turkey

<sup>2</sup>Cardiology Department, Ankara University, Ankara, Turkey

**Background:** Mechanical prosthetic heart valve implantation is a surgical treatment method used in the treatment of severe and symptomatic valvular disease. Regular follow-up of prosthetic valve functions, clinical and laboratory parameters is of great importance in patients who have undergone valve implantation. Chronic subclinical intravascular hemolysis is frequently seen in this patient group, but its management and long-term adverse effects are uncertain. In this study, it was aimed to determine the effects of subclinical hemolysis on the endothelium by comparing the frequency of clinical events such as pulmonary hypertension and atherosclerotic vascular events in patients with mechanical valves.

**Methods:** In this single-center, retrospective cohort, patients with functional mechanical prosthetic valves were evaluated. A total of 346 patients who underwent aortic and/or mitral valve replacement were included in the study according to the inclusion and exclusion criteria. The severity of mechanical intravascular hemolysis (MIH) in patients was evaluated based on serum lactate dehydrogenase (LDH) levels measured during follow-up after valve implantation. The study population was divided into two groups according to the median follow-up LDH value (fLDH) of 264.5 U/L: non-hemolysis/mild hemolysis (Group 1) and moderate hemolysis (Group 2). Study patients were evaluated for pulmonary hypertension (PHT) and major adverse cardiovascular events (MACE) during the retrospective follow-up period.

**Results:** The mean age of the study patients was 57.5±12.5 years, and the study population consisted of 65% male patients. The mean follow-up period of the patients was 9.4 years (±3.3). MACE (composite of non-fatal cerebrovascular event, myocardial infarction, new-onset arrhythmia, cardiovascular death, and elective coronary revascularization) were observed in 5.2% (n=18) of the study population. New-onset PHT was detected in 122 patients (35.3%) during follow-up period. When compared in terms of MACE, 1 event (0,6%) occurred in group 1, while 17 events (9,8%) occurred in group 2 (p<0.001). In the multivariate analysis performed with logistic regression method to determine statistical significance of the parameters that stand out in terms of MACE prediction, fLDH value  $\geq 265$  and having DM were found to be statistically significant variables (fLDH; OR = 37.18, 95% CI: 3.24-426.35, p=0.004, DM; OR = 27.14, 95% CI: 1.22-601.72, p=0.037).

**Conclusion:** The results of the study show that subclinical intravascular hemolysis in prosthetic heart valve patients may be associated with the development of MACE and PHT. Evaluation of the severity of hemolysis, which can be evaluated by LDH level in routine clinical practice, can be a prognostic factor in this patient group and may contribute to the appropriate management and treatment of patients.

**Keywords:** intravascular hemolysis, lactate dehydrogenase, MACE, mechanical prosthetic heart valve, pulmonary hypertension

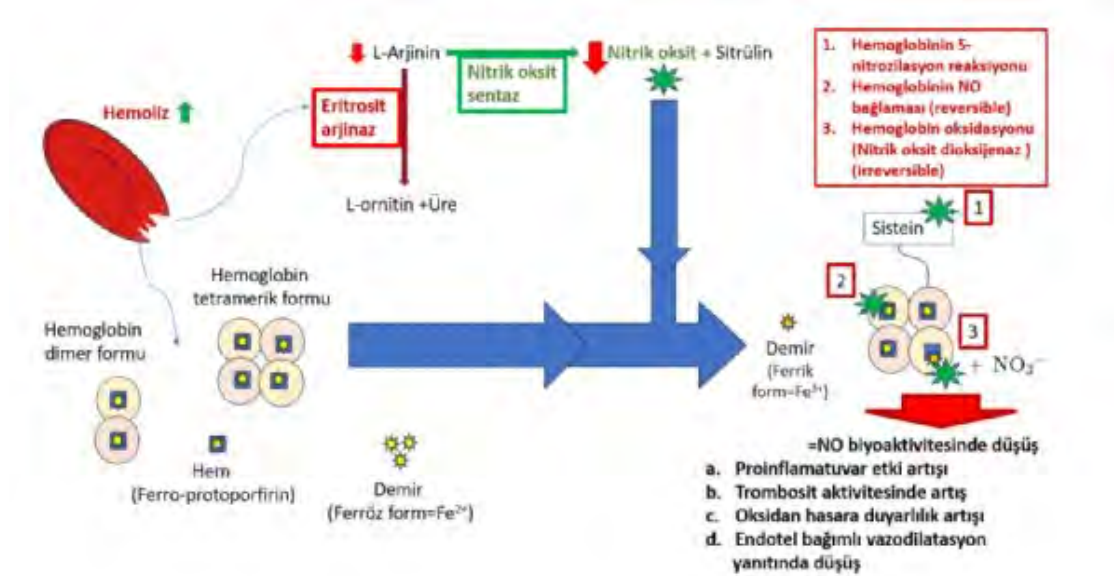


# KARDİYOVASKÜLER AKADEMİ KONGRESİ

## & INTERNATIONAL ACADEMY OF YOUNG CARDIOLOGISTS

Elexus Hotel Gime, K.K.T.C.  
18-22 Eylül 2024

Figure 1



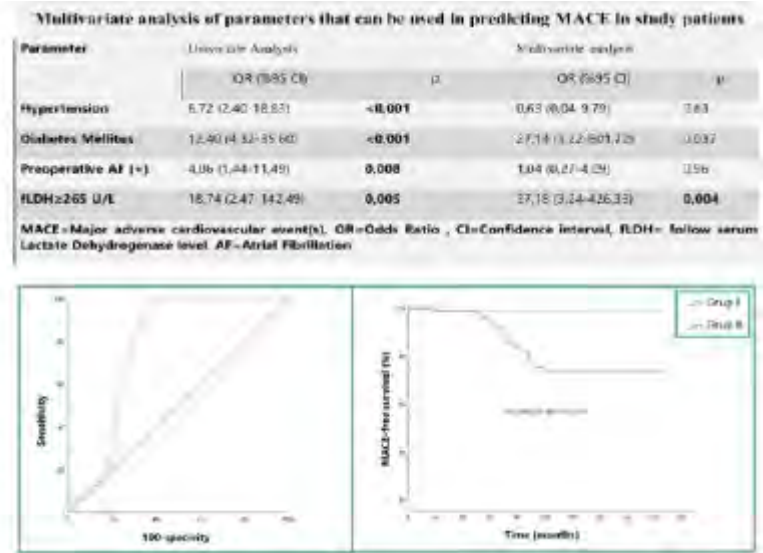
Pathophysiology of intravascular hemolysis

Figure 2

Table 1. Baseline clinical and demographic characteristics of study patients

Parameter	Study (n=340)	ELITE-2a5 (n=175)	ELITE-2a2 (n=175)	P Value
Gender, M (n, %)	225 (66.2)	109 (62.2)	116 (66.3)	<0.001
Age (years) (SD)	72 (14.1)	74 (14.1)	70 (14.1)	0.48
Body Mass Index (kg/m <sup>2</sup> )	23.4 (23.4-24.8)	24.3 (23.1-25.7)	24.2 (23.3-26.9)	0.001
Body Surface Area (m <sup>2</sup> )	1.89 (1.87-2.04)	1.89 (1.84-2.11)	1.8 (1.87-2.04)	<0.001
Arterial Hypertension (n, %)	82 (24.1)	37 (21.1)	45 (25.7)	0.001
Diabetes Mellitus (n, %)	40 (11.8)	24 (13.8)	16 (9.2)	0.18
Hyperlipidemia (n, %)	48 (14.1)	4 (2.2)	4 (2.2)	<0.001
History of Coronary Artery Disease (n, %)	14 (4.1)	1 (0.6)	13 (7.4)	0.238
Smoking (n, %)	19 (5.6)	1 (0.6)	18 (10.3)	0.001
Preoperative LVEF measurement (%)	65.2 (5.7)	62.3 (5.1)	60.2 (4.1)	<0.001
Low LVEF measurement (%)	40.3 (11.8)	35 (19.7)	48 (27.4)	<0.001
Stroke/Myocardial infarction (n, %)	122 (35.9)	52 (29.7)	70 (39.9)	0.18
Diastolic blood pressure (mmHg) (n, %)	70 (20.6)	18 (10.3)	52 (29.7)	0.01
Follow-up ECG Rhythm (n, %)				<0.001
SR	24 (7.1)	1 (0.6)	17 (9.7)	
AF	82 (24.1)	34 (19.4)	48 (27.4)	

AF= Atrial Fibrillation, SR= Sinus Rhythm, LVEF=Left Ventricular Ejection Fraction, SR= Sinus Rhythm.



Important tables of study



# KARDİYOVASKÜLER AKADEMİ KONGRESİ

## & INTERNATIONAL ACADEMY OF YOUNG CARDIOLOGISTS

Elexus Hotel Girne. K.K.T.C.  
18-22 Eylül 2024

### [OP-70] How We Managed An Acute İschemic Stroke Event During Tavi Procedure

Abdulla Arslan<sup>1</sup>, Oyku Gulmez Ozkaya<sup>2</sup>, Omer Kozan<sup>2</sup>

<sup>1</sup>Anadolu Hospital/İstanbul

<sup>2</sup>Baskent University Hospital

Cerebrovascular accidents including stroke or transient ischaemic attack are one of the most feared complications after transcatheter aortic valve implantation. During the our TAVI procedure, ischemic cerebral accident happened and in two hours, the arterial embolization and arterial occlusion treated with embolectomy procedure. As of now, there is not any case presented before.

Keywords: Acute ischemic event, cerebral intervention, TAVI

**Case:** 73 year old woman patient with severe aortic stenosis, admitted to hospital with decompensated heart failure. With diuretic therapy and getting the patient to compensated situation, echocardiography had been done: AVA: 0,6cm<sup>2</sup> with 61/36 mmhg gradients measured. After preprocedural preparation we took the patient to catheter laboratory for TAVI with STS 7,6 Euro II scores:8,7. Procedure was performed superficial anesthesia, the aortic valve predilated with 18number aortic balloon and then we implanted 23 number edwards aortic bioprothesis valve. After the succesful of implantation the aortic valve the patient had been taken to the care unit. After one hour, the patient evaluated by neurologist because of right hemiparesia, tendency to sleep and afasia. Serebral computer tomography and carotid angiography examinations were performed. There was a sign of occluded left internal carotid artery. The patient has been got to the cath library fort he carotid intervention, in 2hours from the symptoms had started. The left ICA was crossed with a wire, the thrombus was removed with thrombectomy, and the flow was observed to progress again. After this procedure patient evaluated in every 6hours via neurologist. And clinic defects such as tendency to sleep, afasia and right hemiparesia regressed. The patient began to speak normally, his consciousness returned to normal. Right extremity movements returned to normal. The patient discharged after two days from the procedure in a completely healthy condition.

**Discussion:** The possibility of experiencing ischemic events in complex procedures such as TAVI is still a serious problem. In the event of this problem, performing these procedures in centers that can quickly investigate the etiology and perform appropriate therapeutic procedures can minimize possible complications.

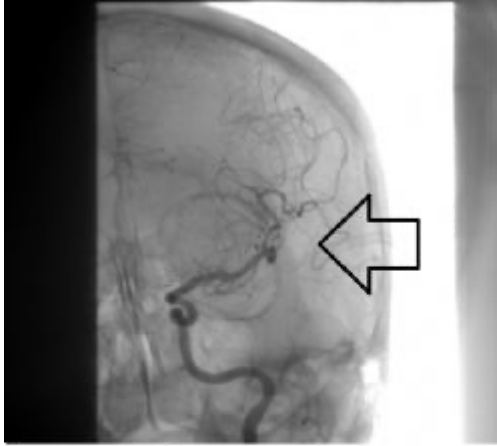Keywords: Acute ischemic event, cerebral intervention, TAVI

# KARDİYOVASKÜLER AKADEMİ KONGRESİ

## & INTERNATIONAL ACADEMY OF YOUNG CARDIOLOGISTS

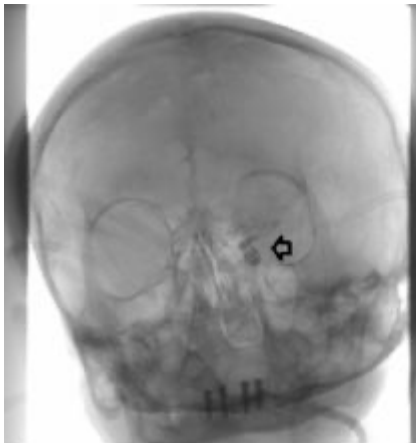Elexus Hotel Girne, K.K.T.C.  
18-22 Eylül 2024

arterial trace with open flow



*shows the flow that after trombektomi*

total occluded



*shows the occluded artery*



# KARDİYOVASKÜLER AKADEMİ KONGRESİ

## & INTERNATIONAL ACADEMY OF YOUNG CARDIOLOGISTS

Elexus Hotel Girne, K.K.T.C.  
18-22 Eylül 2024

### [OP-71] Can Annual Follow-Ups Replace Biannual Visits for DOAC Therapy? Insights from the COVID-19 Era?

Özge Çetinarslan<sup>1</sup>, Kemal Engin<sup>2</sup>, Ekin Günay<sup>1</sup>, Nihan Turhan<sup>3</sup>, Said Mesut Doğan<sup>2</sup>

<sup>1</sup>TC Demiroğlu Bilim Üniversitesi, İstanbul Florence Nightingale Hastanesi

<sup>2</sup>İstanbul Üniversitesi, Cerrahpaşa, Kardiyoloj Enstitüsü

<sup>3</sup>Bakırköy Sadi Konuk Eğitim ve Araştırma Hastanesi

**Background:** Adequate follow-up of patients on direct oral anticoagulants (DOACs) treatment is a debated clinical issue. Monitoring is predictable and less strict for patients on DOACs, who should be evaluated initially in the first month and then every six months regularly.

**Method:** The study was performed on 950 patients with non-valvular atrial fibrillation (AF) on DOACs treatment. Patients who continued their outpatient follow-up every six months between March 11, 2020, and March 11, 2021, were grouped as the regular follow-up group. Those who maintained outpatient controls at intervals longer than six months or never admitted to the hospital were called the irregular follow-up group. AF-related complications, including bleeding, stroke, and death, were questioned.

**Results:** Despite less frequent bleeding, death was more common in the irregular follow-up group. However, the composite endpoint of bleeding, stroke, and death was similar between the two groups.

**Discussion:** The results suggest that annual follow-up for patients using DOACs may be safe and effective rather than every six months, addressing that more flexible monitoring can be safe even outside of pandemic situations.

**Keywords:** Direct oral anticoagulants, DOACs, COVID-19, out-patient follow-up

**Table 1**

	n irregular	% irregular	n regular	% regular	p- value
major bleeding	3	0.6%	8	1.8%	0.000*
minor bleeding	7	1.4%	36	8.2%	0.000*
Death	42	8.2%	0	0	0.000*
Recent Stroke	1	0.2%	2	0.5%	0.598
Composite endpoint	53	10.3%	45	10.3%	0.975
Coronavirus infection	38	7.9%	57	14.4%	0.002*

*Comparison of management strategies of patients requiring direct oral anticoagulation therapy in the context of the current COVID-19 pandemic.*





# KARDİYOVASKÜLER AKADEMİ KONGRESİ

## & INTERNATIONAL ACADEMY OF YOUNG CARDIOLOGISTS

Elexus Hotel Girne, K.K.T.C.  
18-22 Eylül 2024

### **[OP-72] Successful Management Of Hyperacute Pseudoaneurysm of the Distal Superficial Femoral Artery**

Zeynep Esra Guner, Regayip Zehir

*KOŞUYOLU HIGH SPECIALIZATION EDUCATION AND RESEARCH HOSPITAL*

71-year-old male patient with diabetes mellitus presented to the outpatient clinic with intermittent claudication. On examination distal pulses were not palpable and resting ankle-brachial index measurement was low at 0.7 in the right leg. Claudication interfering with work or lifestyle did not improve despite medical treatment. Thus we decided to perform an endovascular intervention for this patient. First, we used contralateral transfemoral approach technique. A 0.035-inch guidewire was inserted to left femoral artery through the needle followed by a 6-Fr femoral introducer sheath. After achieving left femoral access, we crossed into the right iliac artery using an 0.035-inch wire with the help of a standard right Judkins catheter. We inserted the destination sheath on the right common femoral artery and we showed to establish anatomical stump on the femoral bifurcation. Peripheral angiography revealed total occlusion in the right superficial femoral artery (SFA) (Figure 1A). We detected the distal cap of the right SFA chronic total occlusion (Figure 1B). After the administration of heparin, we advanced a guidewire but guidewire could not penetrate the occluded SFA lesion antegradely. After failing the antegrade approach we decided to perform the crossing the total occlusion from retrograde access. Previous studies have demonstrated retrograde access more effective and safe. Under fluoroscopic guidance, we punctured the distal SFA. We approached retrogradely with standard 0.035 wire through dilator of 6Fr sheath into the distal cap of the occlusion. We performed retrograde balloon dilation with a 5.0 x 200 mm balloon in the distal cap of the occlusion. We crossed the distal SFA as antegradely and we confirmed true lumen below the distal cap. And we performed antegrade balloon dilation with balloon angioplasty a 4.0 x 100 mm balloon in the distal SFA through proximal SFA. Post-intervention angiography showed pseudoaneurysm of the distal puncture side (Figure 1C). We performed balloon inflation for 5 minutes but still pseudoaneurysm was continued (Figure 1D). We decided longer balloon inflation approximately 15 minutes but still pseudoaneurysm was not closed (Figure 1E). We punctured right common femoral artery antegradely and inserted the destination sheath. We implanted 5.0 \* 22 Advanta V12 graft stent via antegrade femoral approach and pseudoaneurysm was occluded completely (Figure 1F). Iatrogenic pseudoaneurysms that develop after interventional treatments can cause various complications such as rupture, distal embolization, local pain, and neuropathy. It often presents with a pulsatile mass after intervention. After diagnosis, there are treatment options such as manual compression, ultrasound guided compression, thrombin injection, and covered stenting. We wanted to highlight a rare case of pseudoaneurysm that developed hyperacutely in distal SFA and was treated with a graft stent in the same intervention procedure.

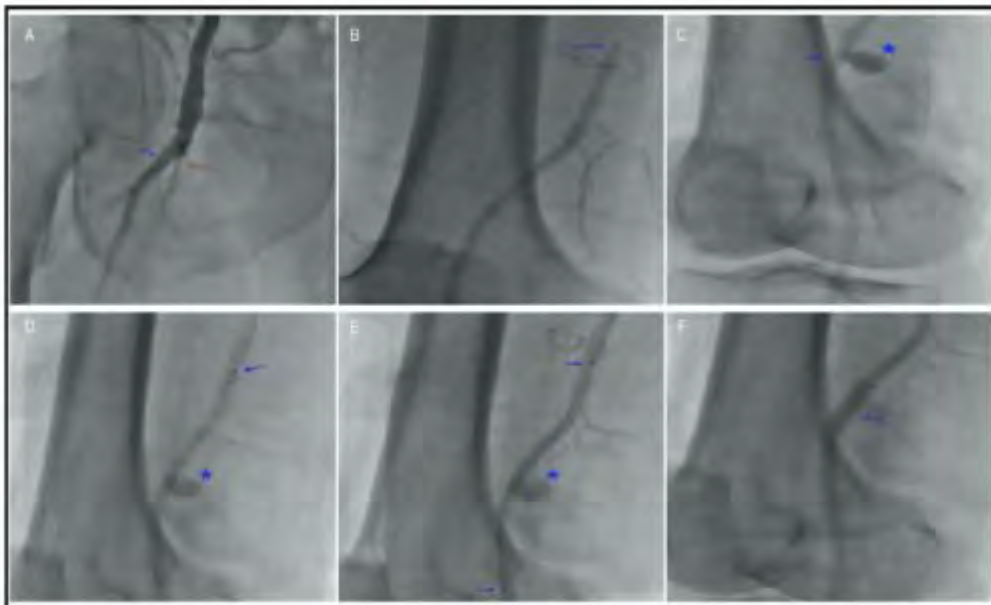
**Keywords:** peripheral arterial disease, pseudoaneurysm, graft stent

# KARDİYOVASKÜLER AKADEMİ KONGRESİ

## & INTERNATIONAL ACADEMY OF YOUNG CARDIOLOGISTS

Elexus Hotel Girne, K.K.T.C.  
18-22 Eylül 2024

Figure 1





# KARDİYOVASKÜLER AKADEMİ KONGRESİ

## & INTERNATIONAL ACADEMY OF YOUNG CARDIOLOGISTS

Elexus Hotel Girne. K.K.T.C.  
18-22 Eylül 2024

### [OP-73] Two Different Life-threatening Condition; Acute Coronary Syndrome and Trombocytopenia and as a Treatment Option Partial Splenic Embolization

Aysu Oktay<sup>1</sup>, Merve Kapçık<sup>2</sup>, Yusuf Yılmaz<sup>3</sup>, Murat Aşık<sup>4</sup>

<sup>1</sup>Aysu Oktay, Kardiyoloji, Birecik Devlet Hastanesi, Şanlıurfa, Türkiye

<sup>2</sup>Merve Kapçık, Kardiyoloji, Göztepe Süleyman Yalçın Şehir Hastanesi, İstanbul, Türkiye

<sup>3</sup>Yusuf Yılmaz, Kardiyoloji, Göztepe Süleyman Yalçın Şehir Hastanesi, İstanbul, Türkiye

<sup>4</sup>Murat Aşık, Radyoloji, Göztepe Süleyman Yalçın Şehir Hastanesi, İstanbul, Türkiye

**Introduction:** Coronary Artery Diseases (CAD) and malignancies are important causes of death in the world.

Thrombocytopenia is a common problem in cancer patients. One of the important causes of thrombocytopenia in cancer patients is venous thromboembolism (VTE). Splanchnic vein thrombosis (SVT) are a unique manifestation of VTE that involves one or more abdominal vessels. Patients with cancer who develop acute coronary syndromes (ACS) are less likely to receive timely coronary angiography or appropriate medical therapy. A multidisciplinary approach is recommended to guide treatment decisions in this high-risk and growing patient group.

**Case:** 74 years old male who has a history of colorectal carcinoma applied to emergency service with typical anginal symptoms.

While no significant change was detected in the ECG, the troponin level was found to be high above the upper limit. Pancytopenia was revealed. The patient was admitted to the coronary intensive care unit with the diagnosis of NSTEMI while increasing troponin level. Echocardiography revealed anterior wall hypokinesia and a reduced LVEF calculated 45%. An hypersplenism associated platelet destruction which caused by SVT that a complication of colorectal carcinoma considered and because of ongoing platelet destruction replacement of thrombocyte was not assumed as a treatment strategy. The first choice for the treatment was splenectomy with high surgery risk. Another treatment option which is PSE, that might improve the patient's thrombocytopenia by splenic volume reduction suggested, and a consensus formed for this option.

After 5 days of PSE, the platelet level are increased dramatically. The patient's platelet counts before the PSE were 36.000 and after five days of PSE the platelet counts is 160.000. Then the patient taken to coronary angiography on the fifth days of PSE. A subtotal lesion detected in the LAD artery, and any significant stenosis was seen in other epicardial coronary arteries. The coronary artery lesion crossed drug eluted stent was implanted.

**Discussion:** In cases of ACS without any contraindication for procedure, the patient is immediately taken to the catheter laboratory for coronary revascularization. Avoiding PCI when the patient's platelet count is 50,000/ $\mu$ L was recommended. In our cases, the high necessity of PCI with DAPT while thrombocytopenia was challenging situation.

There is a similar case report in the literature while our case presented with ACS. Studies implied PSE as a treatment option for thrombocytopenia in chronic coronary syndrome with acute congestive heart failure presentation. In this respect, our case study differs from other studies in the literature.

**Conclusion:** PSE is an option for treatment of thrombocytopenia with ACS. After other life-threatening conditions like ACS and high risk surgery discussed, patient must be evaluate with a multidisciplinary approach including hematology, general surgery, interventional radiology and cardiology.

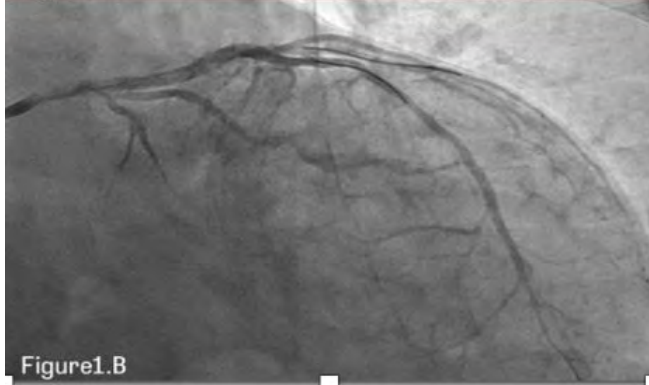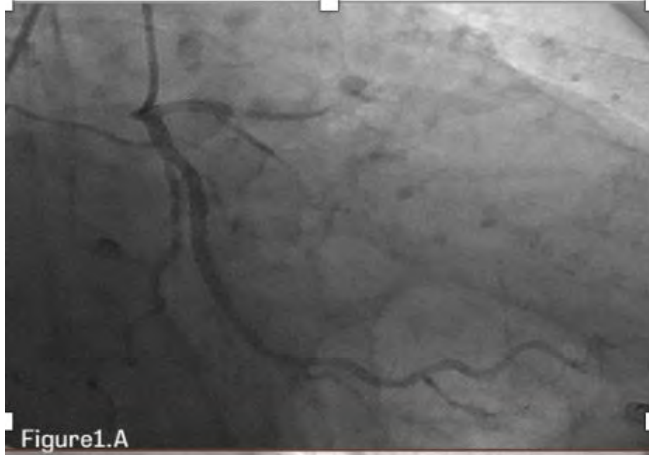**Keywords:** Partial Splenic Embolization, Trombocytopenia, Acute Coronary Syndrome

# KARDİYOVASKÜLER AKADEMİ KONGRESİ

## & INTERNATIONAL ACADEMY OF YOUNG CARDIOLOGISTS

Elexus Hotel Girne, K.K.T.C.  
18-22 Eylül 2024

### CAG



### Trombocyte level

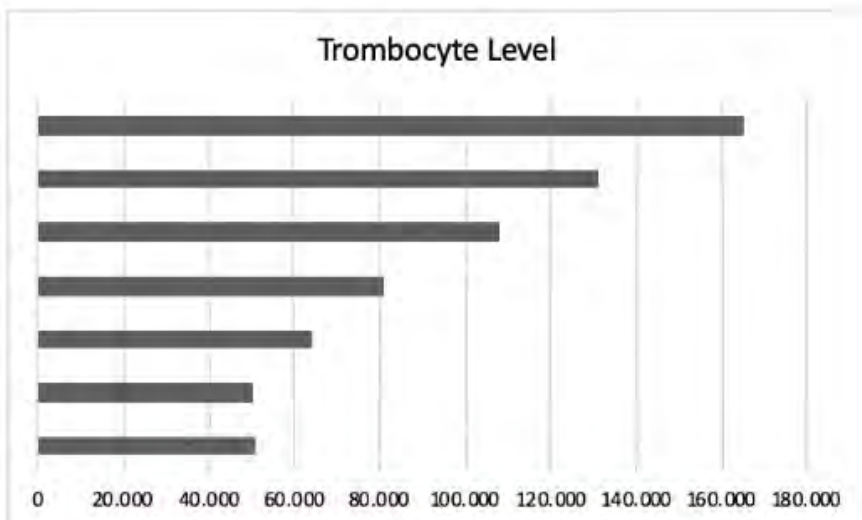


Table-1: Trombocyte level changes after partial splenic embolization.





# KARDİYOVASKÜLER AKADEMİ KONGRESİ

## & INTERNATIONAL ACADEMY OF YOUNG CARDIOLOGISTS

Elexus Hotel Girne, K.K.T.C.  
18-22 Eylül 2024

### **[OP-74] The predictive value of pan-immune-inflammation value (piv) for saphenous vein graft disease in post-coronary artery bypass grafting patients**

Zeki Çetinkaya

*Department of Cardiology, Elazığ Fethi Sekin City Hospital, Elazığ, Turkey*

**Background:** For patients with severe coronary artery disease (CAD) and high-risk profiles for percutaneous coronary intervention, coronary artery bypass grafting (CABG) continues to be the gold standard of care. Even though saphenous vein grafts (SVG) are used in CABG often, their patency rates are not as high as those of arterial grafts. Finding non-invasive ways to assess SVG patency is essential.

**Aims;** In post-CABG patients, this study examines the association between SVG patency and a novel inflammatory marker called Pan-Immune-Inflammation Value (PIV).

**Methods:** Between 2016 and 2023, 427 patients had coronary angiography (CAG) performed for clinical reasons; these patients were included in the study. Depending on whether or not SVG stenosis (SGVS) was present, patients who had undergone CABG at least a year earlier and had at least one SGV utilized were split into two groups.

**Results:** 204 out of the 527 patients had SVGS. Higher levels of diabetic mellitus and inflammatory markers such as NLR, SII, CAR, and PIV were seen in patients with SVGS. PIV was found to be an independent predictor of SVGS by multivariate analysis. A PIV cut-off value  $>313.5$  indicated SVGS with 76.2% sensitivity and 67.4% specificity (area under the curve (AUC) = 0.74 [95% CI: 0.68-0.78],  $p < 0.001$ ) according to ROC analysis. Similarly, for SII, a cut-off value of 470.7 predicted SVGS with 73% sensitivity and 60.2% specificity (AUC = 0.71 [95% CI: 0.67-0.77],  $p < 0.001$ ). In the case of CAR, a cut-off value of 0.95 demonstrated 70.9% sensitivity and 60.7% specificity in predicting SVGS among CABG patients (AUC = 0.68 [95% CI: 0.64-0.72],  $p < 0.001$ ) (Figure)

**Conclusion:** Strong prognostic value for SVGS was shown by PIV, an easy-to-measure and straightforward marker, in patients who had undergone CABG.

**Keywords:** Coronary artery bypass grafting, Saphenous vein graft stenosis, Pan-immune-inflammation value

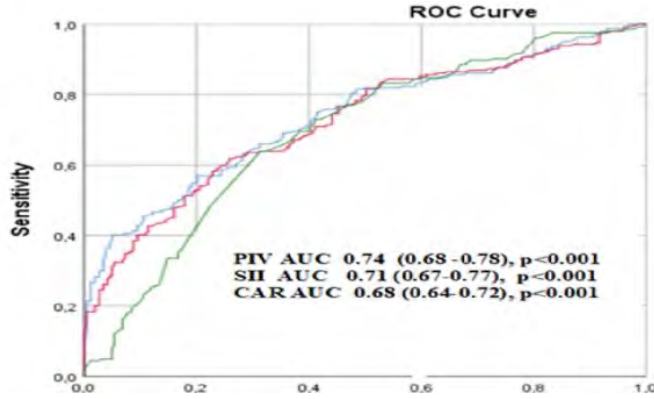
---

**Figure:** Receiver operating characteristic (ROC) curves for the pan-immune-inflammation value (PIV), systemic immune inflammation index (SII) and CRP / Albumin ratio (CAR) for predicting saphenous vein graft stenosis

# KARDİYOVASKÜLER AKADEMİ KONGRESİ

## & INTERNATIONAL ACADEMY OF YOUNG CARDIOLOGISTS

Elexus Hotel Girne, K.K.T.C.  
18-22 Eylül 2024



**Table 1. Demographic characteristics of the study population**

	Saphenous vein graft stenosis Presence (204)	Saphenous vein graft stenosis Absence (223)	p value
Age (years)	67.7±10.6	66.5±10.4	0.6
Male (n,%)	146 (%71.8)	137 (%61.6)	0.81
DM (n,%)	93 (%45.8)	80 (%36)	0.03
Dyslipidemia (n, %)	50 (%24.8)	40 (18)	0.21
Hypertension (n, %)	116 (%68.6)	148.7 (%66.7)	0.51
Smoking (n, %)	75(%36.5)	65 (%29)	0.34
Systolic blood pressure (mmHg)	124.7+14.6	123.8+14.2	0.2
Diastolic blood pressure (mmHg)	75.6+8.1	75.2+7.6	0.48
LVEF (%)	47.9±10.3	48.7±9.3	0.46
ASA	183 (%89.9)	194 (%87.2)	0.78
B-Blocker	169 (%83.3)	187 (%84.2)	0.7
ACEi.or ARB	157 (%77)	178 (%79.8)	0.46
Statins	129 (%63.3)	139(%62.2)	0.88
Clopidogrel	179 (%88.1)	188 (%84.3)	0.75

Values are expressed as n (%), median (interquartile range [IQR]), or mean ± standard deviation. P values were calculated using an independent samples t-test or the Mann-Whitney U-test for continuous variables, and a chi-squared test or Fisher's exact test for categorical variables, as appropriate. ACEi, Angiotensin Converting Enzyme Inhibitors, ARB, Angiotensin Receptor Blocker, DM, Diabetes Mellitus LVEF, left ventricular ejection fraction



# KARDİYOVASKÜLER AKADEMİ KONGRESİ

## & INTERNATIONAL ACADEMY OF YOUNG CARDIOLOGISTS

Elexus Hotel Girne. K.K.T.C.  
18-22 Eylül 2024

### **[OP-75] Evaluating the Naples Prognostic Score in Predicting Long-Term Mortality for Cancer Patients with ST-Elevation Myocardial Infarction**

Fatma Esin, Berkay Palaç

*Department of Cardiology, Izmir Atatürk Training and Research Hospital, Izmir, Türkiye*

**Background:** Cardiovascular diseases and cancer are leading causes of mortality worldwide. ST-Elevation Myocardial Infarction (STEMI) significantly increases prognostic uncertainties, especially in cancer patients. Understanding the long-term mortality risk in this group is crucial for improving clinical outcomes. The Naples Prognostic Score (NPS), which includes nutritional and inflammatory markers, may be particularly relevant in cancer patients who are at higher risk for adverse outcomes following STEMI.

**Objective:** This study aims to assess the NPS in predicting long-term mortality among cancer patients with STEMI.

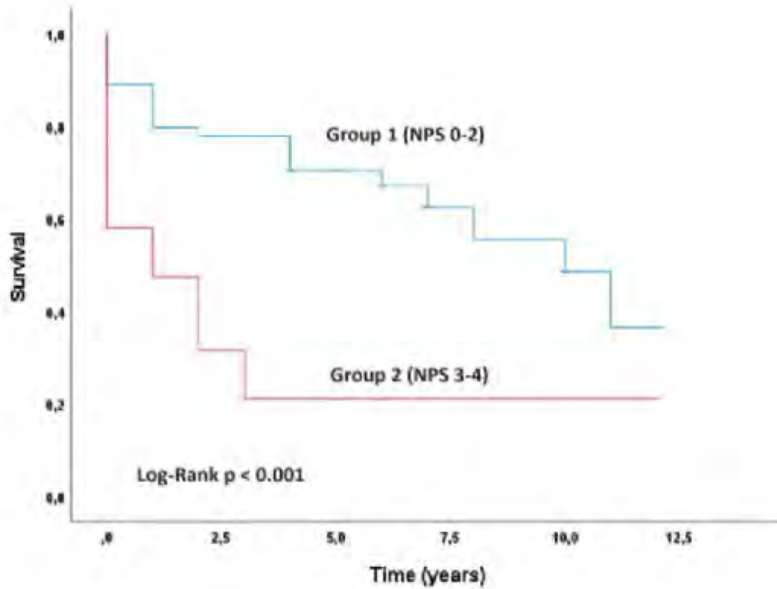
**Methods:** In this retrospective study, we analyzed the medical records of 73 cancer patients with STEMI between November 2009 and March 2018 at a tertiary education and research hospital. The study included patients who were diagnosed with cancer within six months before or after their STEMI diagnosis and received treatment in the oncology department. All patients underwent primary percutaneous coronary intervention. The NPS was calculated at the time of STEMI diagnosis by incorporating albumin levels, total cholesterol, lymphocyte-to-monocyte ratio (LMR), and neutrophil-to-lymphocyte ratio (NLR). A score of 1 was assigned for albumin levels  $<4$  g/dL, total cholesterol  $\leq 180$  mg/dL, LMR  $\leq 4.44$ , and NLR  $>2.96$ . Patients were categorized into Group 1 (NPS 0–2) and Group 2 (NPS 3–4). The primary endpoint was all-cause mortality. Outcomes were monitored over an average of 5 (1–6) years to assess mortality rates. Statistical analyses were performed using Cox regression models to assess the association between NPS and long-term mortality. Kaplan-Meier survival analysis and log-rank tests were used to compare survival curves. Continuous variables were compared using the Student's t-test, while categorical variables were analyzed using the chi-square test. A p-value of  $<0.05$  was considered statistically significant.

**Results:** The analysis revealed a statistically significant difference in long-term mortality rates between the groups defined by their NPS. Patients in Group 2 (NPS 3–4), indicating higher risk, had significantly higher mortality rates compared to Group 1 (NPS 0–2), with a Hazard Ratio (HR) of 2.78 (95% CI: 1.30–5.94,  $p = 0.008$ ). This finding highlights the strong predictive capacity of the NPS for long-term mortality. Kaplan-Meier survival analysis demonstrated a significant separation in survival curves between the two groups (log-rank test,  $\chi^2 p < 0.001$ ).

**Conclusion:** NPS is a robust predictor of long-term mortality in cancer patients with STEMI, underscoring the critical importance of assessing nutritional and inflammatory statuses in this patient population. These findings suggest that integrating the NPS into treatment protocols for cancer patients with cardiovascular conditions could improve the precision of prognostic evaluations and support more informed therapeutic decisions, ultimately leading to better patient outcomes.

**Keywords:** Cancer, inflammatory status, long-term mortality, Naples Prognostic Score, ST-Elevation Myocardial Infarction

**Figure 1**



*Kaplan-Meier Survival Curves by NPS Group. This figure shows the Kaplan-Meier survival curves for two groups based on the Naples Prognostic Score (NPS). Group 1 (NPS 0- 2) represents lower-risk patients, while Group 2 (NPS 3-4) represents higher-risk patients.*

**Table 1: Demographic, Clinical and Laboratory Findings of the Study Population**

Characteristic	Group 1 (NPS 0-2) (n=39)	Group 2 (NPS 3-4) (n=34)	P-value
Age (Years)	63.72± 12.29	64.29 ± 12.01	0.840
Gender (Male n %)	29 (74)	27 (79)	0.817
Diabetes mellitus (n %)	15 (38)	18 (53)	0.245
Hypertension (n %)	20 (51)	10 (29)	0.098
Stroke (n %)	2 (5)	4 (12)	0.547
Hyperlipidemia (n %)	4 (10)	7 (21)	0.339
COPD (n %)	5 (13)	3 (9)	0.718
Multivessel disease (n %)	18 (46)	22 (65)	0.116
Smoking (n %)	17 (44)	22 (65)	0.072
Killip class >2 (n %)	5 (13)	7 (21)	0.492
LV EF %	50.72 ± 10.29	49.29 ± 9.01	0.683
Beta blockers (n %)	31 (79)	23 (68)	0.315
ACE/ARB (n %)	32 (82)	29 (85)	0.729





# KARDİYOVASKÜLER AKADEMİ KONGRESİ

## & INTERNATIONAL ACADEMY OF YOUNG CARDIOLOGISTS

Elexus Hotel Girne, K.K.T.C.  
18-22 Eylül 2024

Statin (n %)	35 (90)	30 (88)	0.812
Acetylsalicylic Acid (n %)	38 (97)	31 (91)	0.511
Clopidogrel (n %)	26 (67)	24 (71)	0.915
Ticagrelor (n %)	9 (23)	7 (21)	1.000
Prasugrel (n %)	4 (10)	3 (9)	1.000
LMCA (n %)	2 (5)	1 (3)	0.658
LAD (n %)	15 (38)	12 (35)	0.759
CX (n %)	8 (21)	6 (18)	0.738
RCA (n %)	14 (36)	12 (35)	0.923
Lung Cancer (n %)	7 (18)	9 (26)	0.645
Breast Cancer (n %)	4 (10)	3 (9)	0.999
Prostate Cancer (n %)	5 (13)	1 (3)	0.214
Colorectal Cancer (n %)	4 (10)	5 (15)	0.739
Bladder Cancer (n %)	6 (15)	9 (26)	0.414
Others (n %)	13 (33)	7 (21)	0.208
All-cause Mortality (n %)	10 (26)	18 (53)	0.003
WBC ( $\times 10^9/L$ )	11.33 $\pm$ 3.95	12.37 $\pm$ 6.65	0.553
Hemoglobin (g/dL)	13.16 $\pm$ 2.82	12.32 $\pm$ 2.63	0.377
Neutrophils ( $\times 10^9/L$ )	6.54 $\pm$ 3.20	336.00 $\pm$ 1457.93	0.390
Lymphocytes ( $\times 10^9/L$ )	3.84 $\pm$ 2.14	1.57 $\pm$ 0.62	<0.001
Monocytes ( $\times 10^9/L$ )	0.60 $\pm$ 0.35	0.78 $\pm$ 0.57	0.283
Platelets ( $\times 10^9/L$ )	296.21 $\pm$ 66.29	279.18 $\pm$ 129.90	0.609
Total Cholesterol (mg/dL)	166.58 $\pm$ 27.31	157.95 $\pm$ 30.65	0.351
Albumin (g/dL)	3.55 $\pm$ 0.56	3.34 $\pm$ 0.54	0.263
GFR (mL/min/1.73m <sup>2</sup> )	103.55 $\pm$ 20.63	83.31 $\pm$ 30.59	0.189
NLR	4.15 $\pm$ 9.60	118.37 $\pm$ 521.90	0.347
LMR	7.27 $\pm$ 3.40	2.82 $\pm$ 1.36	<0.001
NPS	1.5 $\pm$ 0.7	3.4 $\pm$ 0.5	<0.001

*Abbreviations: COPD = Chronic obstructive pulmonary disease, LV EF = Left ventricular ejection fraction, ACE = Angiotensin-converting enzyme inhibitors, ARB = Angiotensin II receptor blockers, LMCA = Left main coronary artery, LAD = Left anterior descending artery, CX = Circumflex artery, RCA = Right coronary artery, WBC = White blood cell count, GFR = Glomerular filtration rate, LMR = Lymphocyte-to-monocyte ratio, NLR = Neutrophil-to-lymphocyte ratio, NPS = Naples Prognostic Score.*



# KARDİYOVASKÜLER AKADEMİ KONGRESİ

## & INTERNATIONAL ACADEMY OF YOUNG CARDIOLOGISTS

Elexus Hotel Girne. K.K.T.C.  
18-22 Eylül 2024

### [OP-76] Evaluation of Left Atrial Strain in Post COVID-19 Syndrome Patients with Persistent Dyspnea

Mesut Karatas<sup>1</sup>, Nursen Keles<sup>2</sup>, Kemal Emrehan Parsova<sup>3</sup>, Mehmet Baran Karatas<sup>2</sup>, Ali Nural<sup>2</sup>, Erkan Kahraman<sup>2</sup>, Cevdet Ugur Kocogullari<sup>4</sup>

<sup>1</sup>University of Health Sciences, Kartal Kosuyolu Yuksek Ihtisas Training and Research Hospital, Department of Cardiology, Istanbul, Turkey

<sup>2</sup>University of Health Sciences, Dr Siyami Ersek Thoracic and Cardiovascular Surgery Training and Research Hospital, Department of Cardiology, Istanbul, Turkey

<sup>3</sup>Koc University Hospital, Department of Cardiology, Istanbul, Turkey

<sup>4</sup>University of Health Sciences, Dr Siyami Ersek Thoracic and Cardiovascular Surgery Training and Research Hospital, Department of Cardiovascular Surgery, Istanbul, Turkey

**Background:** Even after recovering from COVID-19, many people still suffer persistent dyspnea for extended periods of time. Typically, conventional methods are unable to explain the dyspnoea. Long-term persistent dyspnoea in patients can be attributed to impaired left ventricular (LV) diastolic function and elevated LV end-diastolic pressure. The left atrium (LA) has a complex structure and plays a critical role in the cardiac cycle, particularly in the process of diastolic filling.

**Objectives:** The aim of this study was to compare the LA strain in patients who recovered from COVID-19 pneumonia but had persistent dyspnoea at 6 months with healthy volunteers.

**Methods:** A prospective observational cohort study included 66 COVID-19 pneumonia patients and 60 healthy individuals. Patients with specific cardiac and respiratory conditions were excluded. Echocardiography, including LA strain assessment, was performed using standard techniques. 4D LA strain assessment was used for the first time in this patient population.

**Results:** Results showed significantly lower LA 2D and 4D LA strain values in the patient group, indicating potential early signs of diastolic dysfunction. Other conventional echocardiographic parameters were comparable between groups. The study suggests that LA strain assessment may provide insights into early cardiac alterations in patients with persistent dyspnoea post-COVID-19 recovery.

**Conclusions:** These findings highlight the importance of long-term cardiac monitoring in COVID-19 survivors and the potential role of LA strain as an early marker of cardiac dysfunction in this population. Further studies with longer follow-up periods and invasive evaluations are warranted to validate these observations and guide clinical management strategies.

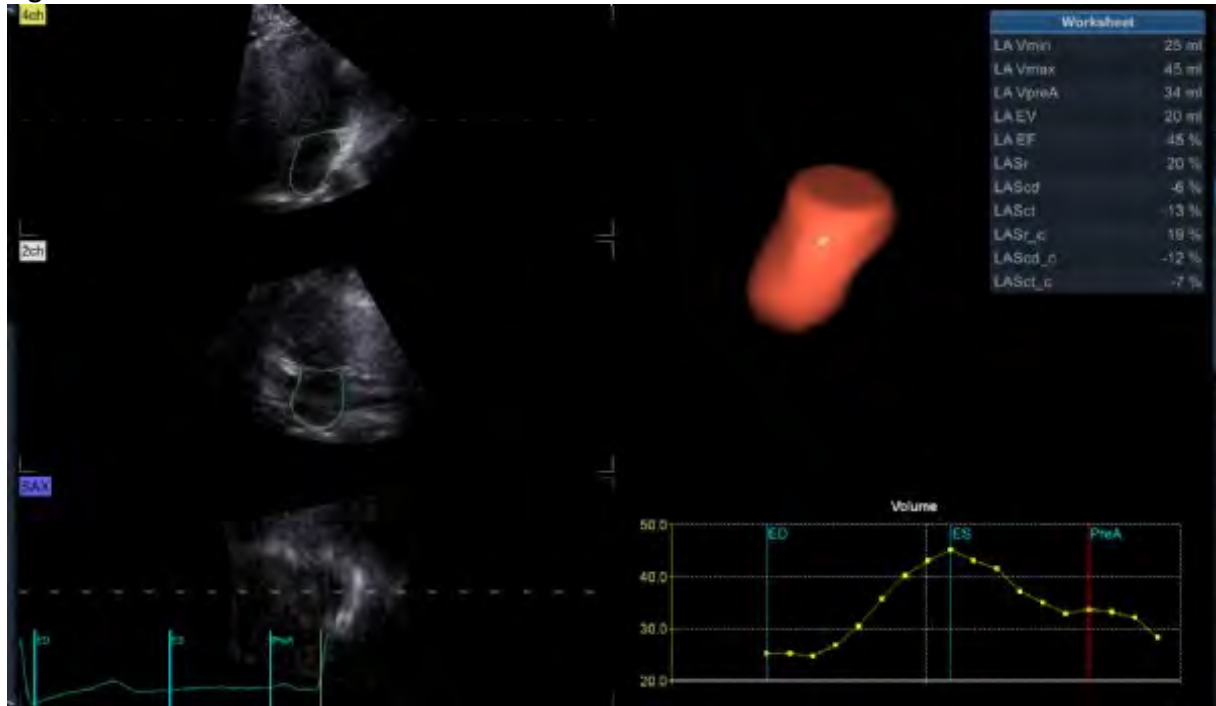
**Keywords:** Post COVID-19 syndrome, Long COVID-19 syndrome, left atrial strain, left atrial longitudinal strain, persistent dyspnea

# KARDİYOVASKÜLER AKADEMİ KONGRESİ

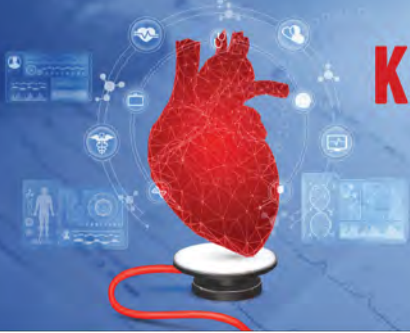## & INTERNATIONAL ACADEMY OF YOUNG CARDIOLOGISTS

Elexus Hotel Girne, K.K.T.C.  
18-22 Eylül 2024

Figure 1



Left atrial strain parameters measurement. 4D Auto LAQ instrument is used to measure the strain and volume curves of the LA.



# KARDİYOVASKÜLER AKADEMİ KONGRESİ

## & INTERNATIONAL ACADEMY OF YOUNG CARDIOLOGISTS

Elexus Hotel Girne, K.K.T.C.  
18-22 Eylül 2024

**Table 1**

**Table 1: Clinical characteristics and laboratory results.**

	Patient group (n=66)	Control group (n=60)	p value
<b>Patient characteristics</b>			
Age (years)	41.6 ± 10.4	40.5 ± 9.7	0.476
Gender			0.368
Male (n, %)	24 (48%)	30 (60%)	
Female (n, %)	26 (52%)	20 (40%)	
BMI (kg/m <sup>2</sup> )	25.66 ± 2.42	26.2 ± 2.14	0.464
<b>Laboratory Data</b>			
Hemoglobin, g/dL	14.4 ± 1.2	13.9 ± 1.5	0.075
White blood cell count (10 <sup>3</sup> /μl)	7.1 ± 1.5	7.0 ± 2.5	0.453
Serum creatinine (mg/dL)	0.79 ± 0.14	0.80 ± 0.14	0.869
Glucose (mg/dL)	97.0 ± 26.2	102.7 ± 21.4	0.735
Sodium (mEq/L)	139.2 ± 2.2	136.3 ± 2.5	0.171
Potassium (mEq/L)	4.5 ± 0.3	4.5 ± 0.4	0.362
AST (unit/L)	20.9 ± 7.3	24.7 ± 8.0	0.180
ALT (unit/L)	24.1 ± 13.2	25.8 ± 8.4	0.055
Thyroid stimulating hormone (TSH) (mIU/L)	1.5 ± 1.3	1.6 ± 0.8	0.880

*Clinical characteristics and laboratory results*





# KARDİYOVASKÜLER AKADEMİ KONGRESİ

## & INTERNATIONAL ACADEMY OF YOUNG CARDIOLOGISTS

Elexus Hotel Girne, K.K.T.C.  
18-22 Eylül 2024

**Table 2**

	Patient group (n=66)	Control group (n=60)	p value
LVEDD (mm)	45.36 ± 3.03	45.72 ± 3.15	0.946
LVESD (mm)	30.34 ± 2.50	27.08 ± 4.44	0.189
LVEF (%)	60.13 ± 3.75	60.80 ± 4.50	0.491
IVS (mm)	9.18 ± 1.00	10.08 ± 1.12	0.572
E/A ratio	1.18 ± 0.33	1.15 ± 0.55	0.013
Em lateral (cm/s)	0.15 ± 0.04	0.17 ± 0.02	0.174
Am lateral (cm/s)	0.14 ± 0.04	0.17 ± 0.13	0.324
TAPSE (mm)	22.62 ± 3.22	24.20 ± 3.34	0.965
LASr (%)	19 (15-22)	23 (20-29)	<0.001
LAScd (%)	-10 (-6 - -18)	-18.5 (-16 - -23)	<0.001
LASct (%)	-3 [21]	-10 [1.75]	<0.001
LASr-c (%)	25 (14-25)	32 (28-35)	<0.001
LAScd-c (%)	11 (-9 - -19)	-20 (-18 - -21)	<0.001
LASct-c (%)	-11.5 (-4 - -15)	-16 (-15 - -19.3)	<0.001
LV-GLS	-18.22 ± 0.29	-18.9 ± 0.5	0.234
LAVmax	46 (42-59)	36 (34-39)	<0.001
LAVmin	21 (18-24)	16 (13-22)	<0.001

*2D transthoracic echocardiographic parameters and LA longitudinal and circumferential strain parameters.*



# KARDİYOVASKÜLER AKADEMİ KONGRESİ

## & INTERNATIONAL ACADEMY OF YOUNG CARDIOLOGISTS

Elexus Hotel Girne. K.K.T.C.  
18-22 Eylül 2024

### [OP-77] A phenomenon that should not be ignored: A case report of vasospastic angina

*Özgürcañ Usta, Mustafa Kamil Yemiş, Şölen Taşlıçukur, Ahmet Göktuğ Çolakođlu, Onurcañ Türk, Fatma Nur Tanrıverdi, Shabnam Javadova, Turgut Karabađ, Ahmet Öz İstanbul Eđitim ve Araştırma Hastanesi, Kardiyoloji, İstanbul*

Vasospastic angina (VSA) is an important functional cardiac disorder characterized by transient myocardial ischemia due to epicardial coronary artery spasm, during which angina attacks typically occur at rest. [1] The exact cause of this phenomenon is unclear, but it is associated with smoking history and migraines, neither of which this patient had. Other exacerbating factors, include stress, alcohol, cocaine and ergot alkaloids[2]. It most frequently occurs between the ages of 50 and 60 years, and has male predominance[3]. Here, we report on a 73-year-old male patient who presented with frequent chest pain attacks attributed to vasospasm in a small stent-free area of the right coronary artery (RCA).

#### CASE

The patient visited our hospital due to recurrent chest pain attacks. His chest pain occurred mostly in the mornings upon waking up and was alleviated by sublingual nitrate. He has a history of coronary artery bypass grafting (CABG) performed 14 years ago and has undergone nine coronary angiographies. He has no significant family history of coronary disease. He has been on clopidogrel, metoprolol, ASA, atorvastatin, perindopril, and nitrate therapy for over a year.

Following initial evaluation, we conducted an electrocardiogram (ECG), exercise stress test, and echocardiography. His resting ECG minutes before the Efor test (Fig. 1) showed no abnormalities. Echocardiography results were normal except for mild mitral and tricuspid regurgitation. His ejection fraction was measured at 55%, with no segmental wall abnormalities. Blood tests revealed normal values except for a creatinine level of 1.38 mg/dL, indicating a glomerular filtration rate (GFR) of 49. During the beginning of the exercise stress test, the patient experienced chest pain, necessitating the cessation of the test. New-onset ST segment elevation was observed at the outset of exertion (Fig. 2). Shortly afterward, the patient's chest pain subsided. Based on these test results, coronary angiography was scheduled for the patient.

Coronary angiography revealed open stents from the beginning of the right coronary artery (RCA) to the mid-portion, a short segment of stent-free area, followed by another open stent. An 80% stenosis was observed in the stent-free area (A). Upon inserting a floppy wire through the stenotic area, the stenosis improved to 100% (B). Subsequently, the wire was retracted. Three minutes later, images of the stenotic area showed a regression to 70-80% stenosis (C). The lesion responded to 100 mcg of nitrate injection (D), after which the procedure concluded successfully. It was decided to manage the patient with optimized medical therapy. The patient was prescribed diltiazem, ranolazine, trimetazidine, nitrate, atorvastatin, ASA, and clopidogrel, and was discharged the following day.

**Conclusion:** Therefore, lesions seen in angiography should be checked via nitrate administration to differentiate coronary artery spasm and atherosclerosis.

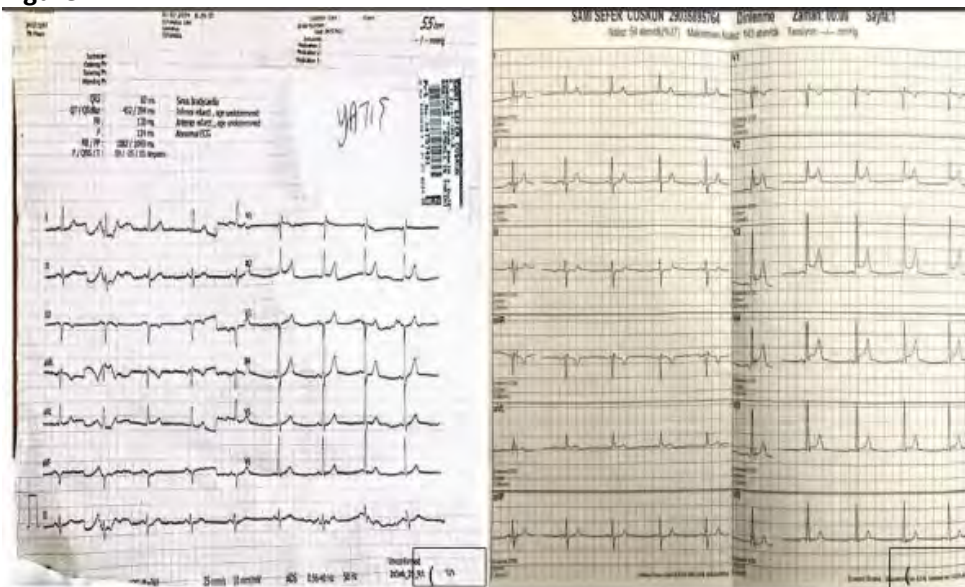
**Keywords:** Vasospastic angina, nitrat, angina with non-obstructive coronary arteries (ANOCA) to ischaemia with non-obstructive coronary arteries (INOCA)

# KARDİYOVASKÜLER AKADEMİ KONGRESİ

## & INTERNATIONAL ACADEMY OF YOUNG CARDIOLOGISTS

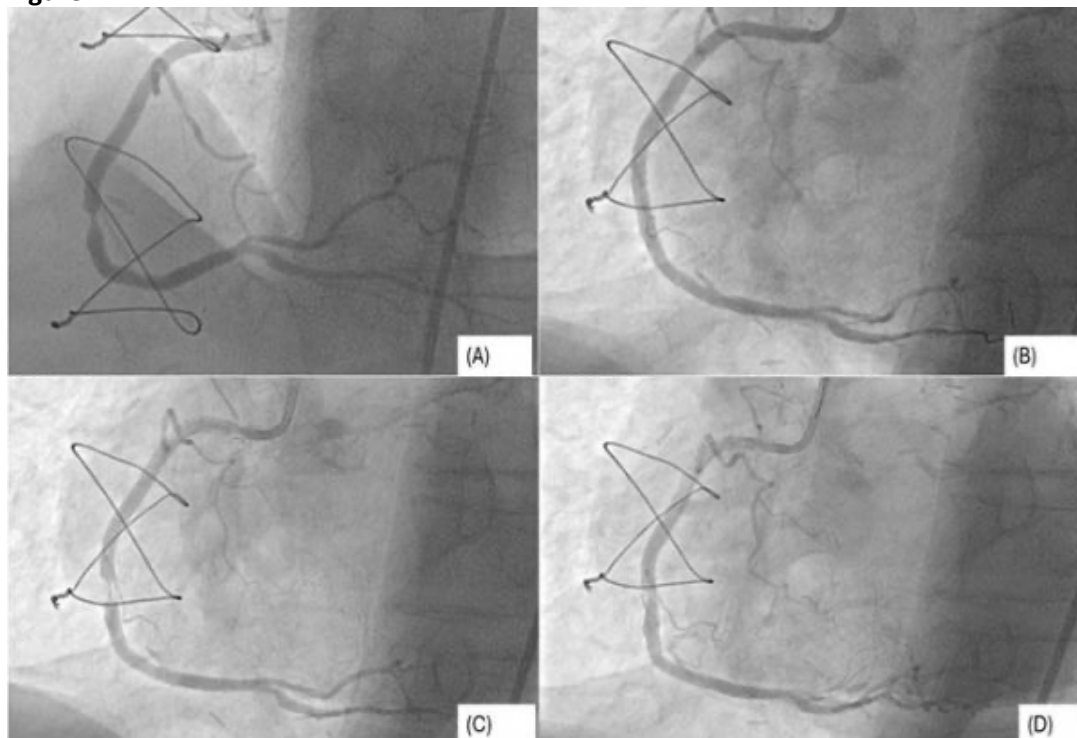
Elexus Hotel Girne, K.K.T.C.  
18-22 Eylül 2024

Figure-1



( ) Is the patient's resting ECG

Figure-2







# KARDİYOVASKÜLER AKADEMİ KONGRESİ

## & INTERNATIONAL ACADEMY OF YOUNG CARDIOLOGISTS

Elexus Hotel Girne, K.K.T.C.  
18-22 Eylül 2024

### [OP-78] Acute coronary angiogenesis observed in the anterior STEMI in a Patient at Term Pregnancy

Semih Kalkan<sup>1</sup>, Ahmet Karaduman<sup>2</sup>

<sup>1</sup>Basaksehir Cam Sakura City Hospital

<sup>2</sup>KOŞUYOLU HIGH SPECIALIZATION EDUCATION AND RESEARCH HOSPITAL

A 28-year-old patient, who is 37 weeks pregnant, presented to the emergency department with widespread chest pain. The patient had no known chronic illnesses. An electrocardiogram (ECG) revealed widespread ST depression and AVR elevation. The patient was hemodynamically unstable, and an echocardiographic examination showed widespread hypokinesia in the LAD territory. It was planned to urgently transfer the patient to the catheterization laboratory. During this process, an obstetric consultation was conducted, and a non-stress test (NST) was found to be normal. In the phase of deciding the priority between delivery and coronary angiography, a follow-up ECG showed that the ischemic findings had completely regressed. The echocardiogram showed supranormal left ventricular systolic function, and the patient was hemodynamically stable. A cesarean section (C/S) was promptly performed. During the coronary angiography, selective cannulation of the left main coronary artery (LMCA) was not achieved. The selective coronary angiography performed through the right coronary artery (RCA) showed retrograde filling of the entire left system through RCA with Rentrop grade 3 collateral circulation. Dissection of the lumen at the ostium of the LMCA was observed on the right coronary angiography. Subsequently, the patient was effectively referred for CABG. The case discussed above exemplifies the angiogenesis physiologically observed in pregnant women. Angiogenesis, the formation of new blood vessels from pre-existing ones, is a critical process during pregnancy. It ensures the proper development of the placenta and the growing fetus by facilitating the exchange of oxygen, nutrients, and waste between the mother and the baby. Understanding angiogenesis in pregnant patients provides insights into normal pregnancy progression and potential complications. During pregnancy, the maternal body undergoes significant physiological changes to support the developing fetus. Several molecular mechanisms regulate angiogenesis during pregnancy: 1. VEGF is a potent mediator of angiogenesis. It promotes the proliferation and migration of endothelial cells, which form the lining of blood vessels. During pregnancy, VEGF levels are tightly regulated to ensure proper placental and fetal development, 2. PlGF is another critical factor involved in angiogenesis. It works in conjunction with VEGF to promote blood vessel formation and enhance placental function, 3. HIF: Hypoxia, or low oxygen levels, within the placenta can trigger the production of HIF, which in turn stimulates the expression of VEGF and other angiogenic factors. The physiological effects of pregnancy mentioned above acutely facilitated the perfusion of the left system in our case as well. When pregnant patients present with acute coronary syndrome, it is important to remember that the angiogenic capacity can provide crucial time for delivery, which is vital for the health of both the mother and the baby.

**Keywords:** angiogenesis, pregnancy, acute, coronary, syndrome

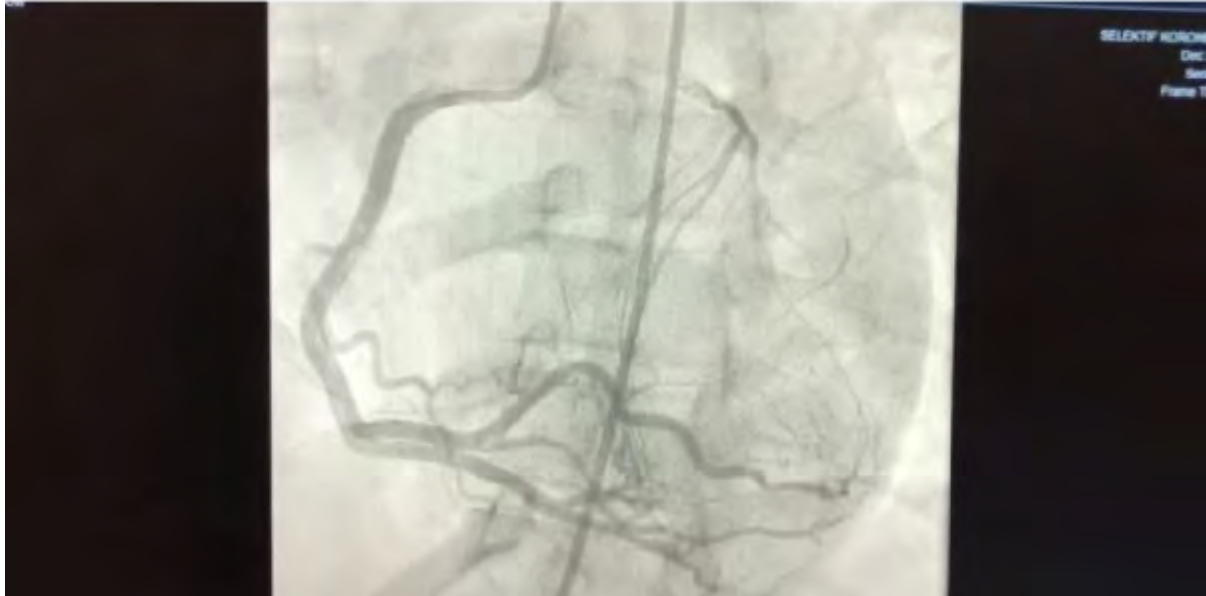

# KARDİYOVASKÜLER AKADEMİ KONGRESİ

## & INTERNATIONAL ACADEMY OF YOUNG CARDIOLOGISTS

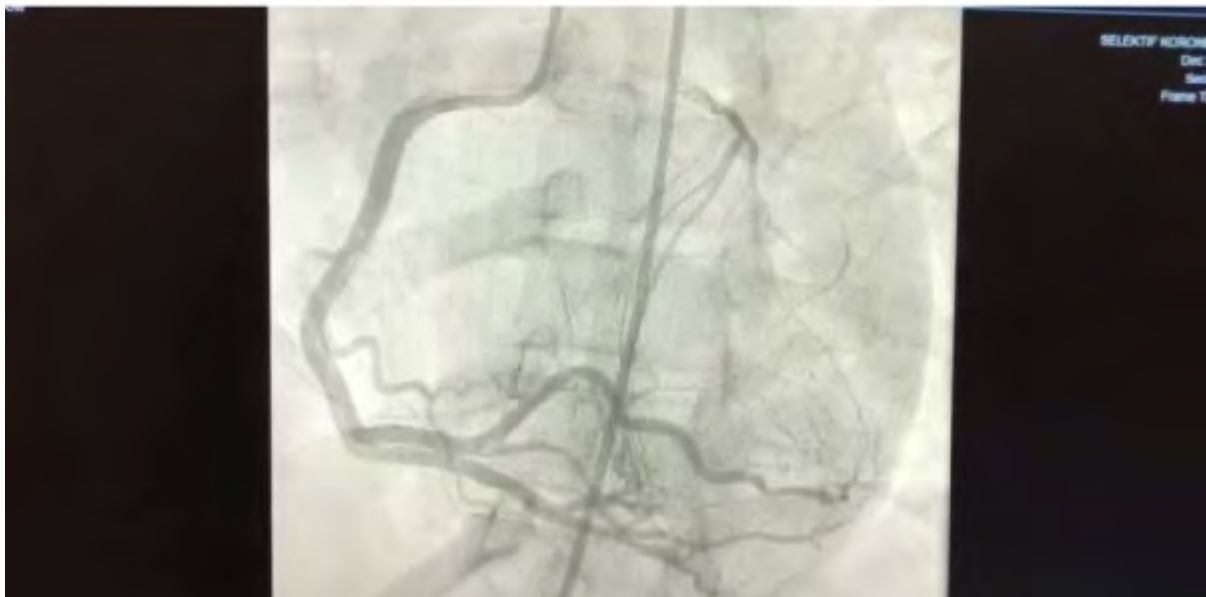Elexus Hotel Girne, K.K.T.C.  
18-22 Eylül 2024

fig 1



*aortagraphy for left main*

fig 2



*Retrograde filling of left system from right coronary*



# KARDİYOVASKÜLER AKADEMİ KONGRESİ

## & INTERNATIONAL ACADEMY OF YOUNG CARDIOLOGISTS

Elexus Hotel Girne, K.K.T.C.  
18-22 Eylül 2024

### [OP-79] Successful Intervention in a Patient With Massive Coronary Air Embolism to the Left Coronary Arteries During Coronary Angiography: A Case Report

Ömer Tepe<sup>1</sup>, Anıl Akray<sup>2</sup>, Rabia Eker Akıllı<sup>3</sup>

<sup>1</sup>Osmaniye State Hospital, Cardiology Clinic, Osmaniye, Turkey

<sup>2</sup>İskenderun State Hospital, Cardiology Clinic, Osmaniye, Turkey

<sup>3</sup>Cukurova University Faculty of Medicine, Department of Cardiology, Adana, Turkey

**Introduction:** Coronary air embolism is a rare complication of cardiac catheterization and its incidence varies between 0.1% and 0.3%. Coronary air embolism is mostly iatrogenic. Insufficient aspiration and washing of catheters used in interventional procedures causes air to enter the coronary vascular system. Complications of air embolism range from a clinically insignificant event to acute coronary syndrome and death. Here, we present a case of air embolism that completely filled both left coronary arteries, complicated by ventricular fibrillation, in a 36-year-old male patient who underwent diagnostic coronary intervention.

**Case:** A 36-year-old male patient applied to our clinic with a complaint of chest pain. The electrocardiogram was in sinus rhythm. In transthoracic echocardiography; EF was 65%. Cardiac tomography was first considered for our patient, who had a history of heavy smoking, a family history of common artery disease, and a history of sudden death. Since tomography was not suitable for evaluation due to tachycardia, diagnostic angiography was planned. In the right oblique pose, both LAD and LCX were observed to be filled with air from proximal to distal. The patient developed hypotension and bradycardia, and his hemodynamics rapidly deteriorated. The patient was administered 100% oxygen support and IV atropine. Immediately, heparinized saline was administered via catheter. Attempts were made to disperse the air embolism to the distal bed by repeated forceful manipulation. He was defibrillated when ventricular fibrillation was seen on the ECG. An attempt was made to disperse the air embolism by moving back and forth along the LAD and CX trace with a 0.014 inch guide wire. A few minutes later, there was no evidence of air embolism in the LAD and CX on the angiogram and TIMI-3 flow was observed. The patient's heart rate and blood pressure gradually improved. Right artery angiogram was normal. He was discharged the next day in stable condition.

**Discussion:** Coronary air embolism is a rare yet preventable complication of coronary angiography and angioplasty. Air can inadvertently enter the coronary arteries due to inadequate aspiration of angiographic or guide catheters, balloon rupture, air leak from a faulty manifold system. The management of coronary air embolism included supportive treatments (oxygen, IV dopamine, IV atropine, and CPR) and forceful injection of heparinized saline. Several methods have been proposed for the treatment of massive air embolism, such as aspiration of bubbles and fragmentation by guidewire to restore flow. In our case, injection of strong heparinized saline worked best. In our case, medical treatments and defibrillation were needed. All this prevented catastrophic consequences. Care should be taken in the cath laboratory in terms of complications that may develop during coronary intervention. Adequate materials and equipment should be available for appropriate intervention during complications.

**Keywords:** coronary arteries, air embolism, ventricular fibrillation, heparinized saline injection

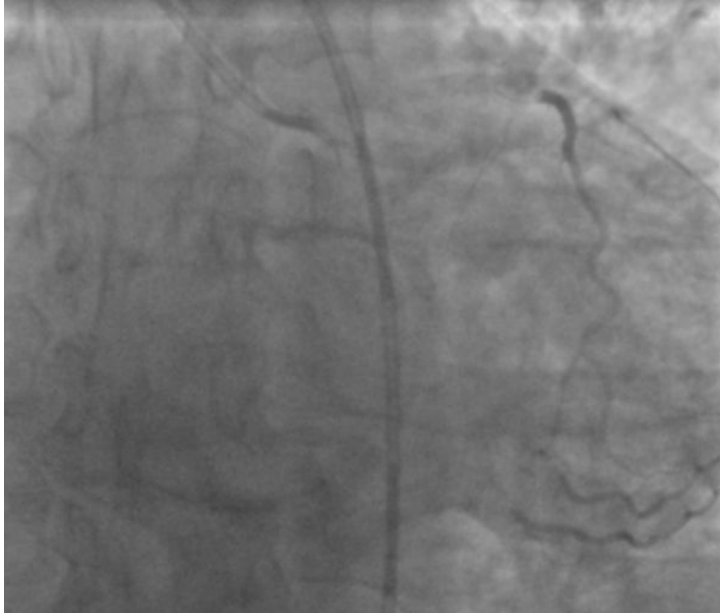


# KARDİYOVASKÜLER AKADEMİ KONGRESİ

## & INTERNATIONAL ACADEMY OF YOUNG CARDIOLOGISTS

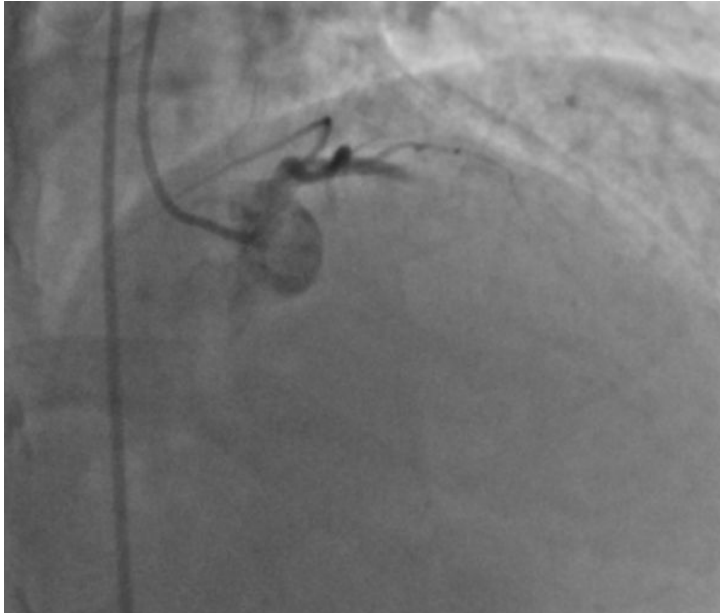Elexus Hotel Girne, K.K.T.C.  
18-22 Eylül 2024

### Air embolism



*In the right oblique pose, multiple air emboli were delivered to the LAD and LCX during contrast injection and traveled to the distal circulation. An excessive amount of air is observed inside the catheter.*

### Air embolism



*The left system, including the left main coronary artery, is completely filled with air. Air bubbles completely fill the LAD and CX arteries. Distal flow disappears.*





# KARDİYOVASKÜLER AKADEMİ KONGRESİ

## & INTERNATIONAL ACADEMY OF YOUNG CARDIOLOGISTS

Elexus Hotel Girne, K.K.T.C.  
18-22 Eylül 2024

### **[OP-80] Successful Percutaneous Management of Device Migration After Left Atrial Appendage Occlusion: Combination of Guidewire and Snare**

Emre Özdemir, Fatma Esin, Sadık Volkan Emren, Mustafa Karaca  
*Izmir Katip Celebi University, Atatürk Trainin and Research Hospital, Department of Cardiology*

**Introduction:** Atrial fibrillation (AF) is the most common arrhythmia in population with age. The most feared complication of AF is cerebro-vascular events that causes mortality and morbidity. In order to prevent this, embolism risk and anticoagulation indication are determined with different scoring systems today,

Despite the indication for anticoagulation in cases that disrupt the anticoagulation status (such as bleeding under medication), left atrial appendage occlusion (LAAO) is suggestable.

In our case, the removal of the device from the left atrium due to mobilization of the device after LAAO.

**Case:** A 78-year-old male patient who underwent TAVI procedure due to severe aortic stenosis has a history of GIS bleeding under with Apixaban 2.5 mg. Dysplastic tubular adenoma was observed in the colon during endoscopy performed by gastroenterology. During the follow-up of the patient, a LAAO decision was made due to anemia requiring transfusion.

During the TEE procedure performed on the patient, the LAA diameter was measured as a maximum of 26 mm and a minimum of 24 mm in the landing zone. A No. 31 Amulet LAAO device was implanted. After the TUG test, it was observed under TEE and fluoroscopy that the device lobe was compressed, the disc and lobe were separate, the disc was concave and perpendicular to the LAA wall, and it was decided to leave the device.

However, the device was pulled towards to LA and the system was separated from the device in this position while try to release. In the scopy and TEE images, it was observed that the device was in the LAA as in its initial position, but the lobe lost its stabilization findings. In a quiet time it was observed that the LAAO device fell into the LA during the cardiac cycle.

The patient was consulted with the surgery. Transcatheter extraction suggested. To provide support, the Agilis Steerable catheter was passed to the LA through the IAS. An attempt was made to capture it from the waist area with a macro-snare and the right diagnostic catheter, but it was unsuccessful.

In the follow-up, a myocardial biopsy catheter was used instead of a snare. It was held twice, but passage through the septum could not be achieved.

Thereupon, the terumo wire was passed through the device lobe with the support of scopy and TEE, the end of the terumo wire was held with a snare, and the device was first pulled into the Agilis catheter and then from the LA to the RA.

The patient had no signs of complications in the follow-up echoes. ASD and a left->right shunt were observed in the puncture area with a diameter of 10 mm in IAS.

**Conclusion:** LAA occluder mobilization is one of the described complication of LAAO procedure, the selection of an inappropriately sized device is the most obvious factor.

Although surgery is the main option in such a case, percutaneous methods can also be successful.

However, since there are no devices designed for percutaneous removal, different methods may be used.

**Keywords:** LAA occlusion, migration, transcatheter extraction



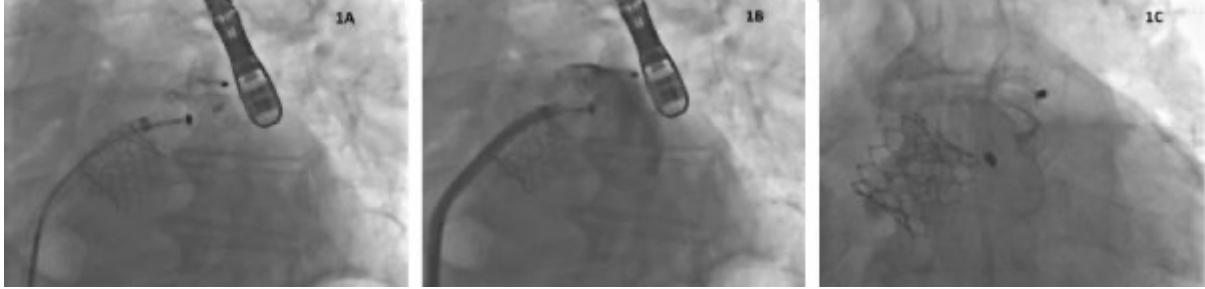


# KARDİYOVASKÜLER AKADEMİ KONGRESİ

## & INTERNATIONAL ACADEMY OF YOUNG CARDIOLOGISTS

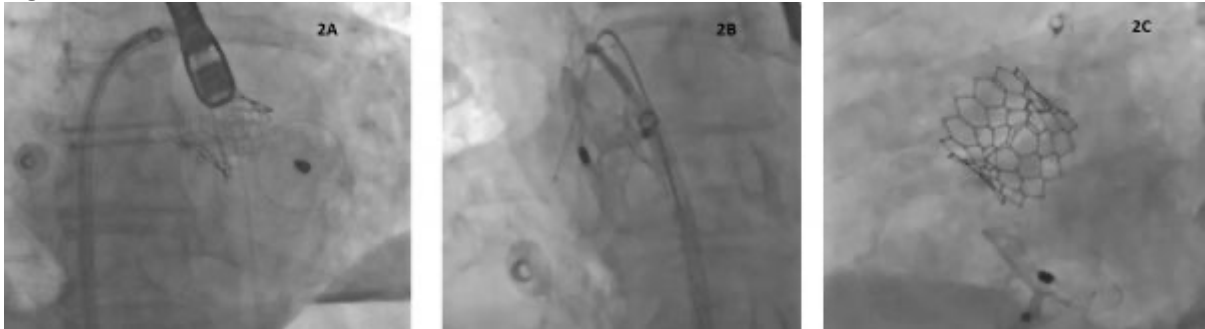Elexus Hotel Girne. K.K.T.C.  
18-22 Eylül 2024

**Figure 1**



A No. 31 Amulet LAAO device was implanted. After the TUG test, it was observed under TEE and fluoroscopy that the device lobe was compressed, the disc and lobe were separate, the disc was concave and perpendicular to the LAA wall, and it was decided to leave the device. However, the device was pulled towards to LA and the system was separated from the device in this position while try to release. In the scopy and TEE images, it was observed that the device was in the LAA as in its initial position, but the lobe lost its stabilization findings. In a quiet time it was observed that the LAAO device fell into the LA during the cardiac cycle.

**Figure 2**



, the terumo wire was passed through the device lobe with the support of scopy and TEE, the end of the terumo wire was held with a snare, and the device was first pulled into the Agilis catheter and then from the LA to the RA.



# KARDİYOVASKÜLER AKADEMİ KONGRESİ

## & INTERNATIONAL ACADEMY OF YOUNG CARDIOLOGISTS

Elexus Hotel Girne, K.K.T.C.  
18-22 Eylül 2024

### [OP-81] Challenges in a case of acute coronary syndrome with coronary artery anomaly

Güneş Melike Doğan, Hakan Kilci

*Sisli Hamidiye Etfal Training and Research Hospital, Department of Cardiology, Istanbul, Turkey*

**INTRODUCTION:** There are various classifications of coronary artery anomalies, and studies generally show that the incidence varies between 0.3 and 1.3%. Coronary artery origin anomaly is the most common congenital coronary artery anomaly.

Acute coronary syndromes (ACS) are major cardiovascular emergencies, and the most appropriate method recommended for these patient groups is percutaneous coronary intervention and optimal medical treatment.

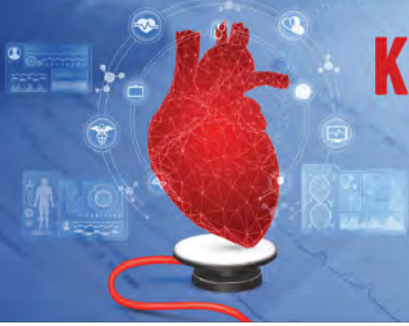Sufficient success cannot be achieved with routinely used materials and invasive techniques in acute coronary syndrome patients with coronary artery anomalies. We would like to share the difficulties we experienced and the percutaneous coronary intervention we performed on this ACS patient with coronary artery anomaly.

**CASE:** A 59-year-old male patient with no known chronic disease applied to the emergency room complaining of chest pain. The ECG was in sinus rhythm and LVEF was 58% on echocardiography. In the coronary angiography; CX which originated from the right aortic sinus along with the RCA was detected. 99% thrombotic lesions in the proximal and 70-80% lesions were observed in the middle and distal regions.

RCX lesion was accepted as the lesion responsible for acute coronary syndrome. RCA and CX emerged from a single coronary ostium. Although the ostium was cannulated with JR4, AL1, AR1 and AR2 guide catheters, the sagging wire could not be advanced due to the RCX osteal angle. The Multi-purpose guide catheter was then positioned towards the ostium of the RCX. Since support could not be provided with the microcatheter and the standard floppy wire could not be advanced, proximal and distal lesions were crossed with the Sion Blue ES wire with the support of the CTO balloon. Predilatation were performed with 1.20x15 mm and 2.5x15 mm balloons. The stent could not be advanced distally due to the CX osteal angle and the proximal lesion being angled and calcified. First, a 2.75x21 mm DES was implanted proximally, followed by post-dilatation with a 2.75x12 mm NC balloon at high ATM. Then, 2.75x33 mm DES was advanced distally and implanted overlapping. When dissection was observed in the distal part of the stent, a 2.75x12 BMS was placed over the distal stent and the dissection line was closed.

**DISCUSSION:** In this patient with an abnormal aortic origin of the circumflex coronary artery from the right coronary artery, since we were not successful in passing the responsible lesion with the standard guiding catheter and standard wires we use, the lesion was treated with a guiding catheter that we rarely use and a hydrophilic wire with extra support in the microcatheter/balloon support. Knowing the number, variety and quality of materials in the catheter laboratory in every centre where interventional procedures are performed will be of great benefit in overcoming the difficulties that may be encountered.

**Keywords:** acute coronary syndrome, coronary artery anomaly, percutaneous coronary intervention

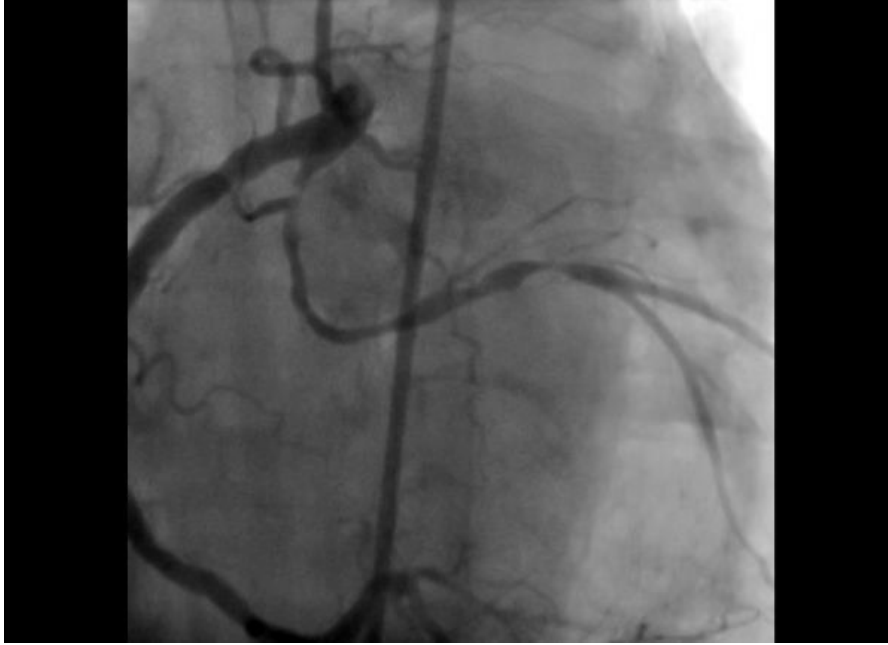

# KARDİYOVASKÜLER AKADEMİ KONGRESİ

## & INTERNATIONAL ACADEMY OF YOUNG CARDIOLOGISTS

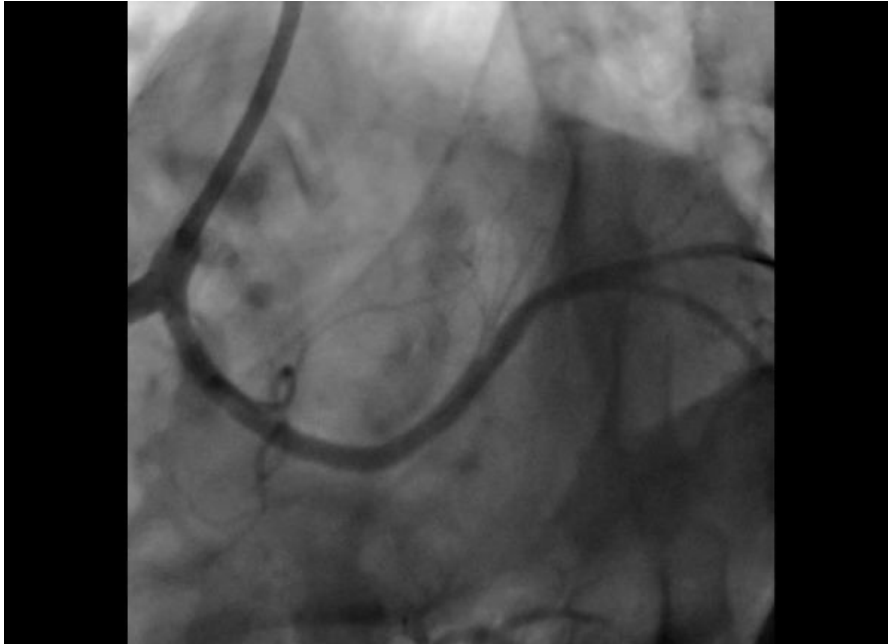
Elexus Hotel Girne, K.K.T.C.  
18-22 Eylül 2024

**Circumflex coronary artery which originated right aortic sinus**

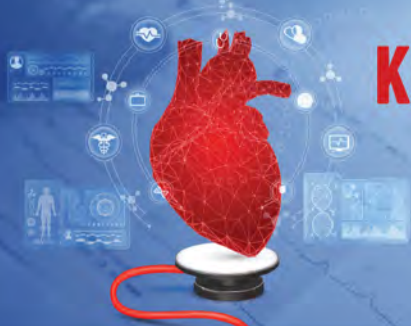

*coronary angiogram of right coroner artery*

**Final result**



*The result of percutaneous coronary intervention in the right circumflex artery*



# KARDİYOVASKÜLER AKADEMİ KONGRESİ

## & INTERNATIONAL ACADEMY OF YOUNG CARDIOLOGISTS

Elexus Hotel Girne, K.K.T.C.  
18-22 Eylül 2024

### [OP-82] The predictive role of mitral annular calcification in the manifestation of symptomatic atrial fibrillation at long-term follow-up in patients with acute coronary syndrome

Hüseyin Durak, Nadir Emlek

*Recep Tayyip Erdoğan Üniversitesi, Faculty of Medicine, Department of Cardiology*

**Objective:** The prevalence of mitral annular calcification (MAC) varies from 5% to 42%. MAC is associated with adverse cardiovascular events. The association between MAC and atrial fibrillation (AF) is also well established; however, the development of AF, particularly symptomatic AF, during long-term follow-up in patients with acute coronary syndrome (ACS) who have MAC has not been previously investigated. This study aims to address this gap.

**Methods:** Our study included 300 consecutive patients hospitalized for ACS who had sinus rhythm at baseline. Demographic data of all patients were recorded using a pre-prepared questionnaire, and biochemical investigations and transthoracic echocardiography (TTE) were performed for all patients. These patients were followed up at 6-month intervals, and those who developed symptomatic AF at each follow-up visit were recorded. After a total follow-up of 72 months, AF developed in 34 of the 300 (11.3%) patients. Patients were then divided into two groups, AF- and AF+, and statistical analyses were performed.

**Results:** Female gender, age, body mass index, hypertension, hyperlipidemia, history of PCI, Gensini score, and insulin use were more common in the symptomatic AF group (all  $p < 0.05$ ) (Table 1). Cox regression analysis for the manifestation of symptomatic AF in MAC (+) and (-) patients at 72 months follow-up revealed a Chi-square value of 22.4 and a log-rank p-value of  $< 0.001$  (Figure 1). In multivariate logistic regression analysis, BMI (HR: 1.099 %95 CI 1.026-1.177;  $p = 0.007$ ), LV EF (HR: 0.944 %95 CI 0.914-0.976,  $p = 0.001$ ), E/A ratio (HR: 2.425 %95 CI 1.073-5.479,  $p = 0.033$ ), and MAC (HR: 2.917, %95 CI 1.244-6.841;  $p = 0.014$ ) were identified as independent predictors of symptomatic AF development during long-term follow-up.

**Conclusion:** In patients with ACS in sinus rhythm, MAC detected by TTE at baseline is a strong predictor of the long-term development of symptomatic AF.

**Keywords:** Mitral annular calcification, atrial fibrillation, acute coronary syndrome

**Table 1:** Comparison of basic demographic, clinical, biochemical and echocardiographic data between groups

Variable	Atrial fibrillation (-) (n=266)	Atrial fibrillation (+) (n=34)	P
Female gender n (%)	43(16.2)	13(38.2)	0.004
Age (year)	62.2±11.7	67.1±10.1	0.019
BMI (kg/m <sup>2</sup> )	28.9±4.5	31.5±6.01	0.003
Office SBP (mmHg)	132.4±22	133.6±24.9	0.776
Office DBP (mmHg)	77.7±13.4	74.5±14.7	0.200





# KARDİYOVASKÜLER AKADEMİ KONGRESİ

## & INTERNATIONAL ACADEMY OF YOUNG CARDIOLOGISTS

Elexus Hotel Girne, K.K.T.C.  
18-22 Eylül 2024

<b>HT n (%)</b>	<b>152(57.5)</b>	<b>26(76.5)</b>	<b>0.034</b>
DM n (%)	102(38.2)	16(47.1)	0.216
<b>HPL n (%)</b>	<b>102(38.3)</b>	<b>20(58.8)</b>	<b>0.018</b>
Current smoking n (%)	116(43.6)	10(29.4)	0.080
CVA history n (%)	13(4.9)	3(8.8)	0.267
STEMI n (%)	111(41.7)	15(44.1)	0.465
CABG history n (%)	14(5.3)	5(14.7)	0.050
<b>PCI history n (%)</b>	<b>46(17.3)</b>	<b>11(32.4)</b>	<b>0.035</b>
<b>Gensini score</b>	<b>1.39±0.64</b>	<b>1.70±0.90</b>	<b>0.013</b>
ASA n (%)	266(100)	33(97.1)	0.113
Beta blocker n (%)	226(85)	29(85.3)	0.598
ACE-i/ARB n (%)	241(90.9)	29(82.4)	0.107
Statin n (%)	262(98.5)	34(100)	0.616
CCB n (%)	37(13.9)	7(20.6)	0.212
Aldosterone antagonist n (%)	12(4.5)	4(11.8)	0.094
<b>Insulin n (%)</b>	<b>16(6.1)</b>	<b>7(20.6)</b>	<b>0.009</b>
OAD n (%)	66(24.8)	10(29.4)	0.347
Glucose (mg/dL)	152.4±76.2	155.2±75.2	0.839
<b>Serum creatinine (mg/dL)</b>	<b>0.97±0.30</b>	<b>1.1±0.37</b>	<b>0.027</b>
<b>eGFR (ml/dak/1,73m<sup>2</sup>)</b>	<b>80.1±20.5</b>	<b>66.3±23.3</b>	<b>&lt;0.001</b>
25-hydroxy vitamin D (ng/mL)	14.7±13.7	15.2±7.8	0.837
Glycosylated hemoglobin (%)	6.63±1.6	6.85±1.7	0.475
WBC (10 <sup>3</sup> /μL)	10.1±3.3	10.01±3.9	0.803
Hemoglobin (g/dL)	14.2±1.8	13.7±2.5	0.137
<b>LV EF (%)</b>	<b>53.2±10</b>	<b>47.2±14</b>	<b>0.002</b>
Interventricular septum (mm)	11.9±1.8	12.01±1.5	0.720
Posterior wall (mm)	11.01±1.5	11.1±1.5	0.568
<b>Mitral E (cm/sn)</b>	<b>69.8±19.1</b>	<b>88.02±31.1</b>	<b>&lt;0.001</b>
<b>Mitral A (cm/sn)</b>	<b>85.1±24.1</b>	<b>62.3±46.7</b>	<b>&lt;0.001</b>
DT (ms)	218±45.5	209.1±45.8	0.279
<b>Mitral Am (mm)</b>	<b>8.5±2.4</b>	<b>5.7±4.1</b>	<b>&lt;0.001</b>
Mitral Em (mm)	6.4±2.06	6.7±2.2	0.481
<b>TAPSE (mm)</b>	<b>23.4±4.5</b>	<b>21.5±4.6</b>	<b>0.023</b>
<b>Aortic sclerosis n (%)</b>	<b>172(64.9)</b>	<b>30(88.2)</b>	<b>0.003</b>
<b>MAC n (%)</b>	<b>43(16.2)</b>	<b>17(50)</b>	<b>&lt;0.001</b>
<b>LAVI (ml/m<sup>2</sup>)</b>	<b>28.4±11.5</b>	<b>38.4±16.1</b>	<b>&lt;0.001</b>



# KARDİYOVASKÜLER AKADEMİ KONGRESİ

## & INTERNATIONAL ACADEMY OF YOUNG CARDIOLOGISTS

Elexus Hotel Girne. K.K.T.C.  
18-22 Eylül 2024

A: Late diastolic peak flow velocity, ACE-i: Angiotensin converting enzyme inhibitor, Am: Late diastolic velocity, ARB: Angiotensin receptor blocker, BMI: Body mass index, CABG: Coronary artery bypass graft operation, CCB: Calcium channel blocker, CVA: Cerebrovascular accident, DBP: Diastolic blood pressure, DM: Diabetes mellitus, DT: Deceleration time, E: Early diastolic peak flow velocity, eGFR: Estimated glomerular filtration rate, Em: Early diastolic velocity, HPL: Hyperlipidemia, HT: Hypertension, LAVI: Left atrial volume index, LDL: Low density lipoprotein, LV EF: Left ventricular ejection fraction, MAC: Mitral annular calcification, OAD: Oral anti-diabetic, PCI: Percutaneous coronary intervention, SBP: Systolic blood pressure, STEMI: ST segment elevation myocardial infarction, TAPSE: Tricuspid annular plane systolic excursion, WBC: White blood count.

**Table 2:** Univariate and multivariate logistic regression analysis

Variable	Univariate			Multivariate		
	HR	95% CI	P	HR	95% CI	P
Female gender *	0.306	0.151-0.621	0.001			
Age*	1.032	1.002-1.062	0.034			
<b>BMI*</b>	<b>1.093</b>	<b>1.032-1.158</b>	<b>0.002</b>	<b>1.099</b>	<b>1.026-1.177</b>	<b>0.007</b>
HT*	2.452	1.060-5.669	0.036			
HPL *	2.210	1.091-4.475	0.028			
PCI history*	2.006	0.950-4.236	0.068			
Gensini score*	1.609	1.025-2.526	0.039			
<b>LV EF*</b>	<b>0.962</b>	<b>0.941-0.984</b>	<b>0.001</b>	<b>0.944</b>	<b>0.914-0.976</b>	<b>0.001</b>
Mitral E	1.028	1.016-1.040	<0.001			
Mitral A	0.978	0.968-0.988	<0.001			
Mitral Am	0.722	0.701-0.850	<0.001			
<b>E/A ratio*</b>	<b>2.425</b>	<b>1.108-5.309</b>	<b>0.025</b>	<b>2.425</b>	<b>1.073-5.479</b>	<b>0.033</b>
E/Em ratio*	1.116	1.048-1.189	0.001			
TAPSE	0.932	0.861-1.009	0.083			
Aortic Sclerosis *	3.456	1.212-9.855	0.020			
<b>MAC*</b>	<b>4.888</b>	<b>2.440-9.791</b>	<b>&lt;0.001</b>	<b>2.917</b>	<b>1.244-6.841</b>	<b>0.014</b>
LAVI*	1.040	1.022-1.059	<0.001			
eGFR*	0.975	0.960-0.989	0.001			
Serum Creatinine	2.063	1.059-4.019	0.033			

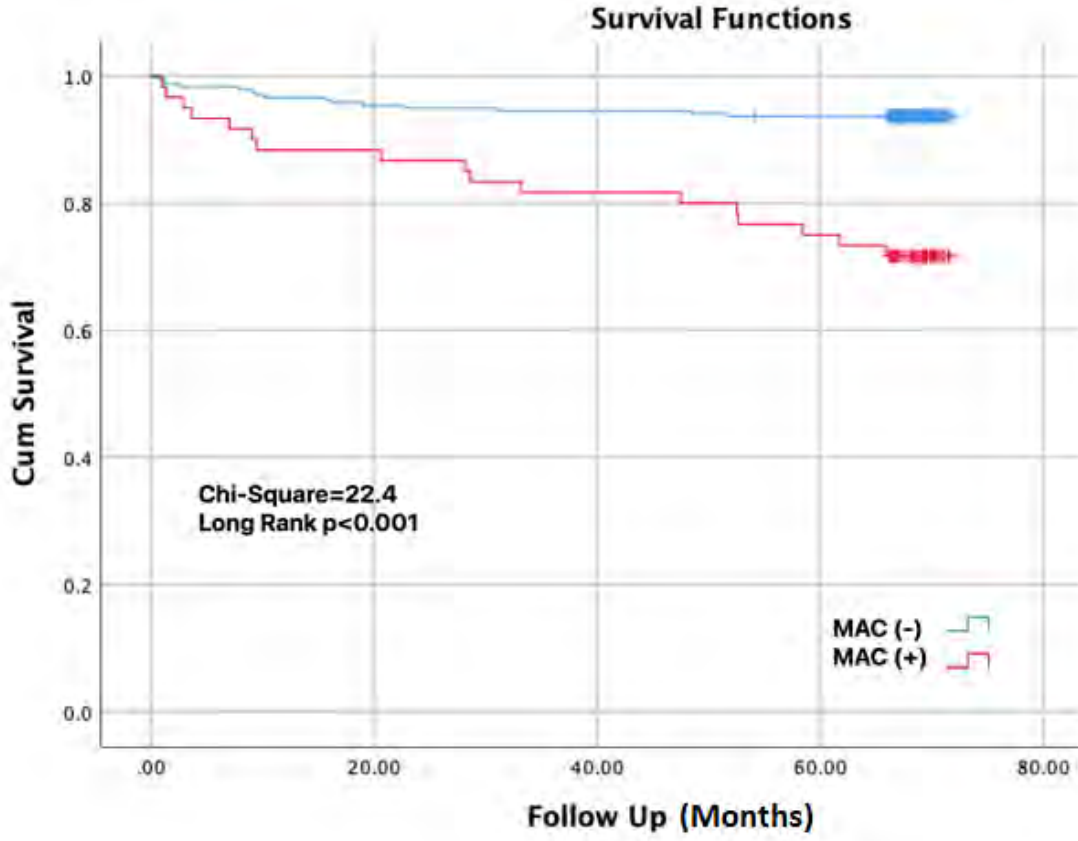
A: Late diastolic peak flow velocity, Am: Late diastolic velocity, BMI: Body mass index, DT: Deceleration time, E: Early diastolic peak flow velocity, eGFR: Estimated glomerular filtration rate, Em: Early diastolic velocity, HPL: Hyperlipidemia, HT: Hypertension, LAVI: Left atrial volume index, LV EF: Left ventricular ejection fraction, MAC: Mitral annular calcification, PCI: Percutaneous coronary intervention, TAPSE: Tricuspid annular plane systolic excursion.

**Figure 1:** Cox regression analysis for manifestation of atrial fibrillation in mitral annular calcification (MAC) [+] and [-] patients at 72 months follow-up.

# KARDİYOVASKÜLER AKADEMİ KONGRESİ

## & INTERNATIONAL ACADEMY OF YOUNG CARDIOLOGISTS

Elexus Hotel Girne, K.K.T.C.  
18-22 Eylül 2024





# KARDİYOVASKÜLER AKADEMİ KONGRESİ

## & INTERNATIONAL ACADEMY OF YOUNG CARDIOLOGISTS

Elexus Hotel Girne, K.K.T.C.  
18-22 Eylül 2024

### [OP-83] The Predictive Value of TG/HDL Ratio on No-Reflow Phenomenon in STEMI Patients

Yunus Emre Özbebek

Ankara Etlik City Hospital/Seçilen sanatçı ve konseptte göre fiyatlandırılacaktır.

**Background:** The no-reflow phenomenon in STEMI (ST-Elevation Myocardial Infarction) patients is characterized by inadequate blood flow restoration despite successful reperfusion therapy and is associated with adverse outcomes. The TG/HDL (Triglyceride to High-Density Lipoprotein) ratio is a recognized cardiovascular risk marker. This study aims to evaluate whether the TG/HDL ratio can predict the occurrence of no-reflow in STEMI patients.

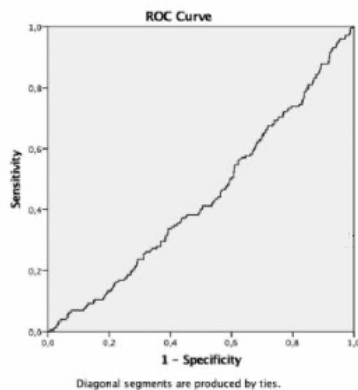
**Methods:** This retrospective study included 1571 STEMI patients whose TG and HDL cholesterol levels were measured upon admission. The TG/HDL ratio was calculated, and the no-reflow status was determined through angiographic findings. Logistic regression analysis was employed to assess the relationship between the TG/HDL ratio and the no-reflow phenomenon.

**Results:** Logistic regression analysis revealed that the TG/HDL ratio is a significant predictor of the no-reflow phenomenon ( $p = 0.024$ ). Contrary to expectations, an increase in the TG/HDL ratio was associated with a decrease in the likelihood of no-reflow. The constant term was  $-2.096$ , representing the log-odds of no-reflow when TG/HDL ratio is zero. The model was significant, and ROC curve analysis showed the model's discriminative power ( $AUC = 0.441$ ).

**Conclusion:** The TG/HDL ratio is a significant predictor of the no-reflow phenomenon in STEMI patients. Contrary to expectations, an increase in the TG/HDL ratio is associated with a decrease in the likelihood of no-reflow. This finding suggests that the TG/HDL ratio can be used as a valuable biomarker in clinical practice to identify patients at higher risk of no-reflow, thereby aiding in risk stratification and management decisions.

**Keywords:** STEMI, No-reflow phenomenon, TG/HDL ratio, Cardiovascular risk marker, Angiographic findings

**Figure 1.**



The ROC curve demonstrates the discriminative power of the model. An AUC value of 0.441 indicates that the model has low discriminative ability.





# KARDİYOVASKÜLER AKADEMİ KONGRESİ

## & INTERNATIONAL ACADEMY OF YOUNG CARDIOLOGISTS

Elexus Hotel Girne, K.K.T.C.  
18-22 Eylül 2024

**Figure 2.**

*Shows the distribution of TG/HDL ratio between patients with and without the no-reflow phenomenon.*

**Table 1.**

Variable	B	S.E	Wald	d f	sig.	Exp(B )
Constant	-2.096	0.81	6.7291 5	1	0.00 0	1.123
TG/HDL Ratio	0.068 1	0.03 1	4.805	1	0.02 4	0.934

*Includes the effect of TG/HDL ratio in predicting the no-reflow phenomenon and the overall fit statistics of the model.*



# KARDİYOVASKÜLER AKADEMİ KONGRESİ

## & INTERNATIONAL ACADEMY OF YOUNG CARDIOLOGISTS

Elexus Hotel Girne. K.K.T.C.  
18-22 Eylül 2024

### [OP-84] Effect of Body Mass Index on Electrocardiographic Parameters in Healthy Subjects

Ali Nizami Elmas<sup>1</sup>, Zülkif Tanrıverdi<sup>2</sup>

<sup>1</sup>Clinic of Cardiology, Menderes State Hospital, Izmir, Turkey

<sup>2</sup>Department of Cardiology, Faculty of Medicine, Harran University, Sanliurfa, Turkey

**Background:** Obesity is defined as the body mass index (BMI)  $\geq 30$  and one of the most important health problems. Its prevalence is increasing rapidly worldwide, and it is recognized as a major risk factor for cardiovascular diseases. Obesity may cause some changes in the electrocardiography (ECG) even before overt heart disease develops. In this study, we aimed to evaluate the effect of BMI on electrocardiographic parameters.

**Methods:** A total of 91 subjects who were admitted to the cardiology outpatient clinic and who did not have any cardiac disease on investigations were included in our study. Subjects with a previous diagnosis hypertension or diabetes mellitus were also excluded. Subjects were divided into three groups based on WHO BMI classification as follows: normal weight (BMI 18.5 to  $< 25$ ), overweight (BMI 25 to  $< 30$ ) and obese (BMI  $\geq 30$ ). Baseline clinical and laboratory variables were recorded. Also, QRS duration, QT/QTc interval, QRS axis and T axis were recorded from the automatic report of ECG device. Frontal QRS-T angle was calculated as absolute difference between QRS axis and T axis.

**Results:** There was no difference among the three groups in terms of age, gender, blood pressures and laboratory parameters (Table 1). Electrocardiographic and echocardiographic variables are shown in Table 2. As BMI increased, both QRS axis ( $p=0.001$ ) and T axis ( $p=0.044$ ) were gradually decreased significantly. Meanwhile, frontal QRS-T angle ( $p=0.025$ ) was significantly increased with the increased BMI. However, although QRS duration, QT and QTc interval also increased with BMI, the difference among the groups was not statistically significant ( $p=0.095$ ,  $p=0.607$  and  $p=0.277$ , respectively). In correlation analysis, BMI was negatively correlated with QRS axis ( $r= -0.379$ ,  $p<0.001$ ) and T axis ( $r= -0.270$ ,  $p=0.010$ ), whereas positively correlated with frontal QRS-T angle ( $r= 0.227$ ,  $p= 0.030$ ).

**Conclusion:** We showed that obesity did not affect the myocardial repolarization parameters. However, as BMI increased QRS and T axis decreased, but frontal QRS-T angle increased significantly. Further studies with larger participants are required to better elucidate the effect of BMI on electrocardiographic parameters.

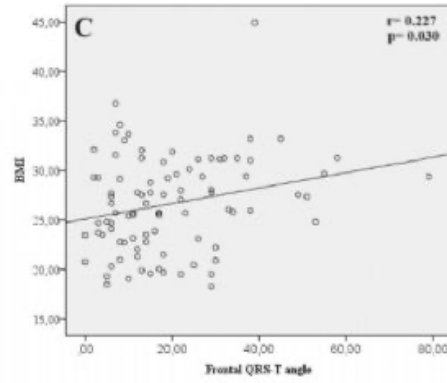
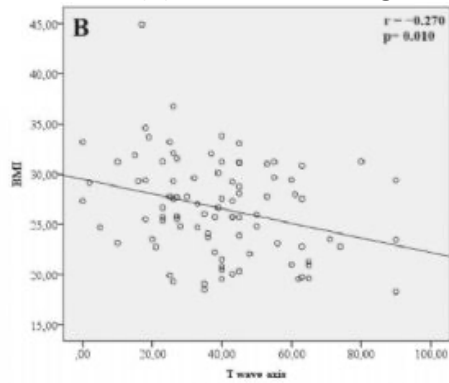
**Keywords:** Obesity, electrocardiography, QRS axis, T axis, frontal QRS-T angle

# KARDİYOVASKÜLER AKADEMİ KONGRESİ

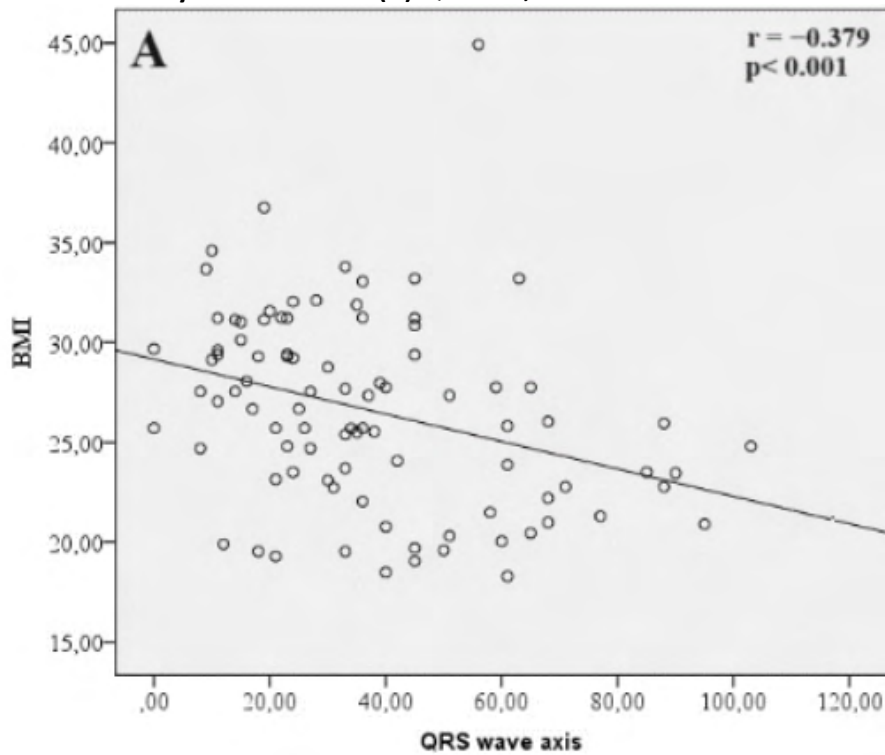
## & INTERNATIONAL ACADEMY OF YOUNG CARDIOLOGISTS

Elexus Hotel Gıme. K.K.T.C.  
18-22 Eylül 2024

(B) T axis and (C) frontal QRS-T angle



Correlation analysis of BMI with (A) QRS axis,





# KARDİYOVASKÜLER AKADEMİ KONGRESİ

## & INTERNATIONAL ACADEMY OF YOUNG CARDIOLOGISTS

Elexus Hotel Girne. K.K.T.C.  
18-22 Eylül 2024

### [OP-85] Management of complications that develop during intervention in LAD osteal lesion

Hüseyin Oğuz<sup>1</sup>, Sinem Çakal<sup>2</sup>, Halil İbrahim Biter<sup>3</sup>, Erdal Belen<sup>4</sup>, Mehmet Mustafa Can<sup>5</sup>

<sup>1</sup>Hüseyin Oğuz

<sup>2</sup>Sinem Çakal

<sup>3</sup>Halil İbrahim Biter

<sup>4</sup>Erdal Belen

<sup>5</sup>Mehmet Mustafa Can

A 56-year-old male patient with uncontrolled hypertension, dyslipidemia, type 2 diabetes mellitus and a history of smoking. His exertional angina, lasting 6 months, had increased in the last 1 week and lasted approximately 15-20 minutes. He applied to the cardiology in another hospital due to ongoing typical rest angina. ECG: Sinus rhythm, T negativity in anterior leads. TTE: Left ventricular wall motion defect; apex, apicoseptum, mid anterior hypokinetic, mild mitral regurgitation EF 45%, left ventricular concentric hypertrophy. On call angiography performed 1 week ago: LMCA: distal plaque LAD: osteal 70%, mid 95% CX: normal RCA: proximal plaque, mid 40% PDA 80%, PLA 30%. The patient was decided to undergo bypass surgery (CABG) according to the decision of cardiology and cardiovascular surgery. However, the patient did not accept surgery and made his own choice and antiischemic treatment (aspirin 100 mg 1\*1, atorvastatin 40 mg 1\*1, ramipril 5 mg 1\*1, metoprolol succinate 50 mg 1\*1) was arranged and he was discharged. Then he was referred to our clinic for percutaneous intervention. The risks were explained to the patient. The patient, who absolutely refused CABG was decided to attempt percutaneous intervention in high-risk LAD osteal, LAD mid and PDA. He was then taken to the cath lab and perform angiography. LAD was wired with sion black also CX was wired with floppy guidewire. LAD lesion was predilated with 1.25x15 mm, 1.5x8 mm mini trek, 2.0x15 mm and 2.75x15 mm NC ballons. Then, 2.75x38 mm DES (14atm) was implanted into the LAD lesion area. Then 3.0x24 mm DES implanted to the LMCA through LAD. Afterwards, POT was performed to the LMCA with a 4.0x8 mm NC balloon. Because of critical lesion in Cx ostium, we decided to performe TAP tecnique as a bail out strategy. CX has been rewired. PTCA was performed on the CX ostium with a 1.5x8 mm mini trek balloon at 20 atm. While 3x15 mm NC balloon has been placed in LMCA 2.75x24 DES was implanted at 14 ATM to the CX. The balloon of this stent was withdrawn and kissing balloon inflation was performed with a 3x15 mm NC balloon extended from the LMCA to the LAD. And then it was seen that hazzy plaque in the distal of previously placed Cx stent.then we saw that hazzy plaque in the distal part of Cx stent we decided to place another stent When advancing the stent(2.75x17 mm DES) distally stent was stripped from the aorta to extend to the CX. By entering from the left femoral artery, the stent extending into the aorta was removed with the help of a JL4 guiding catheter and Snare. A final kissing balloon was performed by placing a 3.0x15 mm NC balloon and a 3.5x15 mm NC balloon in the LAD and CX. Then, the procedure was terminated by performing final POT with a 4.0x8 mm NC balloon. The process has been terminated. After 24 hours of observation, the patient, who had no dynamic ECG changes and no angina, was discharged after his treatment was adjusted.

**Keywords:** coronary bifurcation, TAP, Snare, LMCA, LAD



# KARDİYOVASKÜLER AKADEMİ KONGRESİ

## & INTERNATIONAL ACADEMY OF YOUNG CARDIOLOGISTS

Elexus Hotel Girne, K.K.T.C.  
18-22 Eylül 2024

Figure 1

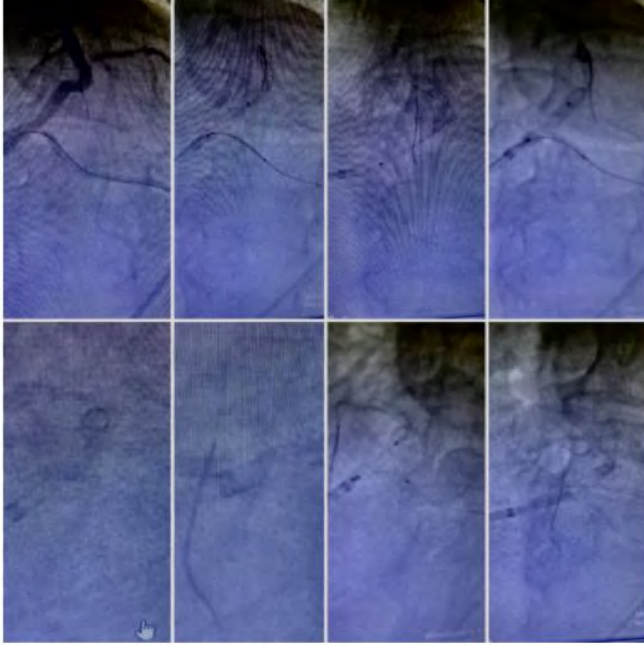
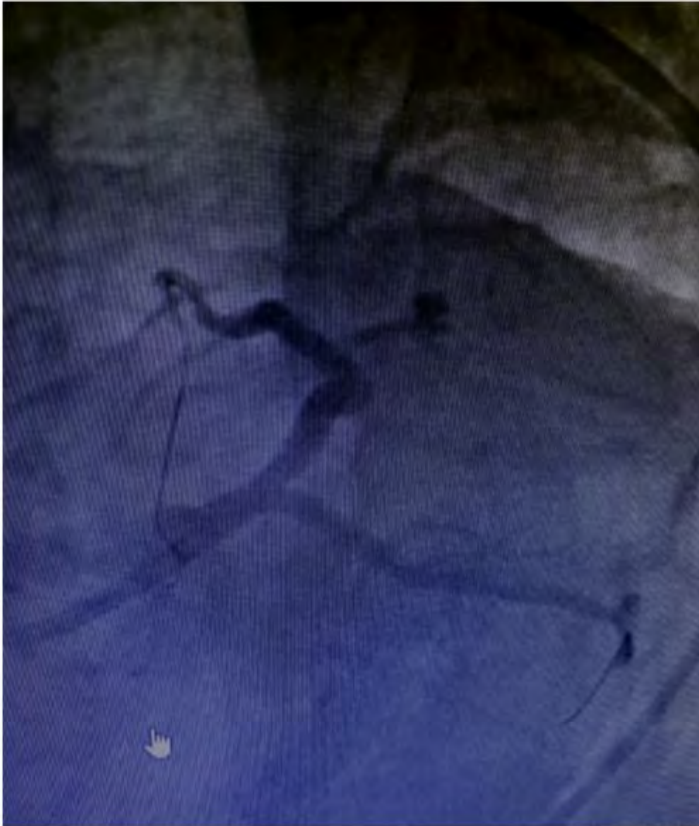

Figure 2





# KARDİYOVASKÜLER AKADEMİ KONGRESİ

## & INTERNATIONAL ACADEMY OF YOUNG CARDIOLOGISTS

Elexus Hotel Girne, K.K.T.C.  
18-22 Eylül 2024

### **[OP-86] Coronary Perforation in STEMI, How We Managed It?**

Cansu Ozturk

*Gazi Yasargil Training and Research Hospital, University of Health Sciences, Diyarbakir, Turkey*

Coronary artery perforation (CAP) is a rare and feared complication, with a varying incidence ranging from 0.1% to 0.8% of all percutaneous coronary interventions (PCI), and up to 4.8–8.9% for complex coronary lesions, such as chronic total occlusions (CTO). The grade of CAP correlates well with the clinical outcome and is usually stratified using the Ellis classification.

Numerous observational studies have shown the superiority of covered stents over prolonged balloon inflation and heparin reversal, predominantly in cases of Ellis type III perforations. Nevertheless, covered stents are known to have a potentially higher rate of in-stent restenosis and stent thrombosis.

**Case:** 62 year-old male patient who has diabetes, was admitted to emergency department with chest pain. ECG:SR, ST elevation on precordial derivation, reciprocal ST depression on inferior leads. EF:%25, apex-anterior and septum mid apical, lateral apical akinetic, 1 mitral regurgitation, left ventricular thrombus (18x5 mm).

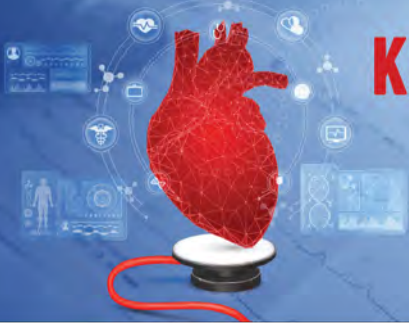Angiography was performed due to anterior myocardial infarction. Perforation (Ellis type III) was observed in the distal after PCI in the LAD calcific responsible subtotal lesion. With balloon inflation into the stent, progression of extravasation was prevented. Then the stent was implanted distal and proximal of the DES, extravasation decreased. LAD distal flow was present. In bedside ECHO, minimal pericardial effusion was observed. Hydration started and monitorized in coronary care unit (CCU).

Loss of consciousness, hypotension and tachycardia developed during follow up. Cardiac arrest developed and responded to CPR. Bedside ECHO performed and observed pericardial tamponade. Then urgent pericardiocentesis performed. Intravenous bolus hydration administered. Surgery was consulted and emergency angiography was performed. The LAD stent was open, there was distal flow and no obvious extravasation was observed. Patient was followed up with haemovac in CCU. He regained consciousness and improved hemodynamics.

The size and location of the perforation will determine management strategy, ranging from watchful waiting to immediate balloon tamponade and permanent vessel occlusion. Although no ideal treatment pathway exists for all perforations, algorithms may be adapted to fit patient need and operator expertise.

Haemodynamic compromise should be treated with resuscitation; evidence of cardiac tamponade should be sought. If tamponade is confirmed, pericardiocentesis should be performed, preferably guided by TTE. Glycoprotein IIb/IIIa inhibitors should be discontinued on recognition of coronary perforation because their use may be associated with increased risk of major adverse cardiac events (MACE) and greater difficulty in achieving haemostasis. Intravenous heparin can be reversed with intravenous protamine sulphate.

**Keywords:** STEMI, coronary perforation, balloon inflation

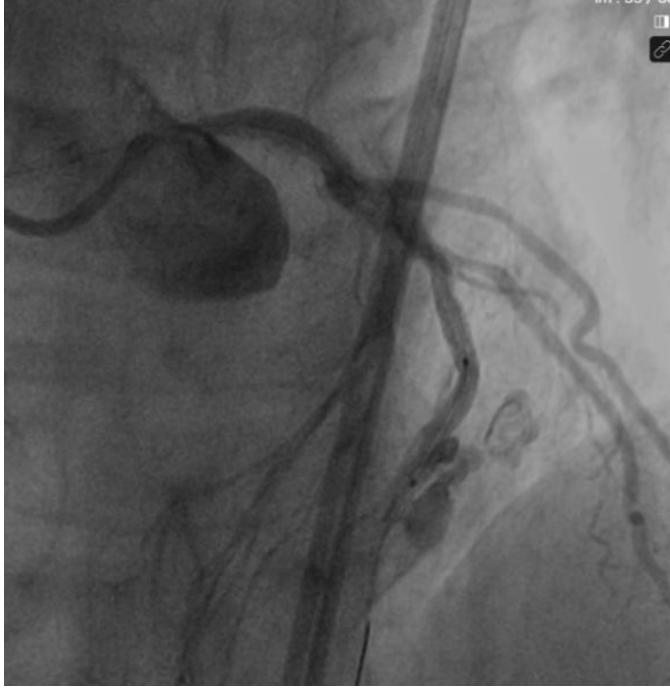

# KARDİYOVASKÜLER AKADEMİ KONGRESİ

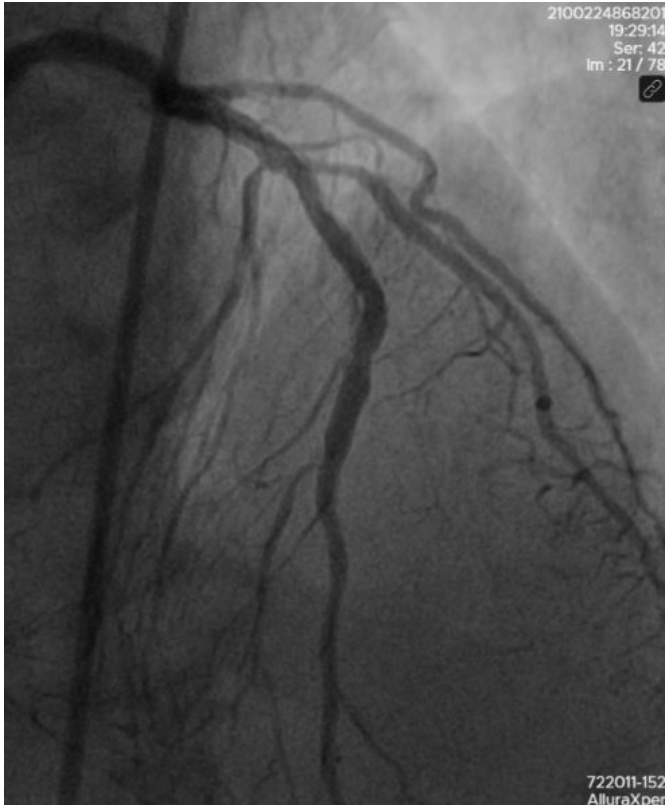## & INTERNATIONAL ACADEMY OF YOUNG CARDIOLOGISTS

Elexus Hotel Girne, K.K.T.C.  
18-22 Eylül 2024

### Coronary Perforation



### Final







# KARDİYOVASKÜLER AKADEMİ KONGRESİ

## & INTERNATIONAL ACADEMY OF YOUNG CARDIOLOGISTS

Elexus Hotel Girne, K.K.T.C.  
18-22 Eylül 2024

### [OP-87] Duke treadmill score predicts significance of erectile dysfunction in patients with coronary slow flow

Dogac Oksen<sup>1</sup>, Gursu Demirci<sup>2</sup>, Muzaffer Aslan<sup>3</sup>, Hadeil Alhashmi<sup>1</sup>

<sup>1</sup>Altınbas University Medical Faculty

<sup>2</sup>Arnavutkoy State Hospital

<sup>3</sup>Siirt University Medical Faculty

**Introduction:** There are many studies showing the close connection between vascular diseases and erectile dysfunction (ED). Endothelial dysfunction is a possible cause in the pathophysiology of both coronary slow flow (CSF) and ED. Duke treadmill score (DTS) is a non-invasive test widely used in the diagnosis and risk stratification of coronary artery diseases. We sought to determine the predictive power of DTS for ED in patients with CSF.

**Material-Methods:** 42 patients with diagnosis of CSF and 18 healthy male volunteers with normal coronaries after coronary angiography, without acute coronary syndrome, and with normal cardiac markers were included in the study. Erectile dysfunctions were divided into 5 groups according to the individuals' international index of erection function (IIEF) scoring. Participants were subjected to the treadmill test and divided into groups according to their DTS.

**Results:** There was no significant difference in demographics between groups. The average age was  $46.42 \pm 12.45$  and  $42.14 \pm 8.65$  in the CSF and control groups, respectively,  $p = 0.056$ . The mean IIEF score in the CSF and control group were  $19.34 \pm 8.16$  and  $23.45 \pm 7.64$ , respectively. IIEF score was significantly higher than CSF in the control group ( $p = 0.016$ ). In the CSF group, the mean DTS was determined as  $-2.4 \pm -3.2$ , while in the control group it was  $4.5 \pm 2.8$  ( $p < 0.001$ ). Correlation analysis was performed to investigate the relationship between DTS and IIEF in each group. In CSF group the correlation was found  $r = 0.72$ ,  $p < 0.001$  and in control group the correlation between DTS and IIEF was  $0.127$ ,  $p = 0.102$

**Discussion:** ED and CSF are diseases that share the same pathophysiology in consequence of endothelial dysfunction. It has been reported that the TIMI frame score increases as the severity of endothelial dysfunction increases. Likewise, for the maintenance of erection, it is necessary for the vascular endothelium to maintain its function in a healthy manner and to release nitric oxide. A low DTS score is an important predictor of both coronary and peripheral vascular diseases. Additionally, there is a linear correlation between treadmill performance and IIEF score. In the study, a statistically significant positive correlation was found between IIEF score and DTS in patients with CSF. The DTS has been viewed as a simple non-invasive test that can give clues about men's sexual performance.

**Keywords:** Coronary slow flow, duke treadmill score, erectile function





# KARDİYOVASKÜLER AKADEMİ KONGRESİ

## & INTERNATIONAL ACADEMY OF YOUNG CARDIOLOGISTS

Elexus Hotel Girne, K.K.T.C.  
18-22 Eylül 2024

**Table 1 Patients' characteristics and demographics**

Variable	CSF (n: 42)	Control group (n: 18)	p value
Age, years	46.42 ± 12.45	42.14 ± 8.65	0.056
Hypertension, % (n)	11.9(5)	16.6 (3)	0.356
Diabetes Mellitus, %(n)	7.1(3)	5.5 (1)	0.535
Hyperlipidemia, %(n)	14.2(6)	2.2(4)	0.752
Smoking, %(n)	42.8(18)	50(9)	0.104
Mean TIMI frame, fc	43.24 ± 15.65	24.50 ± 12.43	<0.001
IIEF score	19.34 ± 8.16	23.45 ± 7.64	0.016
DTS	- 2.4 ± -3.2	4.5 ± 2.8	<0.001



# KARDİYOVASKÜLER AKADEMİ KONGRESİ

## & INTERNATIONAL ACADEMY OF YOUNG CARDIOLOGISTS

Elexus Hotel Girne. K.K.T.C.  
18-22 Eylül 2024

### **[OP-88] Coronary Artery Fistula With ST Elevation Myocardial Infarction Finding on ECG. Fistulization From Three Coronary Arteries to the Left Ventricle (Coronary-Cameral Fistulae)**

Abdulkadir Çakmak, Ömer Kertmen

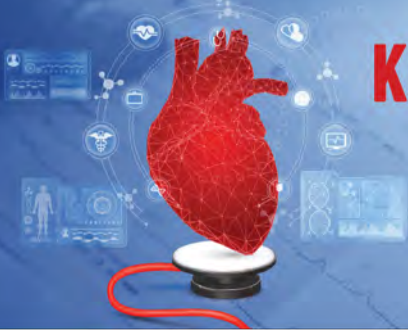*Amasya Faculty of Medicine, Cardiology Department, Amasya/Türkiye*

A 69-year-old male patient with no known disease applied to the emergency unit with a complaint of epigastric pain and discomfort. The ECG of the patient, whose physical examination was normal, revealed ST elevation in d1, aVL, V1-V2, and ST depression in dII-dIII and aVF derivations. In his transtoracic echocardiographic examination; left ventricular EF was found to be normal, and the heart chambers and valves were normal. With the diagnosis of STEMI, the patient was premedicated and taken for coronary angiography. Significant blood flow was observed to the left ventricle with numerous fistulas from the LAD-CX mid and distal regions and from the RCA distal region. After the procedure, the patient was followed up in the coronary intensive care unit. Medical treatment was planned. The patient, whose troponin values taken from the first hospitalization until the 72nd hour of discharge were always at normal levels, was discharged with an appointment for MPS (myocardial perfusion scintigraphy) to investigate coronary ischemia. Coronary artery fistulas (CAF) are rare anatomical anomalies of the coronary arteries. But especially if they become symptomatic, it can trigger a range of complications if not detected and treated quickly. The diagnostic approach is determined by a series of sequential examinations according to the patient's symptoms. If CAF is not an incidental finding and is symptomatic due to myocardial ischemia (angina, dyspnea, etc.), coronary angiography is necessary for optimal treatment.

Fistula diagnosis, treatment, and follow-up planning are variable and depend on several factors, including fistula size and symptoms.

**Keywords:** STEMI, coronary-cameral fistulae, rare anomalies of coronary arteries

---

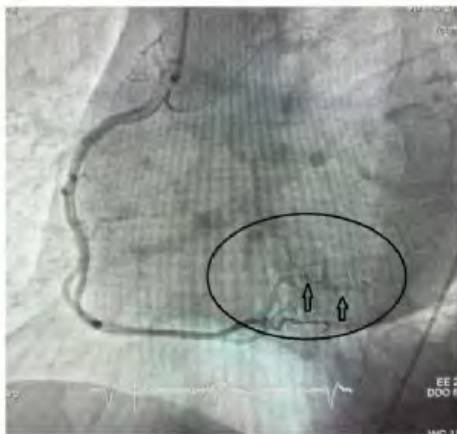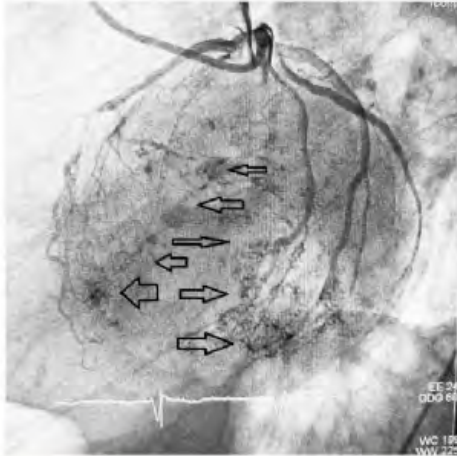


# KARDİYOVASKÜLER AKADEMİ KONGRESİ

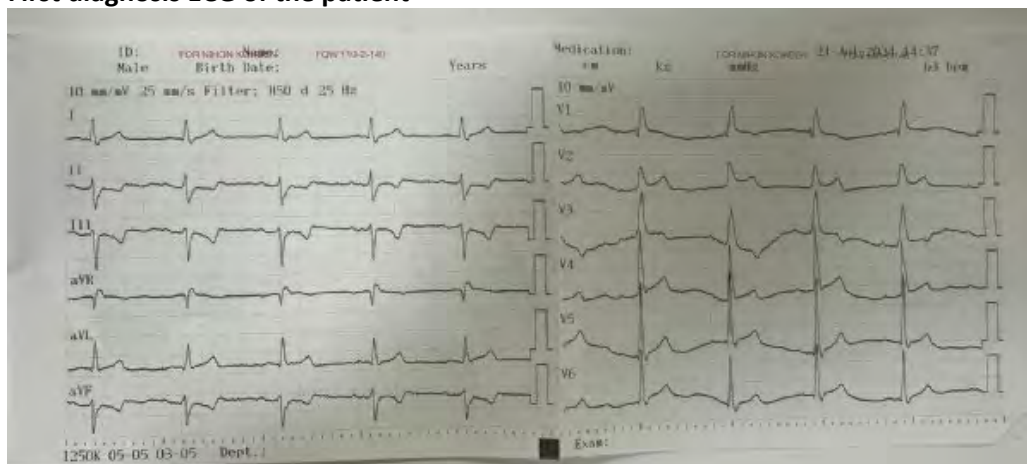
## & INTERNATIONAL ACADEMY OF YOUNG CARDIOLOGISTS

Elexus Hotel Girne, K.K.T.C.  
18-22 Eylül 2024

Coronary angiography image of multiple fistulization from LAD-CX-RCA arteries to the left ventricle



First diagnosis ECG of the patient



AuthorToEditor: Kind regards



# KARDİYOVASKÜLER AKADEMİ KONGRESİ

## & INTERNATIONAL ACADEMY OF YOUNG CARDIOLOGISTS

Elexus Hotel Girne, K.K.T.C.  
18-22 Eylül 2024

### **[OP-89] Management of Acute Saphenous Vein Graft Thrombotic Occlusion: Effective Use of Mechanical and Medical Treatment within the PCI Strategy**

Yakup Yunus Yamanturk

*Cardiology Department, Artvin State Hospital, Artvin, Turkey*

**Introduction:** Despite improvements in surgical techniques and medical treatments, saphenous vein grafts in patients with a follow-up period exceeding 5 years often present with significant stenosis or late thrombosis. In patients presenting with acute coronary syndrome (ACS), while reopening the native artery is an alternative treatment option, intervention on the SVG lesion may be more appropriate, particularly when the native artery lesion is a chronic total occlusion.

**CASE PRESENTATION:** A 49-year-old male patient with a history of triple-vessel coronary artery bypass grafting (CABG) 8 years prior was referred to our clinic with a pre-diagnosis of acute inferior STEMI (Figure 1). The patient's symptoms had started 24 hours earlier. Rapid coronary angiography revealed chronic total occlusions (CTOs) in the native RCA, LAD, and Cx OM1 segments. Selective cannulation of the coronary bypass grafts showed that the LAD-LIMA and Cx-Saphenous grafts were patent, while the RCA-Saphenous graft had a proximal thrombotic occlusion (Figure 2). Subsequently, the saphenous graft was cannulated using a right coronary Judkins guiding catheter, and a guidewire was advanced through the graft. Despite percutaneous coronary angioplasty and implantation of a 3.5x30 mm Promus DES, distal flow could not be achieved. A second guidewire was advanced into the distal segment, and a microcatheter was navigated to the area where flow could not be restored. Following the administration of intracoronary tirofiban, 25 mg of intracoronary diltiazem, 2 mg of intracoronary adrenaline, 2 mg of intracoronary nitroglycerin, 2 mg of intracoronary adenosine, and 10 mg of intracoronary alteplase, ventricular fibrillation has developed. The patient was successfully defibrillated three times (200 joules biphasic) and restored to spontaneous rhythm. Control angiography under amiodarone infusion showed restored flow in distal saphenous graft and RCA. Procedure was finished, and the patient was transferred to the ward follow-up after 48 hours of tirofiban infusion without further complications. Post-procedural daily ECG monitoring revealed a progressive reduction in ST elevations in the inferior leads, development of biphasic T-wave inversions in D3, and no pathological Q waves. Echocardiography showed limited hypokinesia at inferior wall basal segment and an LVEF of 55-60%. Patient was discharged on the 4th day post-procedure with a treatment regimen including ASA 100 mg once daily, prasugrel 10 mg once daily, rosuvastatin 40 mg once daily, edoxaban 30 mg once daily, nebivolol 5 mg once daily, ramipril 2.5 mg once daily, and pantoprazole 40 mg once daily, with plans for outpatient follow-up.

**Conclusion:** For SVG occlusions classified as Type C lesions, where success rates are notably low, the most effective approach involves the optimal combination of medical and mechanical treatment modalities. Operators should not hesitate to use their most potent medical treatment agents appropriately.

**Keywords:** acute coronary syndrome, inferior STEMI, saphenous vein graft, selective thrombolytic therapy

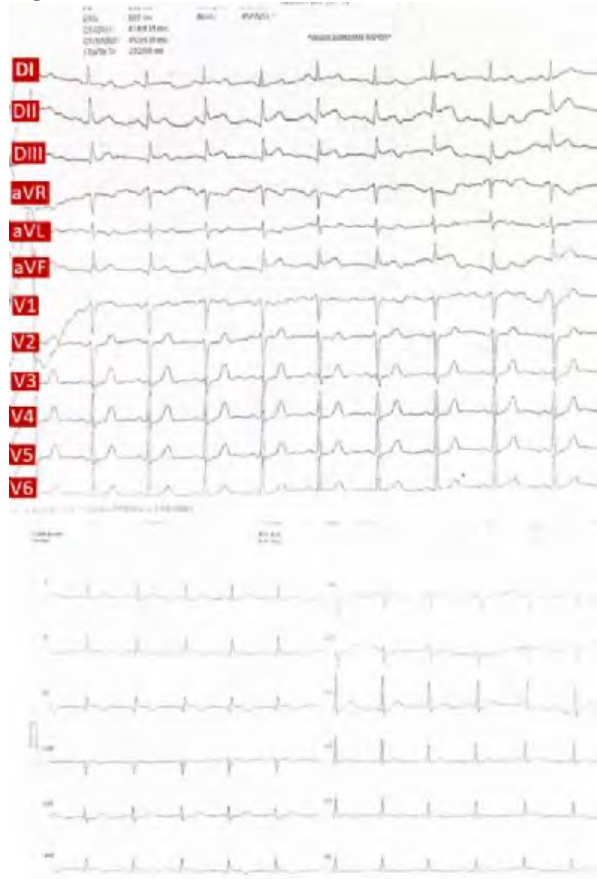

# KARDİYOVASKÜLER AKADEMİ KONGRESİ

## & INTERNATIONAL ACADEMY OF YOUNG CARDIOLOGISTS

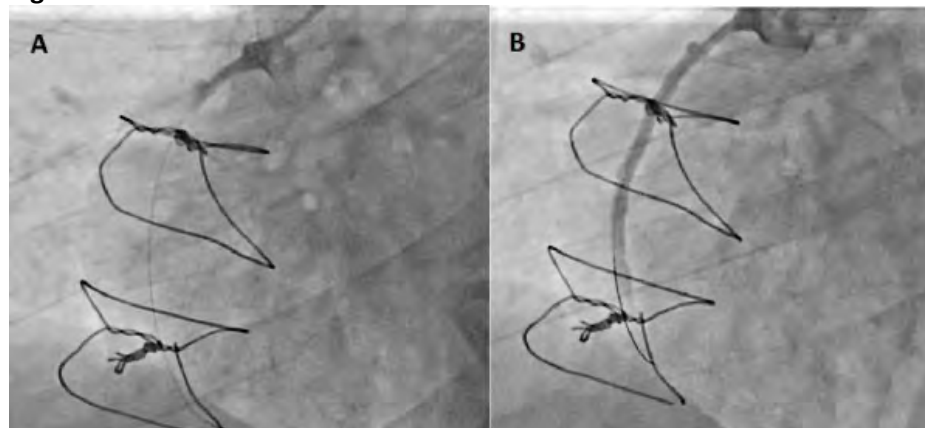
Elexus Hotel Girne, K.K.T.C.  
18-22 Eylül 2024

**Figure 1**



*A. Preprocedural ECG B. Postprocedural ECG*

**Figure 2**



*A. RCA-SVG acute occlusive lesion has seen. B. The final appearance of the lesion following successful mechanical and medical treatment*

**[OP-90] 10-second pause associated with syncope: A successful cardiac neuromodulation case managed without resorting to permanent pacemaker implantation**

Yakup Yunus Yamanturk<sup>1</sup>, Elif Oya Ilhan<sup>2</sup>, Mahmut Ekrem CUNETOĞLU<sup>2</sup>, Bilge Nazar Ateş<sup>2</sup>, Basar Candemir<sup>2</sup>

<sup>1</sup>Department of Cardiology, Artvin State Hospital, Artvin, Turkey

<sup>2</sup>Department of Cardiology, Ankara University, Ankara, Turkey


**INTRODUCTION:** Cardioneural ablation is considered a potential method for treating various sinus and/or AV node conduction disturbances associated with high vagal/parasympathetic tone. These disturbances include neurocardiogenic syncope, functional atrioventricular block, sinus dysfunction, and vagally-mediated atrial fibrillation. This modern therapy relies on the technique of mapping and ablating ganglion plexus (GP) areas with parasympathetic predominance in the right and left atria using three-dimensional electroanatomic systems, offering patients a serious alternative treatment option to permanent pacemaker implantation

**CASE DESCRIPTION:** A 30-year-old female has been experiencing syncope episodes 2-3 times per month over the past 1-2 years. During a tilt table test, a 10-second pause was observed following the administration of Isordil. Detailed assessment revealed the presence of functional (secondary) AV block and sinus arrest. The patient was deemed an appropriate candidate for Cardioneural Ablation (CNA). Following the procedure, the patient has been free of syncopal episodes for the past three months.

**DISCUSSION AND CONCLUSION:** Patients who do not have intrinsic (primary) conduction system disease and are suspected of having functional (secondary) AV/SA block should be thoroughly evaluated to determine if Cardioneural Ablation (CNA) is a suitable alternative to permanent pacemaker implantation. CNA may be an effective treatment option for functional pauses exceeding 5 seconds.

**Keywords:** atrio-ventricular block, CNA, functional av block, pause, permanent pacemaker

**Figure 1**



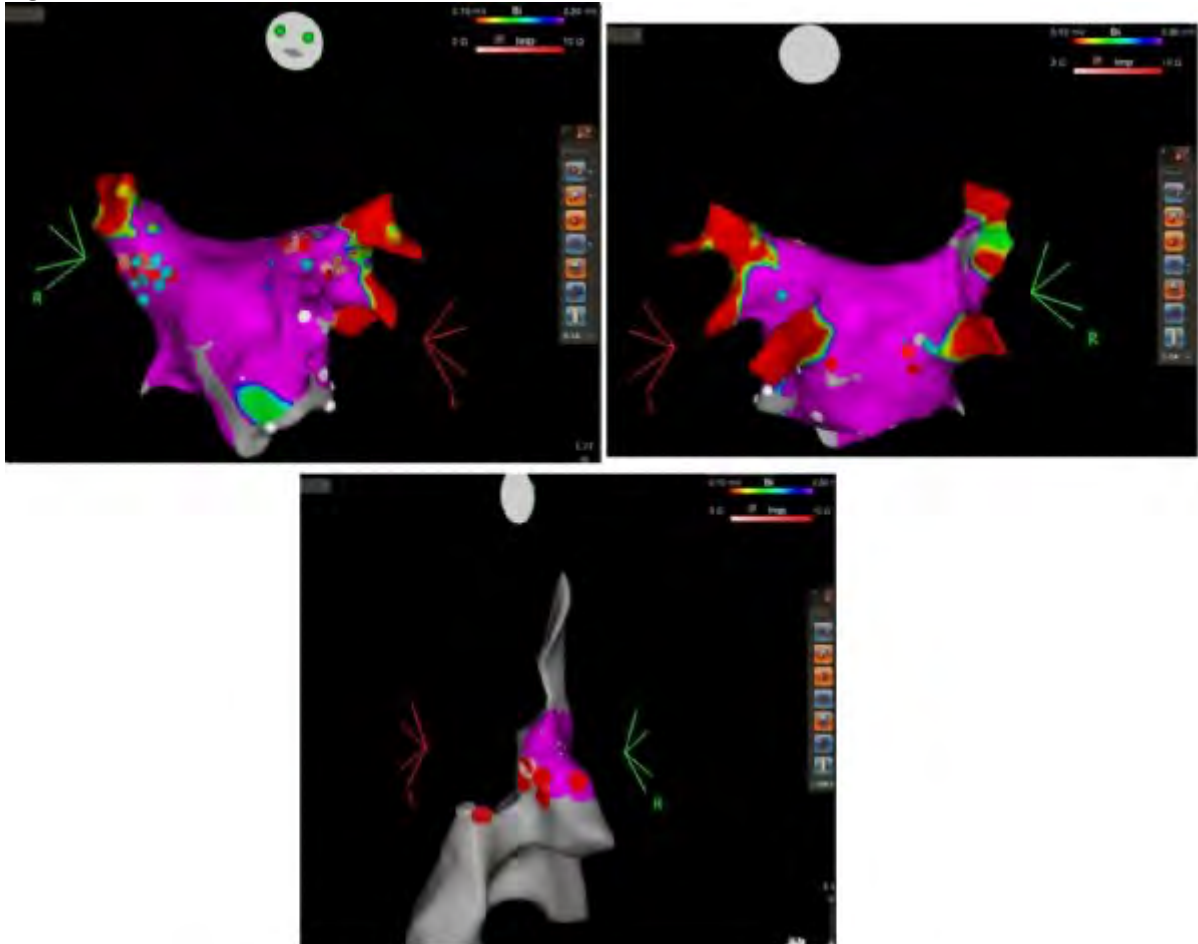
Variable PP intervals suggestive of vagal SA and AV block development at the onset of the pause (left). As recorded during a tilt test with a 10-second pause (Right)

# KARDİYOASKÜLER AKADEMİ KONGRESİ

## & INTERNATIONAL ACADEMY OF YOUNG CARDIOLOGISTS

Elexus Hotel Girne, K.K.T.C.  
18-22 Eylül 2024

Figure 2



*Successful ablation of the ganglion plexus targets in the left atrium (LA) and right atrium (RA) using a 3D electroanatomic mapping system*





# KARDİYOVASKÜLER AKADEMİ KONGRESİ

## & INTERNATIONAL ACADEMY OF YOUNG CARDIOLOGISTS

Elexus Hotel Girne. K.K.T.C.  
18-22 Eylül 2024

### **[OP-91] Do specific ECG variants in acute coronary syndrome indicate particular coronary anomalies? A patient with De Winter Syndrome had a circumflex artery (Cx) originating from the right coronary artery (RCA)**

Yakup Yunus Yamanturk<sup>1</sup>, Elif Oya Ilhan<sup>2</sup>

<sup>1</sup>Cardiology Department, Artvin State Hospital, Artvin, Turkey

<sup>2</sup>Cardiology Department, Ankara University, Ankara, Turkey

**Introduction:** In the literature, the De Winter syndrome, described by De Winter et al. and shown to be associated with acute occlusion of the left anterior descending artery (LAD), is an important ECG pattern observed as an acute STEMI equivalent. Although studies have found this pattern to have a high predictive value for LAD lesions, some reported cases have shown that right coronary artery (RCA), LAD diagonal branch, and left circumflex artery (Cx) lesions can also create a similar ECG pattern. This raises the question of whether this pattern might indicate variant coronary anatomy.

**Case Description:** A 49-year-old male patient with a history of being shot in the chest with a shotgun pellet presented with retrosternal pressure-like chest pain. An ECG taken upon presentation showed a pattern consistent with De Winter syndrome. The patient was urgently transferred to our clinic for primary percutaneous coronary intervention (PCI). Coronary angiography revealed a dissected thrombotic lesion causing 95-99% stenosis in the LAD after the first diagonal branch (D1) (Figure 1). Following percutaneous transluminal coronary angioplasty (PTCA), a drug-eluting stent (DES) was implanted. Subsequent imaging of the right coronary system revealed that the Cx had a common ostium with the RCA (Figure 2).

The patient was discharged after 48 hours of intensive care monitoring, with a planned computed tomography coronary angiography (CTCA) to accurately evaluate the course of the Cx.

**Conclusion:** It is important for interventional cardiologists to carefully evaluate coronary anatomy in the presence of special/atypical ECG patterns in acute coronary syndrome patients. Our case is notable for being the first reported case of De Winter syndrome presenting with a Cx using a common ostium with the RCA.

**Keywords:** acute coronary syndrome, De Winter's syndrome, LAD, RCx

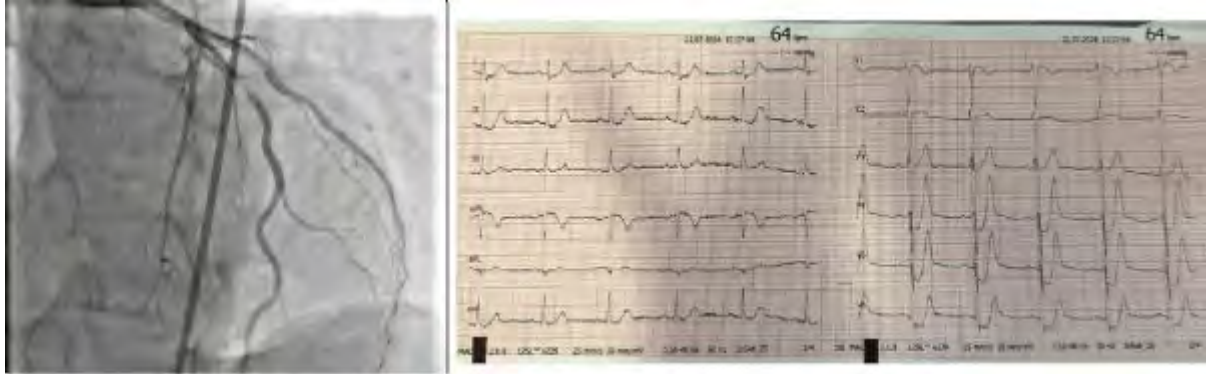


# KARDİYOVASKÜLER AKADEMİ KONGRESİ

## & INTERNATIONAL ACADEMY OF YOUNG CARDIOLOGISTS

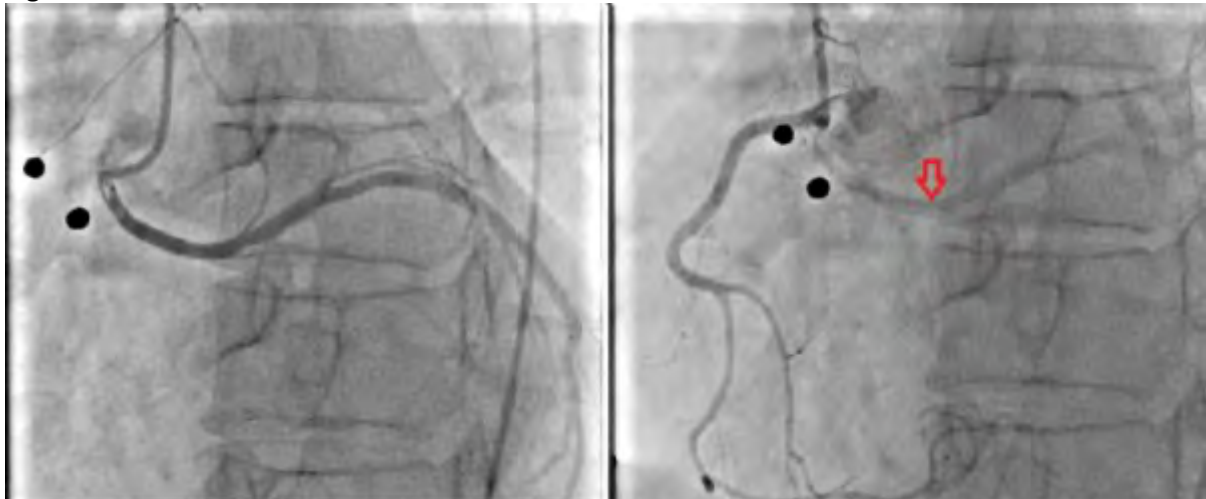
Elexus Hotel Girne, K.K.T.C.  
18-22 Eylül 2024

**Figure 1**



*Patient's pre-procedural ECG and diagnostic left coronary system angiography pose*

**Figure 2**



*Right system selective coronary angiography, revealing RCx artery*



# KARDİYOVASKÜLER AKADEMİ KONGRESİ

## & INTERNATIONAL ACADEMY OF YOUNG CARDIOLOGISTS

Elexus Hotel Girne, K.K.T.C.  
18-22 Eylül 2024

### **[OP-92] New adjunct method for successful transeptal puncture in lipomatous hypertrophy: “Smart”Touch to the interatrial septum**

Yakup Yunus Yamanturk<sup>1</sup>, Muhammed Emin Teker<sup>2</sup>, Elif Oya İlhan<sup>2</sup>, Basar Candemir<sup>2</sup>

<sup>1</sup>Cardiology Department, Artvin State Hospital, Artvin, Turkey

<sup>2</sup>Cardiology Department, Ankara University, Ankara, Turkey

**Introduction:** In electrophysiology practice, the transeptal route is commonly employed for procedures requiring access to the left atrium. Complications may arise during transeptal puncture in patients with abnormal interatrial septal anatomy/structure. Therefore, operators may require auxiliary techniques and imaging methods to facilitate safe transeptal passage.

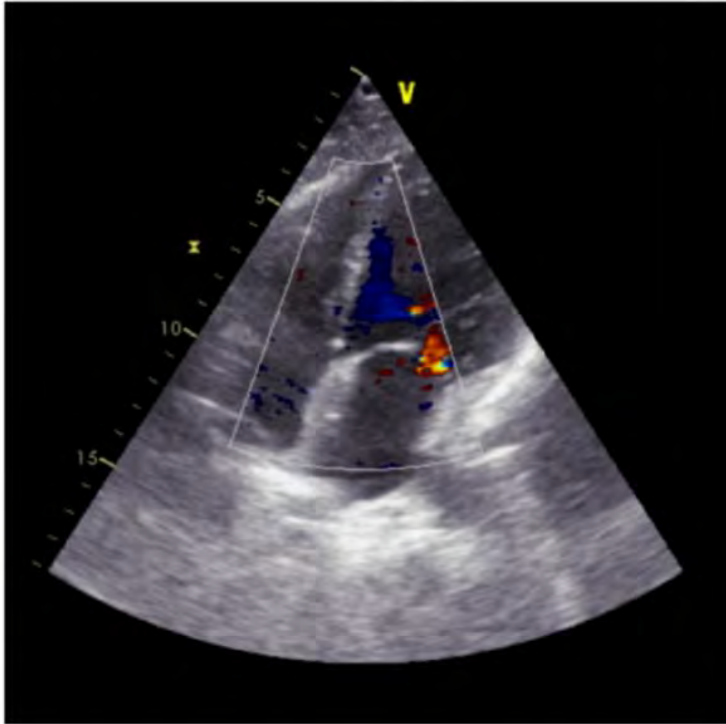
**Case:** A 51-year-old female patient presenting with symptomatic sinus bradycardia and a positive cardioinhibitory tilt test was admitted to the catheter laboratory for cardiac neural ablation (CNA) After local anesthesia and moderate sedoanalgesia, a long sheath was advanced over the venous sheaths on the right side, and the Brockenbrough transeptal needle was directed towards the fossa ovalis under appropriate fluoroscopic angles. Due to severe lipomatous hypertrophy of the interatrial septum, the first attempt at transeptal puncture was unsuccessful. Subsequently, the interatrial septum anatomy was established using Smarttouch SF (CARTO 3D mapping system, Biosense Webster, USA). The area considered safe for transeptal puncture was extensively ablated with radiofrequency and was left there for guidance. The transeptal puncture needle was then repositioned at the ablated IAS site, Brockenborough needle easily punctured IAS this time and passed inside left atrium successfully. Left and right atria were mapped and successful radiofrequency ablation was performed on the left and right atrial parasympathetic ganglion plexuses. The procedure was concluded upon observing an required increase in heart rate.

**Discussion:** This report presents a quick and safe technique where radiofrequency ablation on IAS can be a significant facilitator in patients when transeptal puncture is anticipated to be challenging due to the severely fibrotic / thickened IAS and advanced equipment and imaging via TEE/ICE was lacking. Moreover, based on this case, it can be considered that after 3D mapping of adjacent structures (e.g., aortic root) and the area where transeptal puncture will be performed, RF ablation facilitated transeptal puncture may be a substantial alternative to conventional techniques, adhering to the principle of 'minimal fluoroscopy'.

**Keywords:** Transeptal puncture, lipomatous hypertrophy, minimal fluoroscopy, radiofrequency

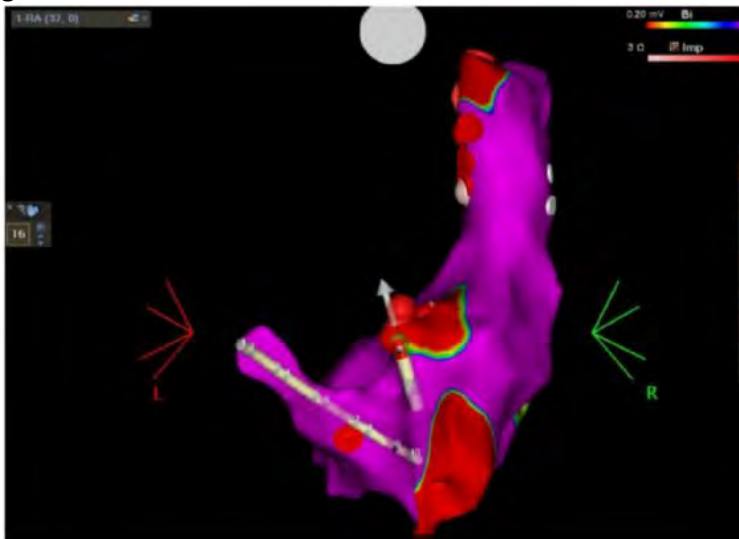
---

Figure 1



*Lipomatous hypertrophy of the interatrial septum seen in TTE*

Figure 2



*Upon encountering difficulty in crossing into the left atrium with the transseptal Brockenbrough needle, radiofrequency (RF) ablation was applied to the suitable area on the interatrial septum (IAS). Subsequently, in the follow-up attempt, the IAS passage was easily achieved (Image from the right atrial map during RF).*



# KARDİYOVASKÜLER AKADEMİ KONGRESİ

## & INTERNATIONAL ACADEMY OF YOUNG CARDIOLOGISTS

Elexus Hotel Girne. K.K.T.C.  
18-22 Eylül 2024

### **[OP-93] The real Heartbreak**

Ali Akin Önal, Nasir Ali Tokmak, Abdullah Orhan Demirtaş  
*Adana Şehir hastanesi*

#### AFTER HEART ATTACK, BROKEN HEART

Takotsubo cardiomyopathy (TCM) is an unusual type of acute cardiomyopathy characterized by apical ballooning of the left ventricle. It is typically triggered by intense physical or emotional stress. Here, we report a case study of TCM.

TCM is an acute cardiac condition mimicking acute myocardial infarction (MI) with features of left ventricular apical ballooning. It is also known as transient left ventricular apical ballooning syndrome, "stress-induced cardiomyopathy," and "broken heart syndrome." In Japanese, "tako tsubo" refers to a narrow-necked and wide-based fisherman's trap used for catching octopus, describing the visual appearance of the heart in ventriculography.

Patients with TCM present with symptoms consistent with acute coronary syndrome (ACS), such as chest pain, ST-segment elevation on electrocardiography (ECG), and elevated cardiac biomarkers. However, angiography reveals no significant coronary stenosis but demonstrates ballooning of the LV apex, which typically resolves within weeks. The syndrome is often triggered by emotional or physical stress.

**Keywords:** Takotsubo, Cardiomyopathy, Acute coronary syndrome, Broken heart syndrome, Stress cardiomyopathy





# KARDİYOVASKÜLER AKADEMİ KONGRESİ

## & INTERNATIONAL ACADEMY OF YOUNG CARDIOLOGISTS

Elexus Hotel Girne. K.K.T.C.  
18-22 Eylül 2024

### **[OP-94] A New Model for Prediction of Myocardial Injury of Non-Elective Surgery in Elderly**

Vedat Çiçek<sup>1</sup>, Mert Babaoglu<sup>2</sup>, Faysal Saylik<sup>3</sup>, Samet Yavuz<sup>2</sup>, Ahmet Furkan Mazlum<sup>6</sup>, Hatice Altinisik<sup>2</sup>, Mustafa Oguz<sup>2</sup>, Mert Ilker Hayiroglu<sup>4</sup>, Tufan Cinar<sup>5</sup>, Ulas Bagci<sup>1</sup>

<sup>1</sup>Norhwestern University Feinberg School of Medicine

<sup>2</sup>Sultan II. Abdülhamid Han Training and Research Hospital, Department of Cardiology Health Sciences University, Istanbul, Turkey

<sup>3</sup>Van Training and Research Hospital, Department of Cardiology, Health Sciences University, Van, Turkey

<sup>4</sup>Dr. Siyami Ersek Cardiovascular and Thoracic Surgery Research and Training Hospital, Istanbul, Turkey

<sup>5</sup>University of Maryland, Baltimore, USA

<sup>6</sup>Sultan II. Abdülhamid Han Training and Research Hospital, Department of General Surgery, Health Sciences University, Istanbul, Turkey

**Background:** Myocardial injury after non-cardiac surgery (MINS) is a common and serious complication, particularly in elderly patients. Studies report that the incidence of MINS in elderly patients range from 15-20 %. Currently, recommended pre-operative risk assessment models including the revised cardiac risk index (RCRI) are not very effective to predict postoperative myocardial injury after non-elective surgery, especially in elderly patients.

**Aims:** This study aimed to create a new risk prediction model to assess MINS in elderly patients and to compare it with the RCRI, a well-known pre-operative risk prediction model.

**Material and Methods:** This retrospective study included 370 elderly patients who were over 65 years and had non-elective surgery in a tertiary hospital. Each patient underwent detailed physical evaluations before the surgery. The study cohort was divided into two groups; patients who had MINS and those who did not have.

**Results:** In total, 13% (48 out of 370 patients) of the patients developed MINS. Table 1 shows the demographic characteristics and laboratory data of all patients. Multivariable analysis revealed that creatinine, lymphocyte, aortic regurgitation (moderate-severe), stroke, hemoglobin, ejection fraction and D-dimer were independent determinants of MINS. By using these parameters, a model called "CLASHED" was developed to predict postoperative MINS (Figure 1). The ROC analysis showed that the 'CLASHED' model had area under curve (AUC) of 0.788 and the RCRI had AUC of 0.611. The CLASHED model was significantly superior than the RCRI in predicting MINS ( $p < 0.05$ ), (Figure 2). Internal validation showed that the generalizability of the prediction model was good as shown in calibration plot

**Conclusion:** Our study shows that a new risk preoperative model successfully predicts MINS in elderly patients undergoing non-elective surgery. In addition, this new model is found to be superior to the RCRI in predicting MINS.


**Keywords:** Cardiac Revised Index, Elderly, Myocardial Injury, Non elective Surgery, Pre-op Risk

# KARDİYOVASKÜLER AKADEMİ KONGRESİ

## & INTERNATIONAL ACADEMY OF YOUNG CARDIOLOGISTS

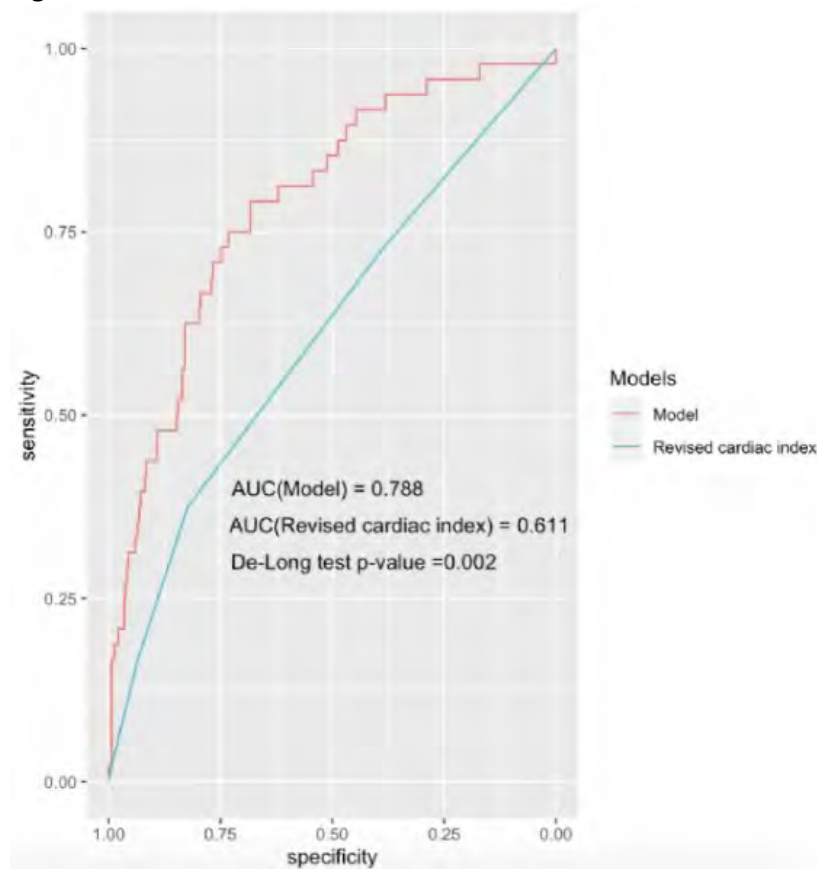
Elexus Hotel Girne, K.K.T.C.  
18-22 Eylül 2024

Figure 1



The nomogram of the CLASHED model developed for MINS prediction after non-elective surgery in elderly patients is seen.

Figure 2



Performance of of the CLASHED model and comparison of the Revised Cardiac Risk Index at non-elective surgery in elderly patients



# KARDİYOVASKÜLER AKADEMİ KONGRESİ

## & INTERNATIONAL ACADEMY OF YOUNG CARDIOLOGISTS

Elexus Hotel Girne, K.K.T.C.  
18-22 Eylül 2024

**Table 1**

	POST-OP MINS ( - ) N:322	POST-OP MINS ( + ) N:48	p.overall
Age	80.0 [73.2;86.0]	82.5 [76.0;88.0]	0.152
Sex(Male)	132 (41.0%)	19 (39.6%)	0.978
HT	234 (72.7%)	39 (81.2%)	0.278
Revised Cardiac Index	1.00 [0.00;1.00]	1.00 [0.00;2.00]	0.008
Wbc	9.10 [7.21;10.8]	9.35 [6.70;10.8]	0.828
Hgb	11.4 [10.0;12.6]	9.95 [8.90;11.5]	<0.001
Üre	48.0 [35.0;73.0]	74.0 [51.0;112]	<0.001
Ejection Fraction	60.0 [60.0;61.0]	60.0 [53.8;60.2]	0.006
Left Atrium Dimension	38.0 [36.0;40.0]	40.5 [36.8;44.0]	0.003
Aortic Regurgitation	24 (7.45%)	10 (20.8%)	0.006
ICU Inhospitalization	2.00 [0.00;3.00]	6.00 [3.00;11.5]	<0.001
Sum Inhospitalization	9.50 [7.00;12.0]	12.0 [8.75;19.0]	0.001
In-hospital Ex	45 (14.0%)	25 (52.1%)	<0.001

*Summary descriptive table by groups of Myocardial Injury After Non-cardiac Surgery*



# KARDİYOVASKÜLER AKADEMİ KONGRESİ

## & INTERNATIONAL ACADEMY OF YOUNG CARDIOLOGISTS

Elexus Hotel Girne. K.K.T.C.  
18-22 Eylül 2024

### [OP-95] The Role of ALBI Score in Predicting Thrombus Burden in Patients with Non-ST-Elevation Myocardial Infarction

Hakan Caf<sup>1</sup>, Abdullah Yıldırım<sup>2</sup>, Mükremin Coşkun<sup>2</sup>

<sup>1</sup>Cukurova State Hospital, Department of Cardiology

<sup>2</sup>Health Sciences University, Adana Research and Training Hospital, Department of Cardiology

**Introduction and Objective:** Our objective is to identify the determinants of high coronary thrombus burden in patients presenting with non-ST-elevation myocardial infarction (NSTEMI) who undergo percutaneous coronary intervention (PCI), and to examine the significance of the albumin-bilirubin score (ALBI) in this context.

**Method:** A retrospective study included 474 consecutive patients diagnosed with NSTEMI and treated with PCI at our center, following exclusion criteria. Demographic, clinical, and laboratory results were systematically recorded. Thrombus burden was graded from 1 to 5 according to the TIMI thrombus score. Based on this score, patients were divided into two groups: low thrombus burden (scores 1, 2, and 3) and high thrombus burden (scores 4 and 5).

**Results:** The mean age of patients in the high thrombus burden group was lower ( $61.1 \pm 12.3$  vs.  $57.1 \pm 11.2$ ;  $p < 0.001$ ). Laboratory parameters showed higher levels of hs-CRP ( $5$  vs.  $11$  mg/dL,  $p < 0.001$ ), hemoglobin ( $13.5 \pm 2.0$  vs.  $14.1 \pm 1.7$  g/dL;  $p = 0.001$ ), albumin ( $3.6 \pm 0.3$  vs.  $3.5 \pm 0.8$  g/dL;  $p = 0.086$ ), GFR ( $77 \pm 23$  vs.  $87 \pm 19$ ;  $p < 0.001$ ), LDL ( $120 \pm 44$  vs.  $130 \pm 41$  mg/dL;  $p = 0.015$ ), and ALBI ( $1.42$  vs.  $3.42$ ;  $p < 0.001$ ) in the high thrombus burden group. Other demographic and laboratory parameters were similar (Table 1). Binary logistic regression analysis identified GFR (OR=1.01,  $p = 0.006$ ), and ALBI (OR=7.41,  $p < 0.001$ ) as independent determinants of high coronary thrombus burden (Table 2). ROC analysis showed that an ALBI score cutoff of  $> -2.35$  (Figure 1) predicted high thrombus burden with 93.3% sensitivity and 78.7% specificity (AUC: 0.819;  $p < 0.001$ ). ALBI outperformed albumin and bilirubin when compared pairwise ( $p < 0.005$  for both) (Figure 2). No significant differences were found in no-reflow phenomenon or in-hospital mortality between groups divided by the ALBI cutoff. Adjusted analysis for in-hospital mortality showed ALBI (a-OR=8.15;  $p < 0.001$ ) as an independent determinant (Table 3).

**Discussion and Conclusion:** The main findings of this study are as follows: hemoglobin level, GFR, and ALBI are identified as independent determinants of high coronary thrombus burden in patients hospitalized with NSTEMI and treated with PCI. ALBI score is superior to albumin and bilirubin in predicting coronary thrombus burden. Additionally, ALBI score is an independent determinant of in-hospital mortality. Consequently, ALBI score emerges as a readily available and reliable parameter for assessing high coronary thrombus burden and the risk of in-hospital mortality in NSTEMI patients.

**Keywords:** Non-ST-Elevation Myocardial Infarction (NSTEMI), In-Hospital Mortality, hs-CRP/Albumin Ratio, SYNTAX Score



# KARDİYOVASKÜLER AKADEMİ KONGRESİ

## & INTERNATIONAL ACADEMY OF YOUNG CARDIOLOGISTS

Elexus Hotel Gıme. K.K.T.C.  
18-22 Eylül 2024

Tablo 1 ve 2

Table 1. Baseline clinical, laboratory, and angiographic data of the study population.

Variables	Total (n=428)	Low Thrombotic Burden (n=230)	High Thrombotic Burden (n=204)	p*
Age, years	55.12(11.9)	51.14(12.3)	57.14(11.2)	<0.001
Gender, female, n (%)	202 (47.2)	94 (40.9)	108 (52.9)	0.145
Hypertension, n (%)	221 (51.6)	111 (48.3)	110 (54.4)	0.365
Diabetes mellitus, n (%)	118 (27.6)	64 (27.8)	54 (26.5)	0.140
Smoking, n (%)	115 (26.9)	59 (25.7)	56 (27.3)	0.199
Glucose, mg/dL	100(51)	110(48)	90(44)	0.215
Hs-CRP, mg/dL	4.15(3.9)	5.13(4.1)	3.11(2.7)	<0.001
Hemoglobin, g/dL	15.8(1.5)	15.5(1.5)	16.1(1.7)	0.004
Albumin, g/dL	3.5(0.6)	3.4(0.7)	3.6(0.5)	0.060
Mineral, mg/dL	8.7(0.44)	8.5(0.48)	8.9(0.39)	<0.001
GFR, mL/min/1.73 m <sup>2</sup>	40(21)	39(21)	41(20)	<0.001
Creatinine, mg/dL**	1.04(0.30)	1.10(0.31)	0.91(0.25)	0.002
Sodium, mEq/L	136.9(5.7)	136.2(5.1)	138.0(6.1)	0.187
hs-cTnI, ng/mL	17.1(3.5)	17.2(5.0)	17.1(3.5)	0.115
hs-MB, ng/mL	11.9 (8.5-14.9)	11.5 (8.5-14.9)	12.4 (8.5-11.5)	0.714
Left carotid int.	185(43)	101(44)	289(14)	0.135
LDL, mg/dL	125(41)	120(44)	130(41)	0.015
Triglycerides, mg/dL	154(48)	154(48)	152(48)	0.791
White blood cell count, 10 <sup>9</sup> /L	11.8(4.5)	12.8(4.5)	11.1(4.4)	0.090
Platelet count, 10 <sup>9</sup> /L	156(45)	156(44)	155(45)	0.540
Ash score	-1.1(1.9)	-2.4(1.8)	-1.2(1.4)	<0.001
Ischemic-related artery, n (%)				0.045
LAD	144(51.3)	101(43.5)	139(68.2)	

Di	154 (33.6)	90 (39.1)	94 (45.8)
ILVA	34 (15.6)	30 (13.0)	36 (17.5)
WVFAC score	16.4(1.7)	16.5(1.9)	16.9(1.4)
Ischemic precondition, n (%)	4 (0.9)	1 (0.4)	3 (1.5)
No-reflow phenomenon, n (%)	95 (28.0)	44 (19.1)	51 (25.1)
ST-segment depression, n (%)	194 (44.3)	91 (39.6)	103 (50.5)
In-hospital mortality, n (%)	45 (9.3)	25 (10.9)	20 (9.8)

Data are expressed as number (n), mean ± standard deviation, or median (interquartile range) (IQR). Statistical analysis was performed using independent samples t-test or Mann-Whitney U-test for continuous variables, and chi-square test or Fisher exact test for categorical variables, as appropriate. \*p<0.05 was considered significant. \*\*Estimated using the MDRD formula. Abbreviations: ALB: Albumin; WVFAC score, WVFAC; hs-CRP:hs-CRP; GFR: Glomerular Filtration Rate; hs-MB: High-Sensitivity C-Reactive Protein; hs-cTnI: High-Sensitivity Cardiac Troponin-I; LDL: Low-Density Lipoprotein.

Table 2. Univariate and multivariate regression analysis of factors associated with high coronary thrombotic burden.

Variables	Univariate analysis		Multivariable analysis	
	OR (95% CI)	p*	OR (95% CI)	p*
Female Gender	0.31 (0.05-2.04)	0.135	0.31 (0.03-3.03)	0.205
Age	0.97 (0.96-0.98)	<0.001	0.97 (0.97-1.00)	<0.001
hs-CRP	0.62 (0.42-0.90)	<0.001	1.04 (1.00-1.09)	0.008
Hemoglobin	0.38 (0.07-1.57)	0.001	1.09 (0.96-1.23)	0.182
LDL	0.81 (0.68-1.02)	0.028	1.00 (0.99-1.01)	0.470
CRP	0.81 (0.68-1.02)	0.009	0.92 (0.92-1.01)	0.142
Ischemic-related artery				
Left anterior descending	0.37 (0.04-2.50)	0.135		
Circumflex	0.75 (0.43-1.33)	0.318		
Right	1.00 (ref)			
No-reflow phenomenon	0.38 (0.25-1.02)	0.017		
WVFAC score	0.93 (0.99-1.02)	0.029		
In-hospital mortality	0.77 (0.41-1.42)	0.400		
Ash score	1.41 (0.88-1.33)	0.001	1.15 (0.99-1.33)	<0.001

\*p<0.05 was considered significant. Abbreviations: ALB: Albumin; WVFAC score, WVFAC; hs-CRP:hs-CRP; GFR: Glomerular Filtration Rate; hs-MB: High-Sensitivity C-Reactive Protein; hs-cTnI: High-Sensitivity Cardiac Troponin-I; LDL: Low-Density Lipoprotein; CRP: C-reactive protein.

# KARDİYOVASKÜLER AKADEMİ KONGRESİ

## & INTERNATIONAL ACADEMY OF YOUNG CARDIOLOGISTS

Elexus Hotel Gıme, K.K.T.C.  
18-22 Eylül 2024

Tablo 3 ve Grafikler

Variable	Total (n=1234)	ADP (< 2.0) (n=684)	ADP (> 2.0) (n=550)	p <sup>1</sup>
Age (years)	54.4(±7.1)	54.3(±6.9)	54.5(±7.3)	0.996
Male sex, n (%)	41 (8.4)	24 (3.5)	17 (3.1)	< 0.01
Diabetes mellitus, n (%)	148 (12.0)	78 (11.4)	70 (12.7)	0.687
LDL-C (mmol/L)	194 (15.6)	101 (14.7)	93 (16.8)	< 0.001
HDL-C (mmol/L)	54 (4.3)	28 (4.1)	26 (4.7)	0.304
LDL-C/HDL-C ratio	3.6 (1.1)	3.5 (1.0)	3.6 (1.1)	0.902
LDL-C/HDL-C ratio	3.6 (1.1)	3.5 (1.0)	3.6 (1.1)	0.902

Variable	Multivariate analysis		p <sup>1</sup>
	OR	95% CI	
Age (years)	1.01	0.99-1.03	0.289
Male sex	0.59	0.19-1.83	0.389
LDL-C (mmol/L)	0.73	0.71-0.75	< 0.001

Abbreviations: ADP, Atherothrombotic Disease Probability; HDL-C, High-Density Lipoprotein Cholesterol; LDL-C, Low-Density Lipoprotein Cholesterol; OR, Odds Ratio.




Figure 3. Histogram showing the distribution of LDL-C levels in mmol/L.




Figure 4. ROC Curve, AUC, and BPLD of Predicting LDL-C Levels Using Age and ADP Score.



# KARDİYOVASKÜLER AKADEMİ KONGRESİ

## & INTERNATIONAL ACADEMY OF YOUNG CARDIOLOGISTS

Elexus Hotel Girne, K.K.T.C.  
18-22 Eylül 2024

### [OP-96] Prodromal Symptoms in Patients Presenting with Acute Coronary Syndrome

Arzu Rzayeva, Duygu Malkoçoğlu, Faruk Bulut, Selin Arca, Buket Hancer, Nimet Selin Aydın, Elton Soydan, Mehdi Zoghi  
Ege University, Cardiology Department, Izmir

**Background and Aim:** Prodromal symptoms (PS) are underestimated by patients prior to acute coronary syndromes (ACS). However, PS may be important warning signs for ACSs. In this study, we evaluated the most common PS before ACS, clinical and demographic characteristics of the patients, and the time to hospital arrival.

**Methods:** In the study, 100 consecutive patients with ACS and PS were included from January to December 2023. Statistical methods used included the chi-square test and t-test.

**Results:** In a sample of 100 patients, 58% were males, 42% were females, with a mean age of  $60 \pm 10$  years. 61% of patients were diagnosed with ST-segment elevation myocardial infarction (STEMI) (Table-1). Typical angina pectoris was the most common symptom at hospital admission. The most common PS was shortness of breath, while back and left pectoral pain were the most common age-dependent PS (Table-2). An increase in the frequency of dyspnea among PS was observed with increasing age. Along with PS, the 35% of patients had anxiety, 23% depression and 23% insomnia problems. The rate of patients who had a health care provider in their family was 44%. But only 4% consulted their PS with them. The average hospital arrival time for all patients was  $3 \pm 1$  hours.

**Conclusion:** The most commonly observed prodromal symptom was shortness of breath. Back pain and left pectoral pain were identified as the most common age-dependent symptoms. An increase in the frequency of dyspnea among PS was observed with increasing age. The study also shows that despite the presence of healthcare providers in the family, few patients consulted them about their PS, highlighting the need for increased awareness and education. Increasing patients' awareness of symptoms defined as prodromal signs seems to be extremely important. Monitoring these symptoms closely and intervening early may reduce hospital arrival time and improve patient outcomes.

**Keywords:** ACS, chest pain, prodromal symptoms

#### Age-Dependent prodromal symptoms

Characteristic	Value
Gender	58% Male, 42% Female
Mean Age	$60 \pm 10$ years
STEMI	61%
Non-STEMI	39%
Hypertension	45%
Diabetes Mellitus	30%
Hyperlipidemia	25%
Chronic Kidney Disease	12%
Current Smoker	40%



# KARDİYOVASKÜLER AKADEMİ KONGRESİ

## & INTERNATIONAL ACADEMY OF YOUNG CARDIOLOGISTS

Elexus Hotel Girne, K.K.T.C.  
18-22 Eylül 2024

### Age-Independent prodromal symptoms

Symptom	Prevalence
Shortness of breath	38%
Neck/Throat Pain	33%
Fatigue	32%
Jaw/Teeth Pain	29%
General Chest Pain	28%
Cough	28%
Discomfort in arms	26%
Anxiety	23%
Tingling in hands	18%
Dizziness	17%
Indigestion	13%
Sleep disturbances	13%
Numbness in arms	11%
Headache frequency changes	11%
Abdominal pain	10%
Loss of appetite	10%
Insomnia	10%

**Table-1: Demographic and Clinical Findings of the Study Population**

Characteristic	Value
Gender	58% Male, 42% Female
Mean Age	60±10 years
STEMI	61%
Non-STEMI	39%
Hypertension	45%
Diabetes Mellitus	30%
Hyperlipidemia	25%
Chronic Kidney Disease	12%
Current Smoker	40%





# KARDİYOVASKÜLER AKADEMİ KONGRESİ

## & INTERNATIONAL ACADEMY OF YOUNG CARDIOLOGISTS

Elexus Hotel Girne, K.K.T.C.  
18-22 Eylül 2024

### **[OP-97] MANAGEMENT OF CORONARY PERFORATION: A CASE STUDY AND REVIEW OF CURRENT APPROACHES**

Dr. Ridvan Cam, Dr. Günseli Miray Ozdemir, Uzm. Dr. Mustafa Azmi Sungur, Doç. Dr. Baris Simsek, Uzm. Dr. Fatma Can, Doç. Dr. Mehmet Fatih Yilmaz, Doç. Dr. Gonul Zeren, Doç. Dr. Ilhan Ilker Avcı, Prof. Dr. Can Yucel Karabay

Health Sciences University Dr. Siyami Ersek Thoracic and Cardiovascular Surgery Training and Research Hospital

#### **ABSTRACT**

Coronary perforation, though a rare complication in percutaneous coronary intervention (PCI), can be life-threatening. This article presents a detailed case of a 71-year-old male who developed a coronary perforation during PCI. We discuss the clinical presentation, management strategies, and relevant risk factors, alongside a review of current methods to control and treat coronary perforation. Emphasis is placed on the implementation of specific interventional techniques such as balloon tamponade, autologous tissue embolization, and coil embolization to manage coronary perforations.

**Key words:** Perforation, Coil, Embolization

#### **INTRODUCTION**

Coronary perforation has an estimated incidence of 0.2-0.5% in all PCI procedures, with an increased likelihood during chronic total occlusion (CTO) interventions (4-9%). Due to the complexity and potential severity, including cardiac tamponade, rapid identification and management of coronary perforation is essential.

#### **CASE PRESENTATION**

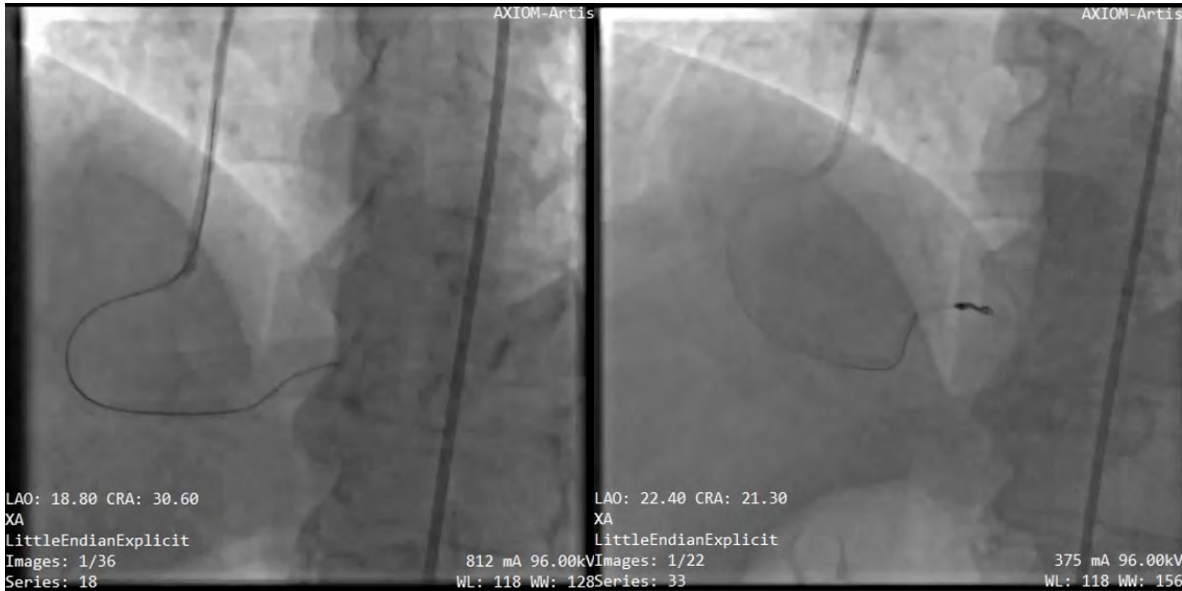
A 71-year-old male with no history of hypertension, diabetes, or known cardiac disease presented with exertional chest pain. Initial physical examination and routine tests, including electrocardiogram and transthoracic echocardiography (TTE), showed normal findings except for mild mitral regurgitation and a positive stress test. Following coronary angiography, percutaneous coronary intervention (PCI) was performed on the left circumflex artery (CX) and right coronary artery (RCA), which showed chronic total occlusion (CTO).

During the RCA PCI, distal branch rupture with contrast extravasation was noted, leading to ventricular fibrillation (VF), which was treated with defibrillation. Despite prolonged balloon tamponade, contrast leakage persisted. Autologous subcutaneous fat and coil embolization techniques were subsequently utilized, achieving full patency and resolution of contrast extravasation. Post-procedure follow-up indicated no pericardial effusion, and the patient was discharged on the third day without complications.

# KARDİYOVASKÜLER AKADEMİ KONGRESİ

## & INTERNATIONAL ACADEMY OF YOUNG CARDIOLOGISTS

Elexus Hotel Girne, K.K.T.C.  
18-22 Eylül 2024



### DISCUSSION

Coronary perforation can manifest in three types: large vessel perforation, distal vessel perforation, and collateral vessel perforation. Type III perforations, which affect larger vessels, carry the highest mortality rates and risk for cardiac tamponade. This case aligns with the literature that highlights increased risk associated with complex PCI in CTO cases.

#### Coronary perforation: Ellis classification

##### Severity

Class I	Crater extending outside lumen only	I	
Class II	Pericardial or myocardial blush with < 1 mm exit hole	II	
Class III	Contrast jet through > 1 mm exit hole	III	
Class III cavity spilling	Perforation into anatomic cavity	III	

Risk factors include advanced age, female sex, calcified or tortuous vessels, high-pressure balloon inflation, and use of hydrophilic or stiff guidewires. A careful procedural approach, including real-time TTE, immediate hemodynamic support, and preparedness for emergency pericardiocentesis, is crucial.



# KARDİYOVASKÜLER AKADEMİ KONGRESİ

## & INTERNATIONAL ACADEMY OF YOUNG CARDIOLOGISTS

Elexus Hotel Girne, K.K.T.C.  
18-22 Eylül 2024

### Management Techniques:

1. Balloon Tamponade: A low-pressure balloon inflation can be applied proximal to the perforation site, effective for small and distal ruptures.
2. Autologous Fat Tissue Embolization: This technique, involving fat tissue harvested from the patient, helps seal distal perforations and promotes hemostasis.
3. Coil Embolization: Particularly useful in Type III perforations, coils induce thrombogenesis and can be deployed with precision to prevent retraction and displacement.
4. Thrombin Injection and Covered Stent Placement: Covered stents may be utilized in larger vessel perforations, effectively reducing the need for emergency surgery.

### CONCLUSION

Coronary perforation management requires tailored strategies based on the type and location of perforation, vessel size, and patient condition. This case demonstrates the effective use of balloon tamponade, autologous fat embolization, and coil embolization in achieving hemostasis in a Type III perforation. A multidisciplinary approach and prompt intervention remain crucial in mitigating the risks associated with this rare but severe complication. Further research is warranted to refine these techniques and improve patient outcomes in complex coronary interventions.

### REFERENCES

- Fujino, Y., Attizzani, G. F., Tahara, S., et al. (2015). Management of Coronary Perforation: Importance of Prompt Control of Coronary Hemorrhage. *Journal of the American College of Cardiology: Cardiovascular Interventions*, 8(8), 1156-1165.
- Shah, R., Patel, T., & Tripathi, B. (2018). Current Approaches in the Management of Coronary Artery Perforations. *Catheterization and Cardiovascular Interventions*, 91(7), 1309-1317.
- Daggubati, R., & Fearon, W. F. (2021). Complications in Chronic Total Occlusion Percutaneous Coronary Intervention: Prevention and Management. *Circulation: Cardiovascular Interventions*, 14(4), e009242.
- Elsayed, M., & Christopoulos, G. (2016). Contemporary Management of Coronary Perforations. *Interventional Cardiology Clinics*, 5(3), 353-362.
- Motta-Leal-Filho, J. M., Messina, L. M., & Neves, J. B. (2019). Incidence, Classification, and Management of Coronary Artery Perforations During Percutaneous Coronary Interventions. *Cardiovascular Revascularization Medicine*, 20(8), 795-800.
- Witzke, M., de Silva, R., & Wijesinghe, N. (2022). Advances in the Management of Coronary Perforation: A Case-based Review. *Heart, Lung and Circulation*, 31(5), 681-688.





# KARDİYOVASKÜLER AKADEMİ KONGRESİ

## & INTERNATIONAL ACADEMY OF YOUNG CARDIOLOGISTS

Elexus Hotel Girne, K.K.T.C.  
18-22 Eylül 2024

### **[OP-98] CORONARY FISTULA COIL EMBOLIZATION: A CASE REPORT AND REVIEW OF TREATMENT APPROACHES**

Dr. Günseli Miray Özdemir, Dr. Rıdvan Çam, Uzm. Dr. Mustafa Azmi Sungur, Doç. Dr. Barış Şimşek, Uzm. Dr. Fatma Can, Doç. Dr. Mehmet Fatih Yılmaz, Doç. Dr. Gönül Zeren, Doç. Dr. İlhan İlker Avcı, Prof. Dr. Can Yücel Karabay

Health Sciences University Dr. Siyami Ersek Thoracic and Cardiovascular Surgery Training and Research Hospital

#### **ABSTRACT**

This case report discusses a 69-year-old female patient with a persistent coronary fistula between the left anterior descending (LAD) artery and pulmonary artery (PA) following an attempted closure at an external center. Surgical closure was advised following continued leakage. After thorough multidisciplinary assessment, percutaneous coil embolization was deemed the preferred approach. This paper reviews coronary artery fistula (CAF) pathology, diagnostic modalities, and various treatment options while presenting a successful intervention through coil embolization. The procedure achieved complete occlusion, with no complications observed postoperatively.

**Key Words:** Coil, Embolization, Fistulas

#### **INTRODUCTION**

Coronary artery fistulas (CAFs) are rare anomalies of the coronary vasculature, with an incidence of 0.1-0.2%. Typically, CAFs result from congenital malformations, though they may also develop as acquired anomalies due to trauma or iatrogenic causes. CAFs most commonly connect coronary arteries to adjacent cardiac chambers or vascular structures, bypassing capillary networks and resulting in high-volume shunting. This condition can lead to symptoms and complications, especially with larger fistulas, necessitating intervention. We report on a case managed with percutaneous coil embolization, outlining the clinical decision-making, procedural details, and relevant literature.

#### **CASE PRESENTATION**

A 69-year-old female patient presented with chest pain and dyspnea. Her history included hypertension and diabetes mellitus, and she was a non-smoker. The patient had previously undergone closure of a LAD-PA fistula at an external center in 2020. Coronary angiography in 2021 revealed persistent leakage, prompting recommendations for surgical closure. The patient was referred to our center, where, following a comprehensive evaluation, the heart team elected for percutaneous coil embolization.

Initial Assessment and Diagnostic Findings:

- Physical Examination: Normal findings without any acute distress.
- Electrocardiogram (ECG): Sinus rhythm with a heart rate of 66 beats per minute.
- Transthoracic Echocardiography (TTE): Left ventricular ejection fraction of 60%, mild left atrial enlargement, and no pericardial effusion.
- Blood Tests: All parameters were within normal limits.
- Myocardial Perfusion Scan (MPS): A reversible perfusion defect was identified in the anterior wall, consistent with ischemic changes related to the fistula.

Coronary Angiography Findings:

The angiographic study confirmed a patent fistula between the LAD and PA, with significant flow through the fistulous connection.

#### **INTERVENTION**





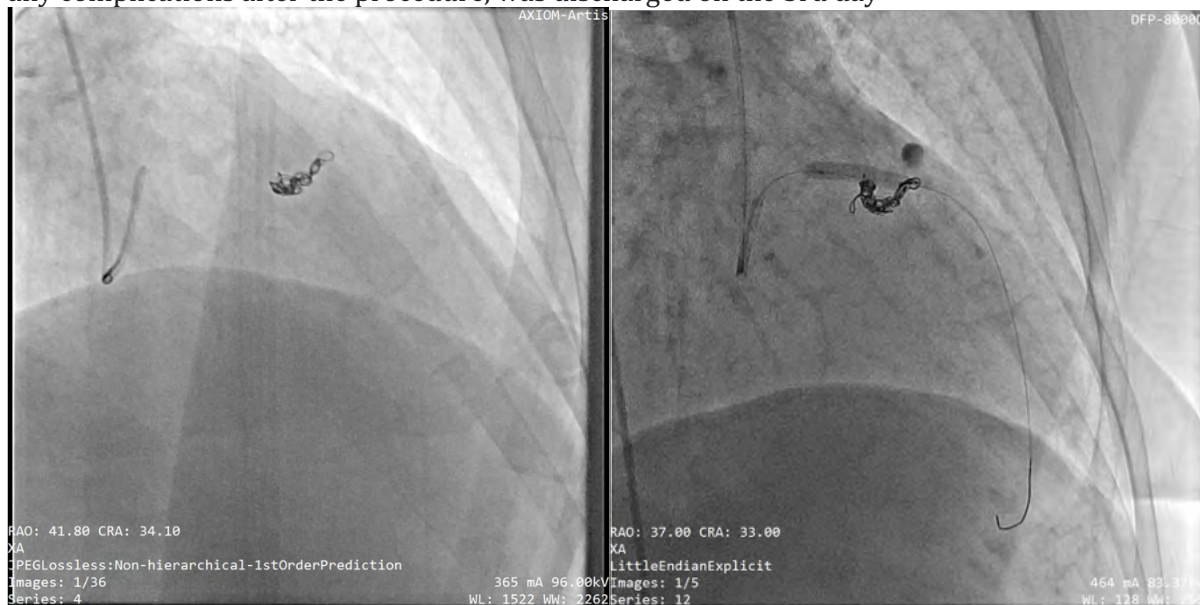# KARDİYOVASKÜLER AKADEMİ KONGRESİ

## & INTERNATIONAL ACADEMY OF YOUNG CARDIOLOGISTS

Elexus Hotel Girne, K.K.T.C.  
18-22 Eylül 2024

The patient was discussed in the Cardiology - Cardiovascular Surgery Council. The Heart Team decided on the percutaneous coiling of the coronary fistula. The patient was admitted for coil embolization. A 7F

sheath was inserted into the femoral artery, and the LMCA was engaged using an EBU4 guiding catheter. The previously placed coil embolization material was observed to be located proximally in Septal 1. An attempt was made to wire Septal 1, but the wire kept redirecting towards the main LAD branch. To facilitate the wire's direction into Septal 1, a balloon was parked in the LAD for support. After successfully directing the wire into Septal 1, an attempt was made to advance the microcatheter distally into Septal 1. However, due to obstruction by the previous coil material, the microcatheter could not advance distally and was parked proximally in Septal 1. Boston Scientific IDC coils were sequentially placed: 1 unit of 4x8 and 2 units of 3x6. Minimal protrusion of the coil into the LAD was observed. A 4.0x16 mm Firehawk DES was implanted in the LAD, crossing over SEPTAL 1. The fistula was observed to be completely occluded. The patient, who did not experience any complications after the procedure, was discharged on the 3rd day



### DISCUSSION

CAFs encompass abnormal coronary connections, with coronary-pulmonary artery fistulas representing 15-20% of cases. The pathophysiology involves blood shunting through low-resistance pathways, leading to potential complications. CAF classification based on size and symptoms informs management strategies, typically necessitating intervention for symptomatic or large fistulas.

Diagnostic approaches, including cardiac catheterization and CT angiography, are crucial for anatomical assessment and procedural planning. This patient underwent comprehensive imaging, highlighting the fistula's hemodynamic significance.

Indications for Treatment:

Symptomatic fistulas, arrhythmia, endarteritis risk, and ventricular dysfunction are key indicators for intervention. Treatment modalities include surgical closure, transcatheter interventions, and, in select cases, stent grafting.

Percutaneous vs. Surgical Approach:

Percutaneous approaches, including transarterial and transvenous catheterization, are increasingly favored due to lower complication rates and efficacy in achieving occlusion. In our patient, a

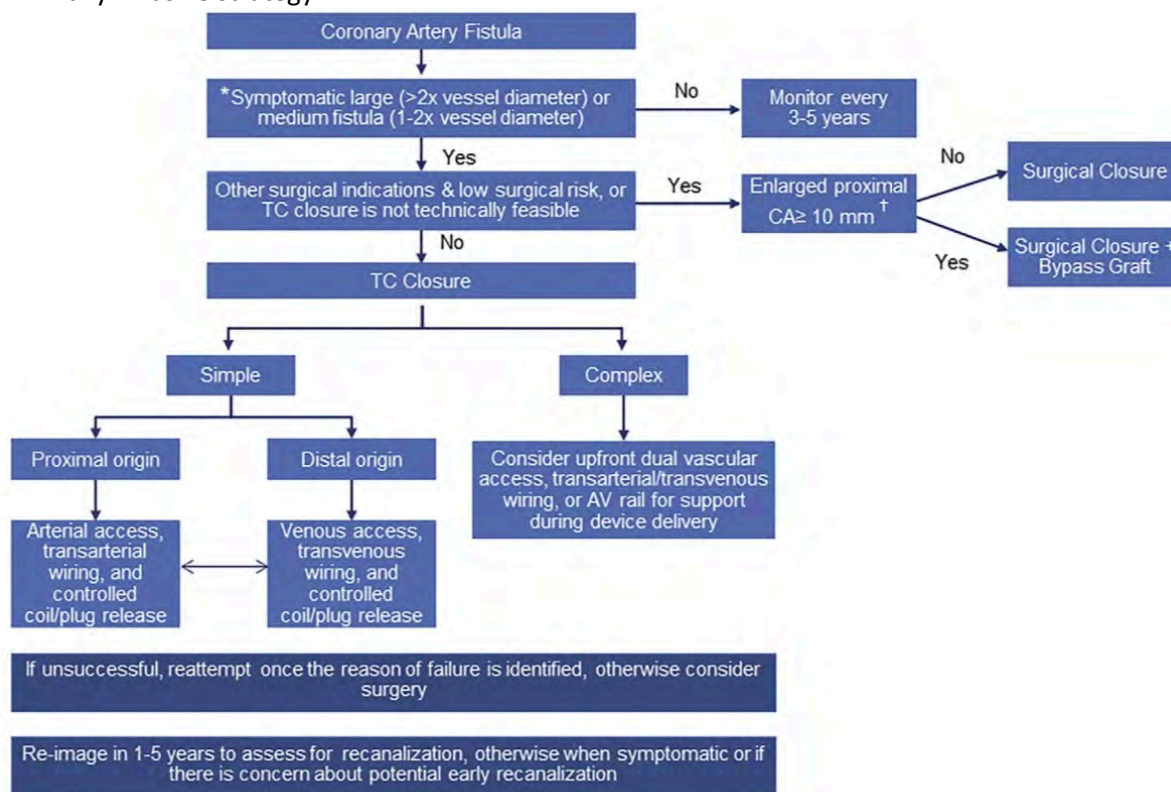


# KARDİYOVASKÜLER AKADEMİ KONGRESİ

## & INTERNATIONAL ACADEMY OF YOUNG CARDIOLOGISTS

Elexus Hotel Girne, K.K.T.C.  
18-22 Eylül 2024

transarterial approach with coil embolization proved effective, demonstrating the utility of this minimally invasive strategy.



### CONCLUSION

CAFs, while rare, pose significant clinical risks and require individualized management. Percutaneous coil embolization offers a promising option for symptomatic CAFs, as seen in this case. The procedure's success and low complication rate underscore its viability as an alternative to surgery in carefully selected cases.

### REFERENCES

- European Heart Journal - Case Reports. Minimally invasive coil embolization for significant left-to-right shunts due to giant coronary-to-pulmonary artery fistulas: a case report. Eur Heart J Case Rep. Available from: <https://academic.oup.com> [2].
- Texas Heart Institute Journal. Transcatheter Coil Embolization in 17 Patients with 22 Coronary Artery Fistulas. Tex Heart Inst J. Available from: <https://meridian.allenpress.com> [2].
- Cardiovascular Journal. Percutaneous closure of coronary artery fistula with detachable coil: a case study. Cardiovasc J. Available from: <https://imsear.searo.who.int> [2].
- Texas Heart Institute Journal. Percutaneous Hydrogel Coil Embolization of Aneurysms and Coronary Artery Fistulae in Congenital Heart Disease. Tex Heart Inst J. Available from: <https://meridian.allenpress.com> [2].
- Revista Española de Cardiología. Percutaneous Occlusion With Coils of Coronary Artery Fistulas in Adults. Rev Esp Cardiol. Available from: <https://www.revespcardiol.org> [2].



# KARDİYOVASKÜLER AKADEMİ KONGRESİ

## & INTERNATIONAL ACADEMY OF YOUNG CARDIOLOGISTS

Elexus Hotel Girne, K.K.T.C.  
18-22 Eylül 2024

- European Heart Journal - Case Reports. Percutaneous coil embolization and stent implantation for multiple coronary-to-pulmonary artery fistulas with giant coronary aneurysms: a case report. Eur Heart J Case Rep. Available from: <https://academic.oup.com> [?].



# POSTER PRESENTATION







# KARDİYOVASKÜLER AKADEMİ KONGRESİ

## & INTERNATIONAL ACADEMY OF YOUNG CARDIOLOGISTS

Elexus Hotel Girne, K.K.T.C.  
18-22 Eylül 2024

### **[PP-01] As a Rare Case, Acute Inferior ST-Elevation Myocardial Infarction Due to Wraparound Left Anterior Descending Artery**

Tuba Ekin

*Kırşehir Ahi Evran University Training and Research Hospital*

**Introduction:** Most of the time in case of myocardial infarction, ecg findings give us information about culprit lesion. Most inferior ST-elevation myocardial infarctions (STEMIS) result from occlusion of the dominant right coronary artery. But there are some exceptions.

**Case presentation:** A 60-year-old female patient was admitted to our hospital with a complaint of increasingly severe central chest pain. He was hypertensive and had diabetes for 8 years. An electrocardiogram at admission showed ST-segment elevation in inferior leads (II, III, augmented vector foot {aVF}) and ST-segment depression in V2 (Figure 1).

The patient was immediately taken to the catheter laboratory. Coronary angiography revealed a left dominant system. It was observed that there was 100% stenosis in the most distal part of the left anterior descending artery. It was observed that the right coronary artery was not dominant and there was no stenosis. Percutaneous coronary intervention (PCI) was performed on the LAD (Figure 2).

**Discussion:** While 80% of inferior STEMI originates from the dominant right coronary artery, the dominant left circumflex artery is involved in only 18% of cases and rarely envelops the left anterior descending artery, causing inferior STEMI. Occlusion of the LAD artery in the inferior lead indicating STEMI and anterior myocardial infarction is an unusual presentation of ST segment elevation. This anatomical definition is clinically important due to the high long- and short-term mortality and morbidity.

**Conclusions:** Although there are not enough case series yet, every cardiologist should keep in mind wraparound lad occlusion, which is a rare but common condition.

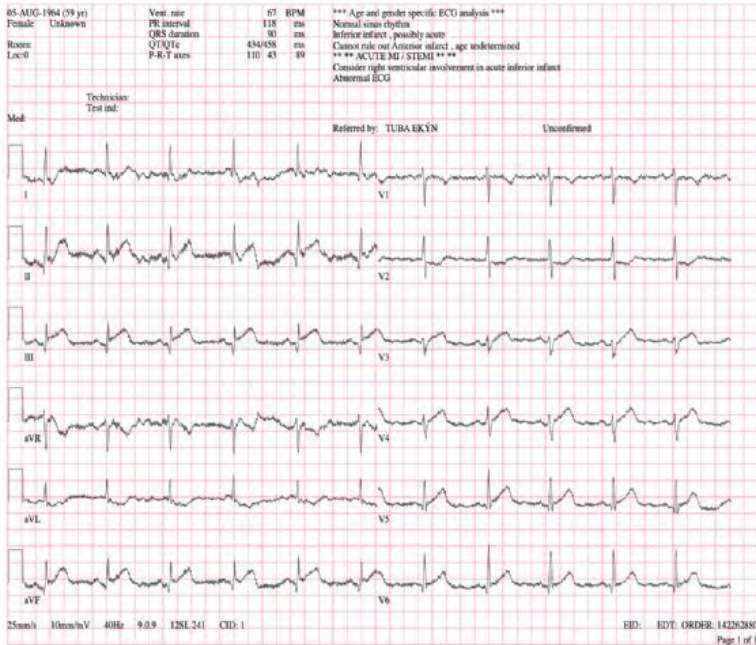
**Keywords:** mimicking st elevation, lad occlusion, inferior st elevation, wraparound left anterior descending artery

# KARDİYOVASKÜLER AKADEMİ KONGRESİ

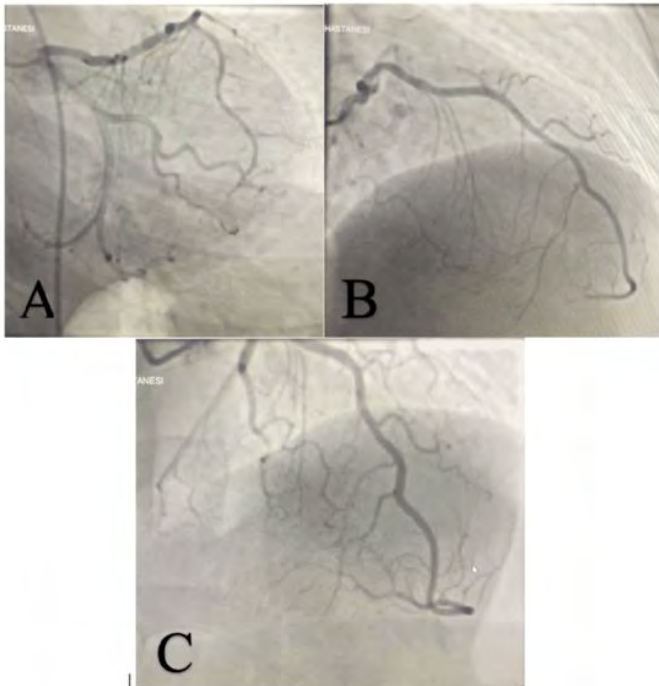
## & INTERNATIONAL ACADEMY OF YOUNG CARDIOLOGISTS

Elexus Hotel Girne, K.K.T.C.  
18-22 Eylül 2024

Figure 1



Electrocardiogram on admission showing inferior ST elevation in lead II, III, aVF  
Figure 2 Coronary angiogram shows wraparound LAD artery and LAD lesion



(A)- distal LAD lesion and LCx artery, (B) - wraparound LAD artery and distal lesion (C) - wraparound LAD artery and post CAG to LAD (culprit vessel) LAD: left anterior descending; LCx: left circumflex; RCA: right coronary artery; CAG: coronary angiography



# KARDİYOVASKÜLER AKADEMİ KONGRESİ

## & INTERNATIONAL ACADEMY OF YOUNG CARDIOLOGISTS

Elexus Hotel Girne, K.K.T.C.  
18-22 Eylül 2024

### [PP-02] Atrioventricular Heart Block Post Covid-19 Biontech Vaccine: A Case Report

Tuba Ekin<sup>1</sup>, Muhammet Uyanık<sup>2</sup>

<sup>1</sup>Kirsehir Ahi Evran University Training and Research Hospital

<sup>2</sup>Carsamba State Hospital, Samsun

**Introduction:** Coronary outbreak started in late in Wuhan, China. Unfortunately, this is a new viral disease, and we do not know about it. A study in Wuhan reported the frequency of acute myocardial damage about 7.2 % and cardiac arrhythmias about 16.7%. However, severe bradyarrhythmias such as third-degree atrioventricular block (AVB) have been relatively uncommon.

**Case presentation:** 56 years old female was admitted to our clinic with nausea, fatigue, dizziness. Patient did not have any additional disease. On the first electrocardiography (ECG) showed Mobitz type I AV block (Wenckebach) (Figure 1). On another ECG performed during monitoring, it was seen that 2:1 AV block is developed (Figure 2). Coronary angiogram result indicated that RCA and Cx branches were normal but there was 40-50% narrowness on the LAD proximal part. FFR is performed to this lesion. It was tested 0.88 and the lesion is evaluated as non-critical. Not having similar symptoms before, as differential diagnosis for the underlying cause of patient's sinus bradycardia and sinus pause, situations such as SARS-CoV2 infection, myocardial ischemia/infarction, myocarditis, cardiomyopathies, hypoxia, electrolyte, drug toxicity (i.e. calcium channel blockers, beta blockers) and increased vagal tone are examined. Prior to application, she was not using any negative inotropes and did not have such symptoms to suspect SARS-CoV2 infection or other aetiologies. When investigated further with anamnesis, it is found out that the patient was vaccinated 6 days ago due to Covid-19 pandemic. Since there were no convincing evidence to indicate other aetiologies, it is proposed that the situation was due to the vaccine, like AV blocks after SARS-CoV2 infection shown with various case presentations before.

**Conclusions:** In present publications, there are well documented cardiac complications of Covid-19 infection with myocarditis, cardiac insufficiency and coronary artery thrombosis or acute coroner syndrome originated from plaque ruptures related to SARS-CoV2. However, there are increasing number of evidence showing that arrhythmias are also one of the main complications. It is shown that various infections such as viral myocarditis and severe acute respiratory syndrome are the reasons for the cardiac conduction system disease with SA node and AV node. It is not yet determined that whether the underlying mechanism of cardiac arrhythmias in Covid-19 is a result of myocardial and/or conduction system damage or the virus has a direct arrhythmogenic impact. By this time, even though bradycardia and AV blocks related to Covid-19 infection are submitted, there are no reports related to the vaccine. In our case, there is AV block developed after the vaccine despite normal primer tests including reported normal past of conduction system, absence of nodal blocker agents and EKG's, electrolytes, and echocardiography. In this respect, it has the characteristics of the first case reported.

**Keywords:** Arrhythmia, AV block, bradycardia, Covid-19 Vaccine

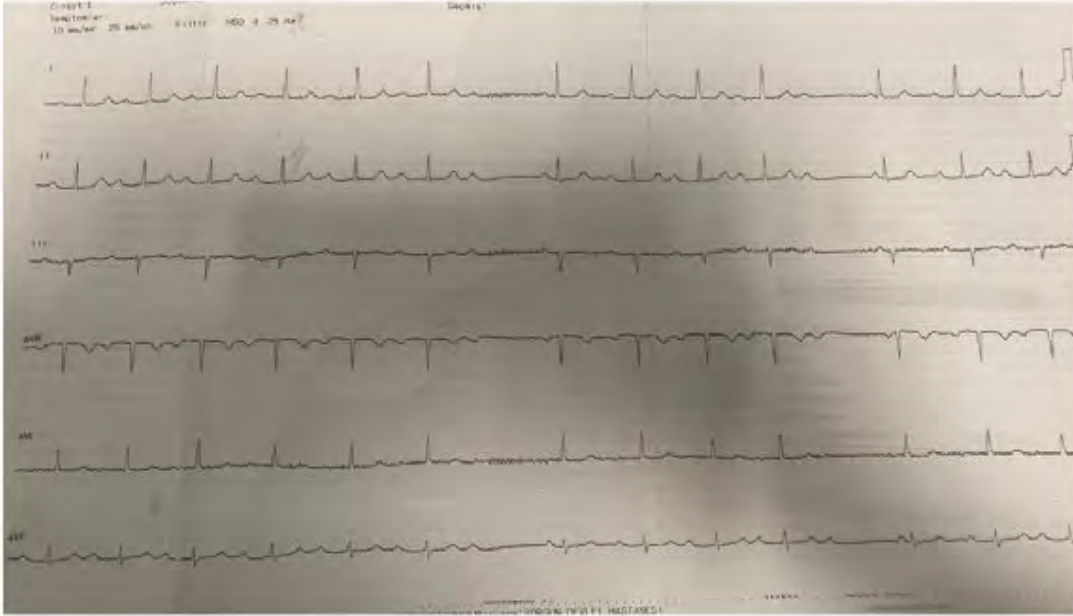


# KARDİYOVASKÜLER AKADEMİ KONGRESİ

## & INTERNATIONAL ACADEMY OF YOUNG CARDIOLOGISTS

Elexus Hotel Girne, K.K.T.C.  
18-22 Eylül 2024

Figure 1 First ECG shows Mobitz type I AV block (Wenckebach)



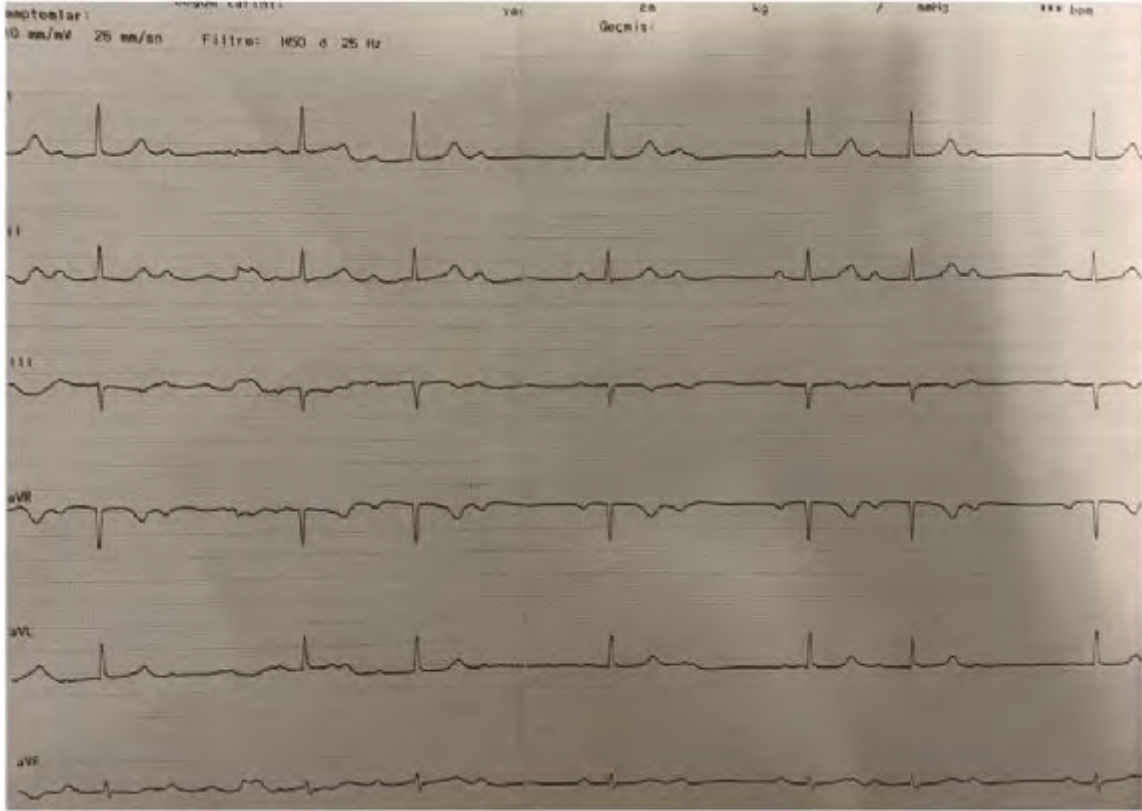


# KARDİYOVASKÜLER AKADEMİ KONGRESİ

## & INTERNATIONAL ACADEMY OF YOUNG CARDIOLOGISTS

Elexus Hotel Girne, K.K.T.C.  
18-22 Eylül 2024

Figure 2; 2:1 AV block is seen the follow up





# KARDİYOVASKÜLER AKADEMİ KONGRESİ

## & INTERNATIONAL ACADEMY OF YOUNG CARDIOLOGISTS

Elexus Hotel Girne. K.K.T.C.  
18-22 Eylül 2024

### [PP-03] Intracardiac cement embolism following vertebroplasty:A case report

Hacer Uysal<sup>1</sup>, Zeynep Kumral<sup>1</sup>, Ayşe Çolak<sup>1</sup>, Oğuzhan Ekrem Turan<sup>1</sup>, Mustafa Mahmut Barış<sup>2</sup>, Hüsna Tuğçe Şimşek<sup>1</sup>

<sup>1</sup>Dokuz Eylül Üniversitesi Tıp Fakültesi, Kardiyoloji Ana Bilim Dalı, İzmir

<sup>2</sup>Dokuz Eylül Üniversitesi Tıp Fakültesi, Radyoloji Ana Bilim Dalı, İzmir

**Background:** Percutaneous vertebroplasty (PVP) is a well-established procedure for the treatment of vertebral fractures. Complications such as migration of bone cement fragments through the paravertebral plexus and then the azygous venous system into the right-sided cardiac chambers are rare and detected in approximately 3.9% of the patients. Most of the cases were asymptomatic and only an incidentally detected finding, but symptomatic serious complications like valvular dysfunction, pulmonary artery obstruction, and life-threatening free wall cardiac rupture resulting in cardiac tamponade can occur in 0.3% of the patients. We present a case of intracardiac cement embolism after PVP and discuss the management of our patient.

**Case summary:** A 75-year-old male patient with a past medical history of heart failure with reduced ejection fraction (HFrEF), atrial fibrillation (AF) underwent fluoroscopy-guided L1 and L3 vertebroplasty. After 2 months after PVP patient applied to our hospital's arrhythmia clinic because of his bradycardia history, he had mild dyspnea as well. Transthoracic echocardiogram revealed oval, pouch-shaped structure with well-defined borders in the rvot (figure 1), cardiac CT scan was performed on the patient and compared with the previous CT scan, high density structure seen in the RVOT on cardiac CT angiogram was considered as inorganic material, and since it was not present on the preoperative CT (figure 2), it was thought to be cement. The patient was also evaluated in the council with heart team; since patient is hemodynamically stable, no pericardial effusion, no gross valvular dysfunction or obstruction, it is decided conservative approach. Patient was already receiving anticoagulant treatment for AF (Rivoroksaban), his treatment was continued and close follow-up planned.

**Conclusions:** Intracardiac cement embolism is important complication after PVP. The majority of cases remain asymptomatic but may show symptoms after years later of the procedure. Symptomatic intracardiac cement embolisms have a low incidence (8.3% of patients with ICE). And these symptoms are most likely dyspnea and chest pain. Although rare, serious complications such as valve dysfunction and life-threatening cardiac tamponade have also been reported. As clinicians, we must be careful to keep in mind that this complications after PVP may occur. Routine thoracic CT scanning after PVP is recommended to reduce mortality and morbidity rates in the long term. There is no definitive treatment approach due to the small number of identified cases and the long-term results are still not fully known, treatment decisions are made considering patient characteristics and symptoms. Current treatment options are: conservative treatment includes symptomatic treatment and oral anticoagulant therapy for 3 to 6 months until PMMA endothelializes, and surgical treatment includes percutaneous embolectomy (especially for right atrial emboli) and open cardiac embolectomy.

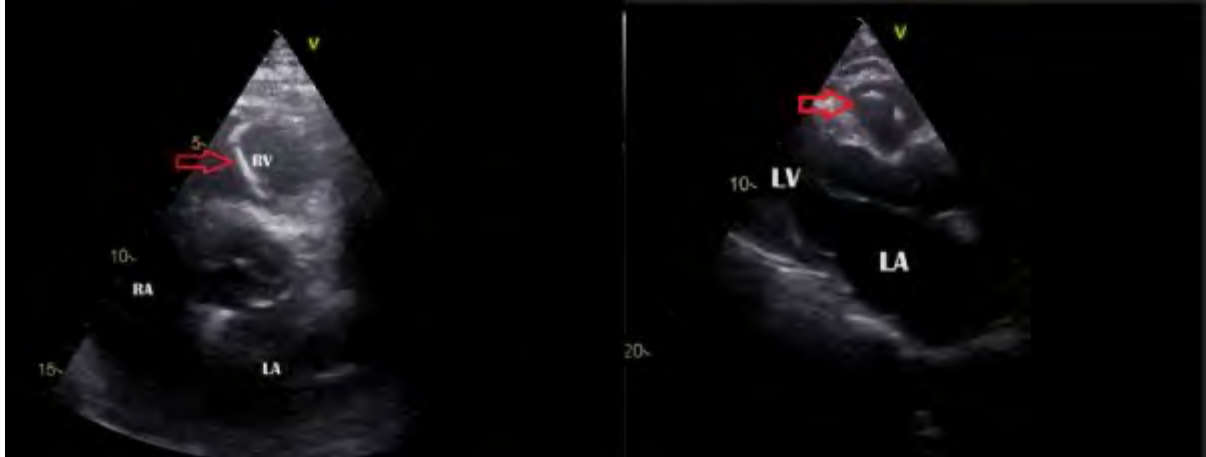
**Keywords:** cement, intracardiac, embolism, case report, vertebroplasty

# KARDİYOVASKÜLER AKADEMİ KONGRESİ

## & INTERNATIONAL ACADEMY OF YOUNG CARDIOLOGISTS

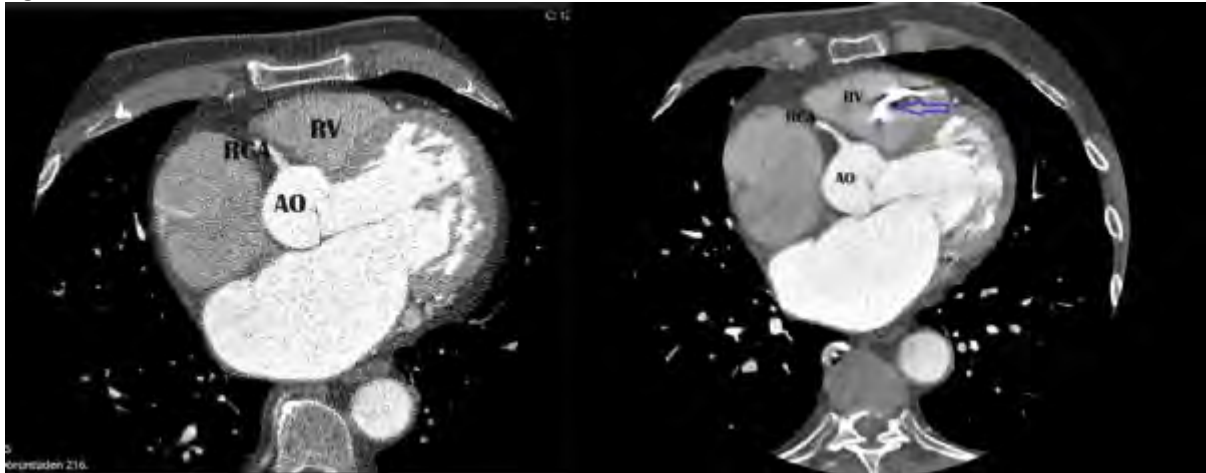
Elexus Hotel Girne, K.K.T.C.  
18-22 Eylül 2024

figure 1



*Transthoracic echocardiogram revealed floating oval foreign body in the right ventricle (red arrow)*

figure 2



*the picture on the left: There is no object in the right ventricle on the CT scan taken before PVP the picture on the right: Cardiac CT angiogram depicted a high density foreign body in the RVOT (blue arrow); RCA, right coronary artery; RV, right ventricle; AO: Aorta*





# KARDİYOVASKÜLER AKADEMİ KONGRESİ

## & INTERNATIONAL ACADEMY OF YOUNG CARDIOLOGISTS

Elexus Hotel Girne, K.K.T.C.  
18-22 Eylül 2024

### [PP-04] A Challenging Angiogram of an Achondroplasia Patient with Acute Coronary Syndrome

Feryat İğit<sup>1</sup>, Aylin Şafak Arslanhan<sup>1</sup>, Umut Baran Yılmaz<sup>1</sup>, Ertan Arter<sup>2</sup>, Ali Nazmi Çalık<sup>2</sup>

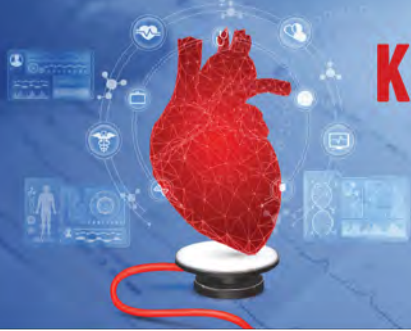<sup>1</sup>Umraniye Training And Research Hospital

<sup>2</sup>Dr Siyami Ersek Thoracic And Cardiovascular Surgery Training And Research Hospital

Dwarfism can arise from various locomotor system anomalies and endocrine disorders. The most common cause of dwarfism is achondroplasia, which is due to a mutation in the fibroblast growth factor receptor 3 (FGFR 3) gene. Given a relatively similar life expectancy to the general population and a propensity for early cardiovascular disease, it is not uncommon for these patients to develop long-term health problems and require cardiac intervention. However, there are relatively few studies in the literature examining coronary imaging and interventions in these patients. In this case report, we present a 62-year-old male, patient with achondroplasia who presented to the emergency department due to progressively worsening exertional dyspnea over the past month. He has a medical history of diabetes mellitus and smoking. Pulmonary auscultation revealed crepitant rales in both lung bases. Additionally, an S3 gallop was detected upon cardiac auscultation. Pretibial edema was detected in both lower extremities. ECG showed sinus tachycardia (121 bpm) and loss of R-wave progression in the anterior derivations. The echocardiogram revealed global systolic dysfunction of the left ventricle, with an ejection fraction of 35%. Apart from mild mitral valve insufficiency, no major pathology was detected. In the blood tests, Pro-BNP was 4507 pg/ml, hs-Troponin T was 108 ng/L, serum creatinine was 0.92 mg/dl, and hemogram was normal. No electrolyte imbalance was observed. The patient was admitted to the intensive care unit due to newly diagnosed congestive heart failure and acute pulmonary edema. Coronary angiography was planned after peripheral and pulmonary decongestion treatment. The patient was transferred to the catheter laboratory. Extremity pulses were detected weak. Attempt to access the femoral and radial arteries were unsuccessful. Coronary and peripheral computed tomographic angiography was planned after failed procedure. Moderate to severe stenosis compatible with Leriche syndrome was observed in the abdominal aorta and bilateral iliac arteries. Coronary CT angiography revealed normal left main coronary artery, 70% stenosis in the proximal and mid region of the left anterior descending artery, occluded circumflex artery and right coronary artery. Since CT angiography was compatible with severe coronary artery disease, conventional angiography was planned. The right upper extremity brachial-axillary artery was determined as the most appropriate arterial access site under the guidance of CT images. Puncture was performed between the axillary and brachial artery at the point where arterial pulsation was best palpated. 6F radial sheath was placed. Angiographic imaging was performed with Judkins right and left 3.5 diagnostic catheters. LMCA distal 80%; LAD proximal 70%, mid 80%, pre-mustache 90%; CX mid 80% and RCA occluded from the ostium. CABG was considered for the patient with a SYNTAX score of 41. The patient was transferred to a centre where open heart surgery is performed.

**Keywords:** Achondroplasia, Coronary Intervention, Coronary Computed Tomography Angiography, Leriche Syndrome



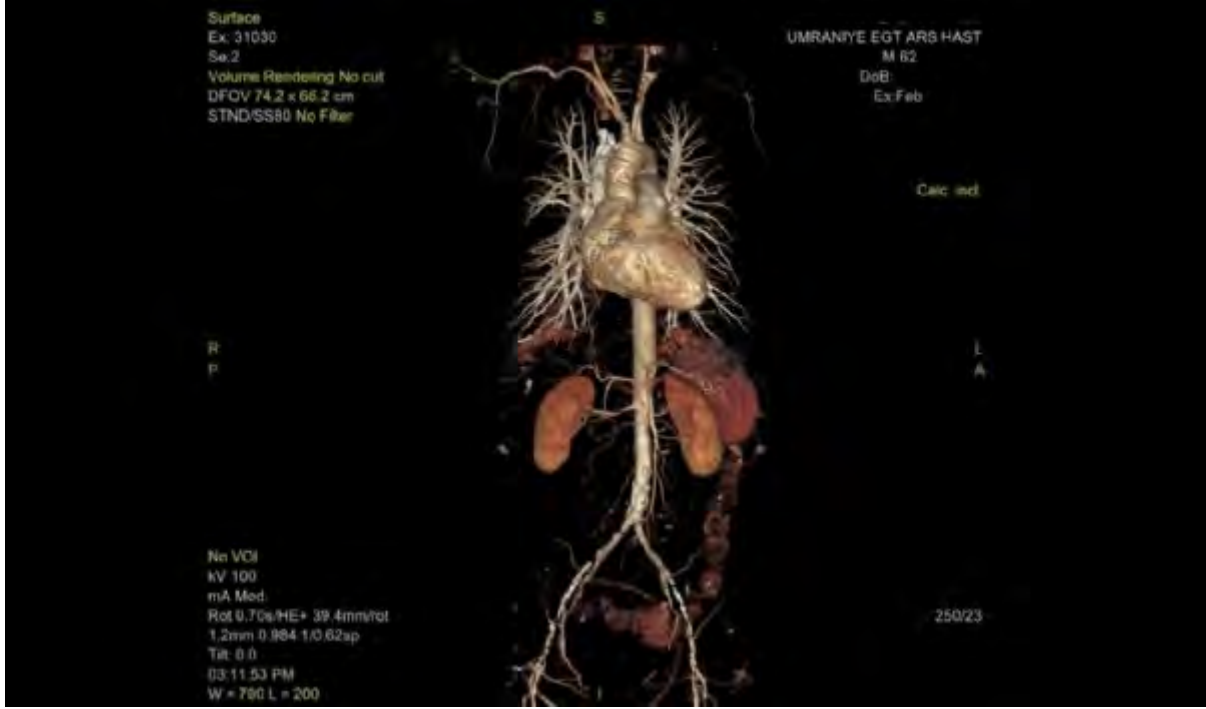

# KARDİYOASKÜLER AKADEMİ KONGRESİ

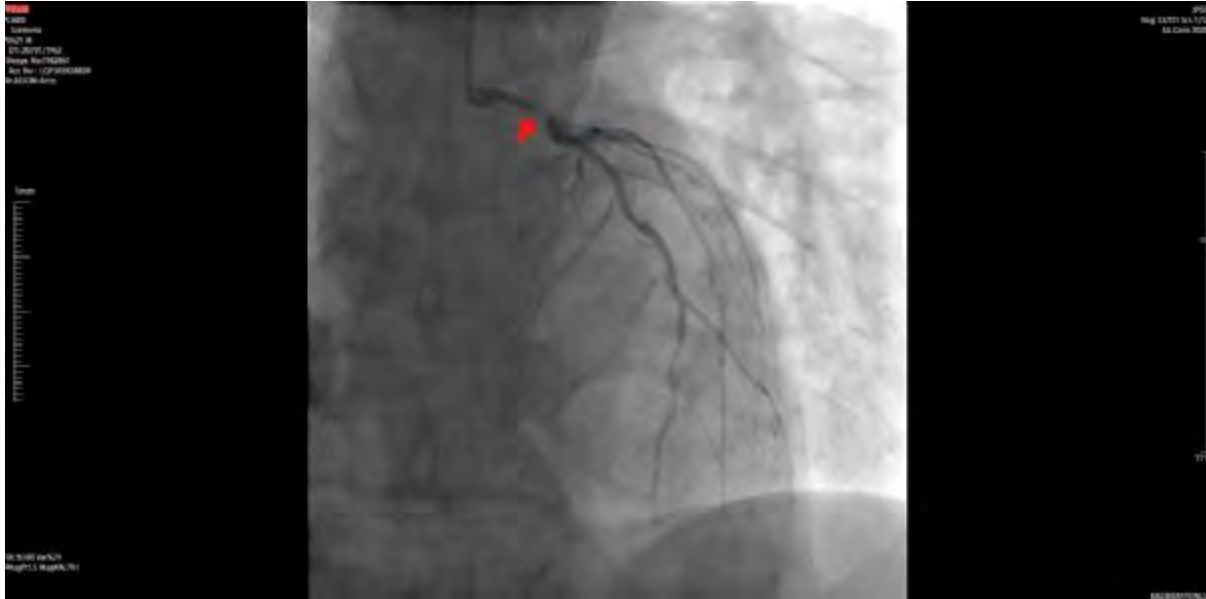## & INTERNATIONAL ACADEMY OF YOUNG CARDIOLOGISTS

Elexus Hotel Girne, K.K.T.C.  
18-22 Eylül 2024

### Computed Tomography Angiography



### Coronary Angiography



*distal LMCA %80 stenosis*



# KARDİYOVASKÜLER AKADEMİ KONGRESİ

## & INTERNATIONAL ACADEMY OF YOUNG CARDIOLOGISTS

Elexus Hotel Girne, K.K.T.C.  
18-22 Eylül 2024

### [PP-05] The rarest complication and the early diagnosis

Utku Zeybey, Selen Yurdakul, Fatih Mehmet Ucar

*Department of Cardiology, Florence Nightingale Hospital, Istanbul*

**Introduction:** Iatrogenic vascular injuries, due to the particular nature of such pathology, are associated with high morbidity and mortality in the postoperative period. This dangerous and sometimes life-threatening complication is being increasingly reported in the literature. Early identification of the fistula and its successful treatment would allow us to avoid significant consequences for the patient's health. The early diagnosis and correct therapy, increases the patient's chances of avoiding complications. In this report, we discuss our experience of iatrogenic iliac arteriovenous fistula after disc surgery in a man diagnosed palpitation.

**Case:** 69 years old man presented to cardiology department with complaint of palpitation. His only medical history was lumbar discectomy performed ten years previously. On presentation, the patient's vital signs were normal. Cardiac examination revealed abdominal murmur. Electrocardiogram and transthoracic echocardiography were normal. Computed tomography angiography revealed an arteriovenous fistula connecting the right common iliac artery and vein (Figure 1). Iliac vessel angiography planned for the patient and confirmed the iliac arteriovenous fistula between right common iliac artery and vein. The decision was made to treat the patient using endovascular method. The right femoral artery was punctured and 25x13x145 mm stent was implanted. A good flow through the right common, internal and external iliac arteries were observed (Figure 2). **Discussion:** Iatrogenic injury of vessel is one of the complications of neurosurgical and orthopedic surgeries. The associated morbidity and mortality results from large vessels hemorrhage leading to hypovolemic shock. If undetected in the course of the primary operation, this may lead to the patient's death during or after the surgery. It is not uncommon that they become detected incidentally, many years after the injury. Due to the associated early and late complications, each such complication requires urgent diagnostic and adequate, specialist treatment. As immediate surgical treatment due to life-threatening condition, is a 1st line treatment, the benefits of minimal invasive approach in the form of endovascular procedure may result in lower morbidity and mortality. In this case, we detected an iliac arteriovenous fistula ten years after the first lumbar disc surgery as a complication. This complication may occur after many years. Physical examination and imaging methods play a major role in diagnosis.

**Keywords:** arteriovenous fistula, murmur, palpitation

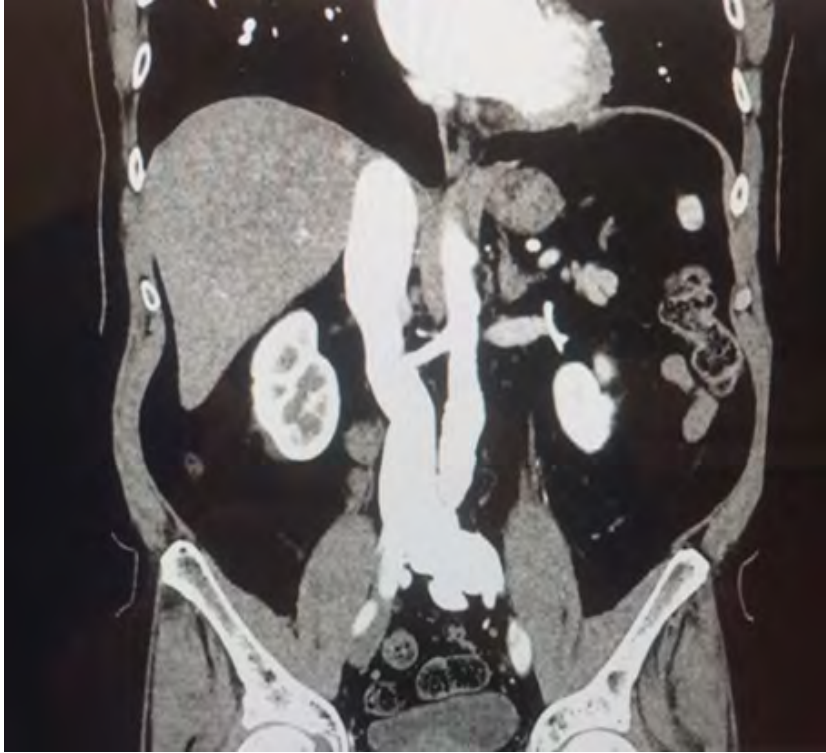


# KARDİYOVASKÜLER AKADEMİ KONGRESİ

## & INTERNATIONAL ACADEMY OF YOUNG CARDIOLOGISTS

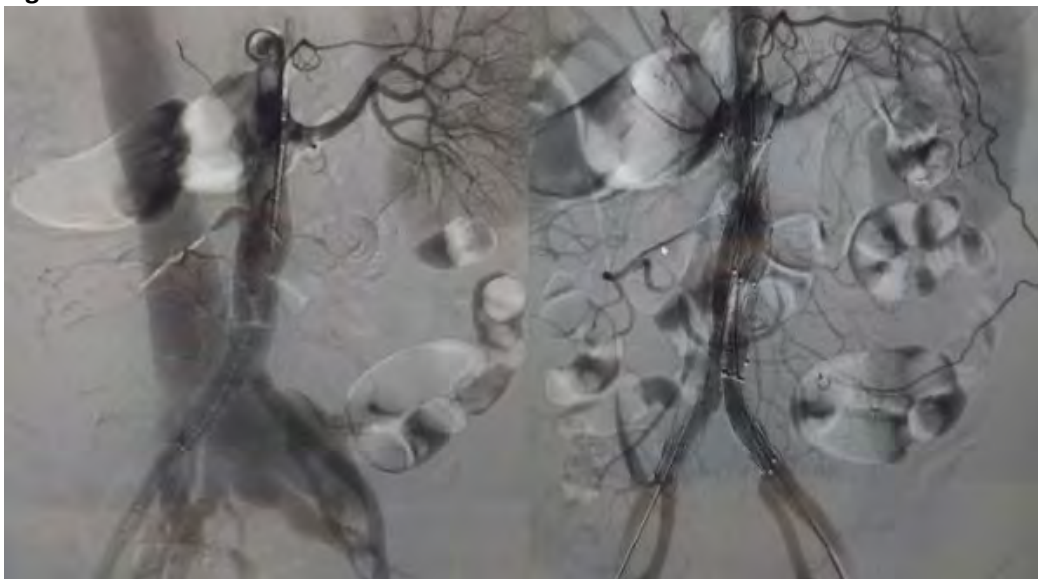
Elexus Hotel Girne, K.K.T.C.  
18-22 Eylül 2024

**Figure 1**



*Arteriovenous fistula connecting the right common iliac artery and vein. Contrast enhancement in bilateral common iliac vein and vena cava in arterial phase.*

**Figure 2**



*Angiography of iliac vessels. The iliac arteriovenous fistula between common iliac artery and vein and arterial flow after stent implantation.*





# KARDİYOVASKÜLER AKADEMİ KONGRESİ

## & INTERNATIONAL ACADEMY OF YOUNG CARDIOLOGISTS

Elexus Hotel Girne, K.K.T.C.  
18-22 Eylül 2024

### [PP-06] Exploring the experiences of Atrial Fibrillation patients, a digital ethnography research report

Şakir Boyraz, Emine Dundar Ahi, Tugay Önal, Ayşe Ölmez  
Pfizer, İstanbul/Turkey

**Objectives:** The objective of this qualitative study is to gain a deeper understanding of the perceptions and perspectives of Atrial Fibrillation (AF) patients, as well as their unmet needs and pain points throughout their journey with the condition. **Methods:** This is a Qualitative, ethnographic study with one-to-one online interviews. The patients met online with the moderator individually to talk about their lives and AF journey in detail. The first interviews took about 75 minutes each. After the first interviews, expert qualitative interviewer requested the patients to gather instances from their daily lives (e.g. living environments, nutritional, and physical experiences) in the format of photos and videos for further exploration. After the patients had gathered the multimedia that they were asked to, the interviewer had another round of interviews with them. Each patient had a 30-45 minute session, where the moderator discussed the media they submitted, explored important aspects that required more clarification. The interviews were held between September-October 2023. **Results:** For AF patients, maintaining their responsibilities as they did before the illness and leading a normal life serve as a fundamental source of motivation. **Nutrition:** AF patients try to eat light and frequently. They complain that they cannot receive direct guidance regarding diet from their doctors, and they think that it would be appropriate to recommend a dietitian program. **Exercise:** While AF patients incorporate physical activity into their lives, they maintain moderation during exercise. They avoid excessive sweating and getting too breathless, preferring to move at a moderate pace. Some patients stated that they were only advised to walk, but they did not know how many days-hours in a week this should be done, and that there was a lot of confusion on the internet about this subject. **Sleep:** AF patients recognize the potential negative impact of sleep deprivation on rhythm disorders. Patients complain of waking up tired. The awareness of the necessity to take medication at a specific time every day is quite high among AF patients. While Group 1 patients are still in the process of developing this awareness, Group 2 and Group 3 patients avoid irregular medication intake due to the negative effects they experience. **Conclusions:** In essence, AF patients have expectations of establishing a more intimate and meaningful dialogue with healthcare professionals regarding AF. They think that cardiologists referring AF patients to Nutrition Specialists (for weight control and appropriate diet recommendations), Physical Medicine & Rehabilitation Specialists (personal exercise program that they can do safely) and Pulmonology Specialist (to be evaluated in terms of sleep hygiene and sleep apnea) would also be beneficial. **Disclosure:** This research was sponsored by Pfizer. Patient recruitment and editorial support were provided by Ipsos Healthcare and were funded by Pfizer.

**Keywords:** atrial fibrillation, nutrition, exercise, sleep apnea



# KARDİYOVASKÜLER AKADEMİ KONGRESİ & INTERNATIONAL ACADEMY OF YOUNG CARDIOLOGISTS

Elexus Hotel Girne, K.K.T.C.  
18-22 Eylül 2024

## STEPS OF PATIENT JOURNEY



The subgroups of the patients and number of interviews

Subgroups	The patient's condition	Ethnos
Group 1	Patients living with AF for less than five years	4
Group 2	Patients living with AF for more than five years without experiencing stroke/transient ischemic attack/systemic emboli	4
Group 3	Patients living with AF for more than five years with experiencing stroke/transient ischemic attack/systemic emboli	4
	TOTAL	12
	TOTAL WITH FOLLOW UP INTERVIEWS	24



# KARDİYOVASKÜLER AKADEMİ KONGRESİ

## & INTERNATIONAL ACADEMY OF YOUNG CARDIOLOGISTS

Elexus Hotel Girne. K.K.T.C.  
18-22 Eylül 2024

### [PP-07] Conservative Treatment of Pellet in the Heart

Cem Korucu<sup>1</sup>, Serkan Güme<sup>2</sup>, Vesile Buse Yolcu<sup>3</sup>

<sup>1</sup>Afyonkarahisar Health Science University, Faculty of Medicine, Department of Cardiology

<sup>2</sup>Afyonkarahisar Health Science University, Faculty of Medicine, Department of Cardiovascular Surgery

<sup>3</sup>Necmettin Erbakan University, Faculty of Medicine, Department of Cardiocascular Surgery

Nowadays, gunshot wounds are among the most common and potentially life-threatening conditions in emergency departments.

In this case, we wanted to present a 28-year-old male patient without any disease, who was admitted to the emergency department with a gunshot wound, was clinically stable, and was followed up with conservative treatment.

During the examination of the patient upon arrival at the emergency department, his vital signs were stable. The patient had no complaints other than pain. A wound with an entrance hole of approximately 0.5\*0.5 cm but no exit hole was observed on the left edge of the sternum. Chest computed tomography revealed many pellets on the anterior chest wall, a few in the lung tissue, two in the pericardial sac and one in the myocardium of the ventricular septum. Transthoracic echocardiography revealed a pellet appearing as acoustic shadowing within the ventricular septal myocardium. Thickening of the adjacent pericardium adjacent to the pellets in the pericardial sac was also noted. There was no evidence of constrictive pericarditis or regional wall motion abnormality. The patient was admitted to the cardiovascular surgery intensive care unit for observation because his vital stability and imaging did not require urgent surgery.

During the 5-day follow-up of the patient, there was no decrease in hemogram, no bleeding, and no symptoms. The patient was followed up stably and no abnormal findings were found in the Holter monitoring and treadmill exercise test at discharge. The patient was included in a periodic follow-up program and discharged.

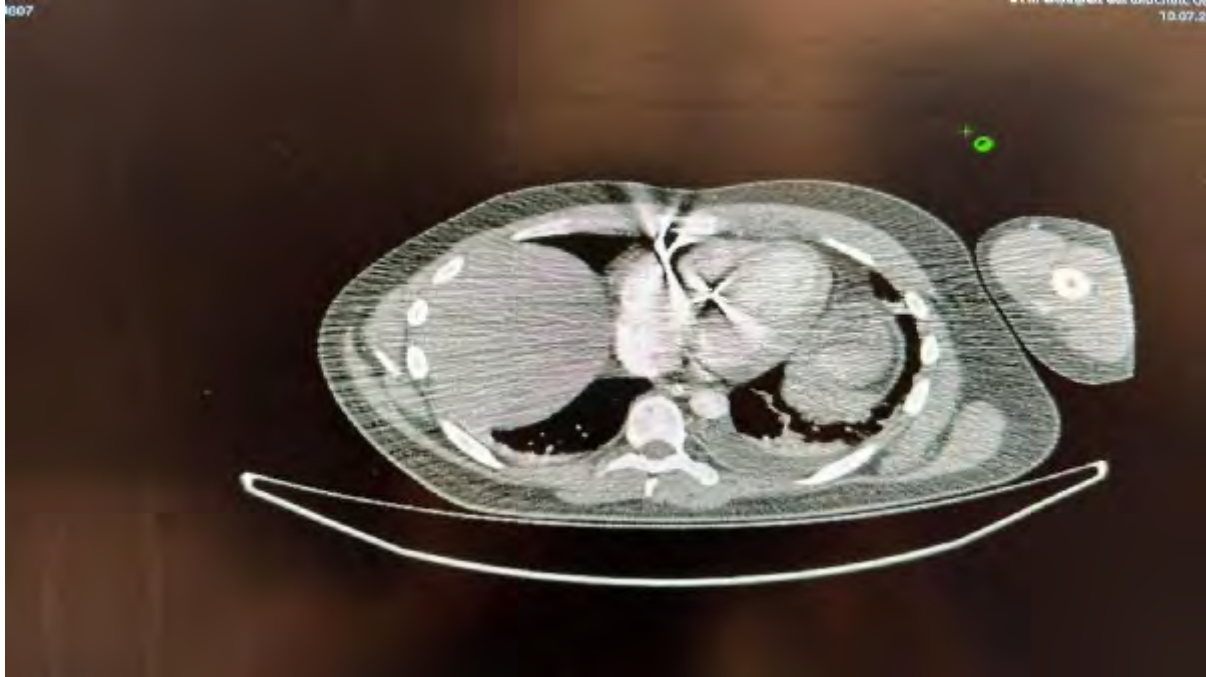
**Keywords:** Conservative treatment, Foreign bodies, Heart injuries

# KARDİYOVASKÜLER AKADEMİ KONGRESİ

## & INTERNATIONAL ACADEMY OF YOUNG CARDIOLOGISTS

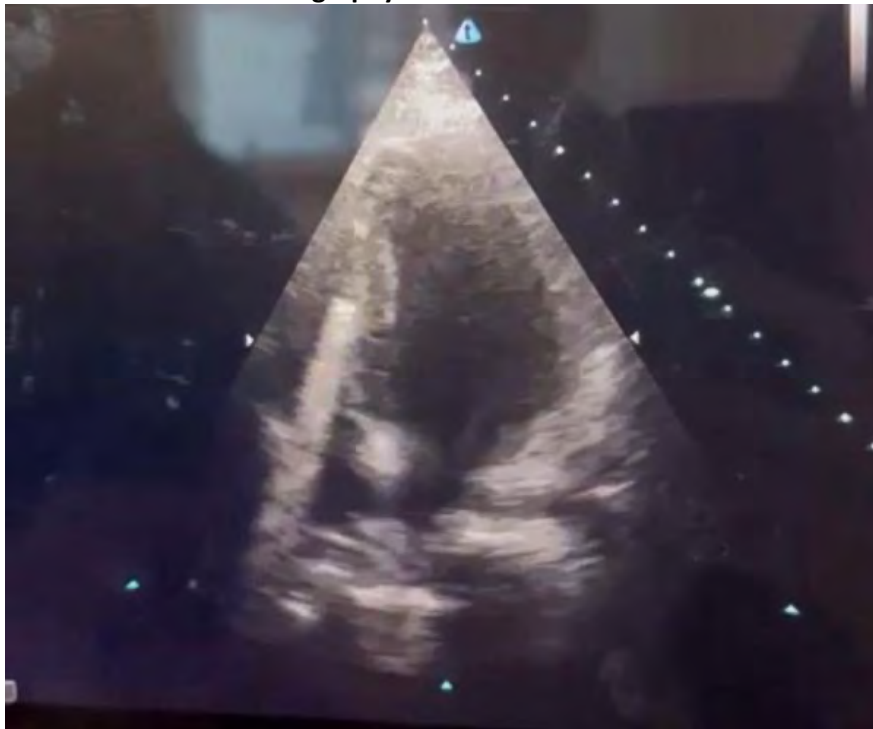Elexus Hotel Girne, K.K.T.C.  
18-22 Eylül 2024

### Computed tomography



*Computed tomography shows pellets in the pericardial area and interventricular septum.*

### Transthoracic echocardiography



*Transthoracic echocardiography shows a pellet in the interventricular septum.*





# KARDİYOVASKÜLER AKADEMİ KONGRESİ

## & INTERNATIONAL ACADEMY OF YOUNG CARDIOLOGISTS

Elexus Hotel Girne, K.K.T.C.  
18-22 Eylül 2024

### [PP-08] Coexistence of multiple coronary artery aneurysms and abdominal aortic aneurysm

Ömer Tepe<sup>1</sup>, Anıl Akray<sup>2</sup>, Haydar Ali Candan<sup>3</sup>, Çağlar Emre Çağlıyan<sup>3</sup>

<sup>1</sup>Osmaniye State Hospital, Cardiology Clinic, Osmaniye, Turkey

<sup>2</sup>Iskenderun State Hospital, Cardiology Clinic, Iskenderun, Turkey

<sup>3</sup>Çukurova University Faculty of Medicine, Department of Cardiology, Adana, Turkey

**Introduction:** An abdominal aortic aneurysm is a local pathological enlargement of the abdominal aorta to a size greater than 30 mm. A coronary artery aneurysm is defined as an enlargement exceeding 1.5 times the diameter of the normal adjacent coronary artery. Aneurysms involving the left main coronary artery are extremely rare. The present article aims to present the intervention performed on the abdominal aneurysm of our patient with multiple coronary aneurysms.

**Case:** A 69-year-old male patient presented with abdominal pain and fatigue. His ECG was in sinus rhythm. Transthoracic echocardiography showed an ejection fraction of 65% with no additional findings. Abdominal ultrasonography revealed an abdominal aortic aneurysm of uncertain size. Coronary angiography and aortography were scheduled. Angiography showed aneurysmatic dilatations in all coronary vessels including the left main coronary artery. A giant aneurysm involving the LMCA, LAD ostial, and CX ostial was observed, and a fusiform aneurysmal dilatation was noted in the RCA. Slow flow was predominant in all coronary vessels. Medical treatment was considered for the coronary vessels, and aortography showed a right-angled saccular aneurysm at the infrarenal level. Endovascular aneurysm repair (EVAR) procedure was planned for our patient. The abdominal aortic aneurysm was intervened with a stent-graft system. Aortography confirmed the patency of the bilateral renal and iliac arteries and the complete closure of the aneurysm. The patient was discharged in an uneventful stable condition. A follow-up computed tomography angiography at 1 year showed favorable stent-graft positions without endoleak or migration.

**Discussion:** Abdominal aortic aneurysms may accompany coronary artery aneurysms. Coronary artery aneurysms and abdominal aortic aneurysms have common risk factors. Atherosclerosis is the most common cause of the two diseases. In addition, inherited connective tissue disorders and mutations in matrix metalloproteinase genes can cause both aortic and coronary aneurysms.

In patients with abdominal aortic aneurysms, coronary artery disease and coronary aneurysms are significantly more common when compared to the general population. Our patient with abdominal aortic aneurysm was diagnosed with asymptomatic non-obstructive coronary artery disease and aneurysm. Concomitant significant critical lesions and aneurysmatic dilatations are not uncommon and cause significant mortality and morbidity in these cases. Screening for abdominal aortic aneurysm in individuals over 65 years old and screening other vascular systems in cases of aneurysm may provide additional benefits.

**Keywords:** abdominal aortic aneurysm, coronary aneurysm, multiple aneurysms



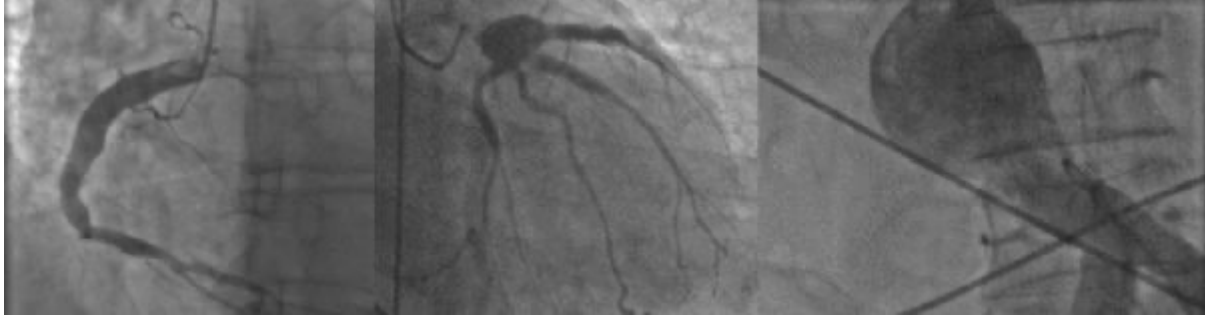

# KARDİYOVASKÜLER AKADEMİ KONGRESİ

## & INTERNATIONAL ACADEMY OF YOUNG CARDIOLOGISTS

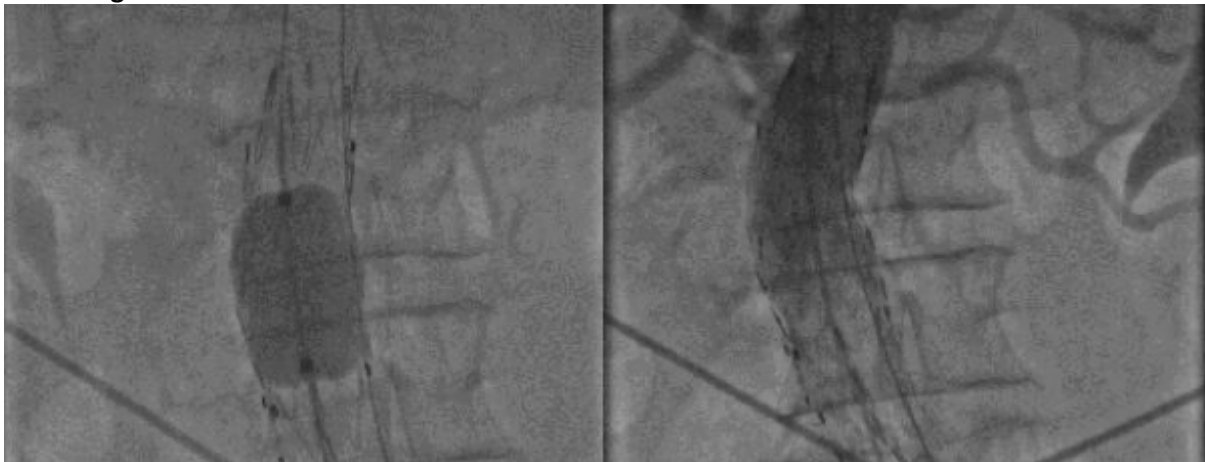
Elexus Hotel Girne, K.K.T.C.  
18-22 Eylül 2024

### Coronary angiography and aortography images



from left to right respectively; Figure 1: Aneurysmal dilatation extending from ostial to mid region in RCA. Figure 2: Giant aneurysm of left main coronary artery. Figure 3: Abdominal aortic aneurysm at infrarenal level

### final images



Aortography showing no blood flow in the aneurysm, no endoleak, appropriate stent-graft positions



# KARDİYOVASKÜLER AKADEMİ KONGRESİ

## & INTERNATIONAL ACADEMY OF YOUNG CARDIOLOGISTS

Elexus Hotel Girne, K.K.T.C.  
18-22 Eylül 2024

### [PP-09] Association of pre-infarction angina with mortality despite infarction-related artery patency in patients with acute myocardial infarction

Özgür Can Usta, Ahmet Göktuğ Çolakoğlu, Onurcan Türk, Şeyma Uyanık, Mustafa Kamil Yemiş, Şölen Taşlıçukur, Ahmet Öz, Turgut Karabağ  
Saglik Bilimleri University, Istanbul Education and Research Hospital, Istanbul-Turkey

**BACKGROUND AND Aim:** Pre-infarction angina (PA) defined as any episode of chest pain within 4 weeks of infarction and defined as presence of ischemic preconditioning. It is accepted that pre-infarction angina is a condition that results in a positive response for patients. In this study, the relationship between the presence of preinfarction and mortality was investigated in patients who presented with acute coronary syndrome and underwent primary percutaneous intervention.

**Methods:** Our study included 209 patients (153 males, 56 females, mean age:  $57.3 \pm 12.6$  years) who presented to the emergency department of our hospital with acute coronary syndrome and presented with ST elevation myocardial infarction (MI), non-ST acute MI, or unstable angina pectoris. All patients underwent electrocardiogram as well as other laboratory tests. All patients underwent primary percutaneous intervention, and before that, ticagrelor 90 mg or clopidogrel 600 mg was given in addition to 300 mg acetylsalicylic acid was loaded. The presence of PA was accepted in patients who described any angina or angina equivalent within 4 weeks before the infarction. In cases of hemodynamic compensation and ongoing angina, if there was another critical coronary stenosis, intervention was also performed. Groups with PA before myocardial infarction group 1; (88 patients 57 men, 31 women, mean age= $58.8 \pm 11.6$  years) and those without PA before myocardial infarction group 2; (121 patients, 96 men, 25 women, mean age= $56.2 \pm 13.3$  years). Exitus within 1 month from the procedure date was considered as the negative endpoint. It was confirmed from the death registration system whether the patients were dead or not within 1 month.

**Results:** Patency of infarct related artery could not be achieved only 4 patients (2 in group 1 and 2 in group). There were 3 deaths in the group 1 (%3.3), while 16 deaths were observed in the group 2 (%13.2) ( $p=0.008$ ). While there was no difference between the groups in terms of age, the proportion of gender in group 2 were significantly higher than in group 1 (Table 1). Systolic and diastolic blood pressures, kidney functions, and cholesterol panels were similar. Glucose levels and hypertension rate were significantly higher in group 1 compared to group 2, while hemoglobin levels were significantly lower in group 1 compared to group 2 (Table 1). Exitus rate was significantly lower in group 1 compared to group 2.

**Conclusions:** Patients with pre-infarction angina, which is one of the indicators of ischemic preconditioning, resulted with positive outcomes than individuals without.

**Keywords:** Acute myocardial infarction, preinfarctus angina, infarct related artery, mortality



# KARDİYOVASKÜLER AKADEMİ KONGRESİ

## & INTERNATIONAL ACADEMY OF YOUNG CARDIOLOGISTS

Elexus Hotel Girne, K.K.T.C.  
18-22 Eylül 2024

Comparison of demographic and laboratory features of the groups

	Group 1 (n=88)	Group 2 (n=121)	p
Age (years)	58.8±11.6	56.2±13.3	0.132
Gender (F,n)	31	25	0.019
Hypertension (n)	48	29	0.042
Diabetes mellitus (n)	28	37	0.837
Smoking (n)	51	78	0.393
Hyperlipidemia (n)	32	38	0.444
Family history (n)	37	38	0.109
CKD (n)	12	13	0.529
Systolic BP	144.8 ± 36.4	138.2 ± 36.2	0.212
Diastolic BP	86.6 ± 20.0	82.0 ± 17.9	0.097
STMI (n/%)	67	99	0.318
Troponin T (ng/L)	356.5 ± 846.9	416.7 ± 1076.3	0.664
Glucose (mg/dL)	58.5 ± 88.3	185.3 ± 85.4	0.030
Urea (mg/dL)	39.0 ± 23.6	34.7 ± 14.2	0.104
Creatinine (mg/dL)	1.04 ± 0.76	0.95 ± 0.28	0.218
Total cholesterol (mg/dL)	188.8 ± 39.0	184.8 ± 47.8	0.598
Triglyceride (mg/dL)	183.1 ± 127.7	162.2 ± 91.2	0.282
LDL cholesterol (mg/dL)	119.7 ± 42.0	119.6 ± 46.8	0.983
HDL cholesterol (mg/dL)	42.1 ± 16.3	37.9 ± 8.2	0.068
WBC (10 <sup>9</sup> /L)	11.16 ± 3.46	11.82 ± 3.70	0.192
Haemoglobin (g/dL)	13.7 ± 2.2	14.3 ± 1.7	0.016
Platelet (10 <sup>9</sup> /L)	258.7 ± 85.9	260.5 ± 81.7	0.878
Platecrit (%)	0.264 ± 0.074	0.282 ± 0.078	0.104

(Abbreviations; CDK; Chronic kidney disease, BP; blood pressure, STMI; ST segment elevation myocardial infarction, LDL; Low density lipoprotein, HDL; density lipoprotein, WBC; White blood cell)

### [PP-10] A Rare Of Tricuspid Valve Endocarditis And Surgical Treatment

Taha Gürbüzer, Ugur Ozpinar

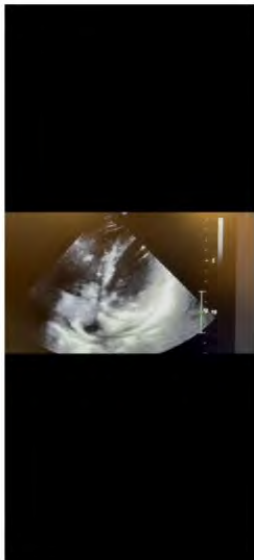Canakkale Mehmet Akif Ersoy Government Hospital Canakkale

Endocarditis of tricuspid valve is very rare. Right-sided infective endocarditis is less common than left-sided infective endocarditis, encompassing only 5–10% of cases of infective endocarditis. Ninety percent of right-sided infective endocarditis involves the tricuspid valve. Right-sided infective endocarditis and tricuspid valve infective endocarditis are strongly associated with intravenous drug use, although pacemaker leads, defibrillator leads and vascular access for dialysis are also major risk factors. Staphylococcus aureus is the predominant causative organism in tricuspid valve infective endocarditis. Most patients with tricuspid valve infective endocarditis are successfully treated with antibiotics, however, 5–16% of right-sided infective endocarditis cases eventually require surgical intervention. A 36-year old male patient was admitted to our hospital with complaint of high fever, fatigue and joint pain. Staphylococcus Aureus (Methicilline susceptible) was isolated from blood and bone marrow specimens. Echocardiography revealed a vegetation, dimension of 14x13 mm on the anterior leaflet of the tricuspid valve. reasonable antibiotherapy for 2 weeks have given, but sepsis and recurrent pulmonary embolics appeared. The vegetation was excised during open heart surgery. Remaining part of the anterior leaflet was corrected to function normally. Postoperatively, it was shown that there was a minimal tricuspid insufficiency by echocardiography.

**Keywords:** Tricuspid valve, Endocarditis, Valvuloplasty, Echocardiography

---

triküspit vejetasyonu







# KARDİYOVASKÜLER AKADEMİ KONGRESİ

## & INTERNATIONAL ACADEMY OF YOUNG CARDIOLOGISTS

Elexus Hotel Girne, K.K.T.C.  
18-22 Eylül 2024

### [PP-11] Removal Of Coil Material Embolized To The Right Atrium

Günseli Miray Özdemir, Melih Öz, Ali Nazmi Çalık

*Department of Cardiology, University of Health Sciences, Dr. Siyami Ersek Thoracic and Cardiovascular Surgery Training and Research Hospital, İstanbul*

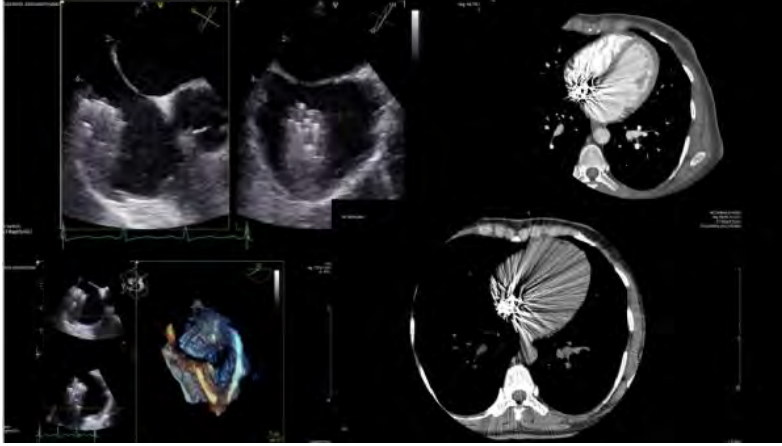Recent advancements have significantly enhanced the diagnosis and treatment of pelvic congestion syndrome, associated with chronic pelvic pain and ovarian and uterine varices. Presently, the surgical treatment involves ligating incompetent veins through open or laparoscopic surgery. However, these procedures are more invasive than endovascular embolization, necessitate general anesthesia, and are seldom performed. Transcatheter embolization therapy is the preferred approach for treating pelvic congestion syndrome.

Herein, we describe a patient treated for pelvic pain stemming from pelvic varices with coil embolization of the left and right ovarian veins, resulting in coil migration to the right atrium. Following an unsuccessful percutaneous removal attempt, the coils were effectively extracted through right atriotomy.

A 40-year-old female patient presented to the clinic with a complaint of progressive shortness of breath. Physical examination revealed a blood pressure of 110/80 mmHg and a heart rate of 70 beats per minute, with no pathological sounds or murmurs detected during cardiac auscultation. The patient's electrocardiogram indicated a sinus rhythm. It was discovered that the patient had undergone coil embolization of the left and right ovarian veins for pelvic pain caused by pelvic varices at an external center six months ago. A transthoracic echocardiography (TTE) was scheduled to investigate the cause of dyspnea. The TTE revealed a hyperechoic mass image causing acoustic shadowing, measuring 23\*27mm with irregular borders, located at the base of the right atrium, along with moderate mitral and tricuspid regurgitation in addition to rheumatic valves. A Transesophageal Echo (TEE) and Cardiac CT were planned for further evaluation. The TEE examination identified a hyperechoic mass image (likely metallic), causing acoustic shadowing, measuring 30\*25 mm near the inferior vena cava within the right atrium. During the cardiac CT examination, a metallic structure measuring approximately 26x25mm was identified within the right atrium, leading to extensive artifact. Subsequent to the cardiac CT, fluoroscopy of the patient revealed coils within the left ovarian veins, whereas coils from the right ovarian vein were observed to have embolized into the right atrium. The original intention was to percutaneously extract the embolized coils from the right atrium using peripheral clamps (snare). However, it was observed that the coil material had adhered to the right atrium, posing a potential risk of damaging the atrial wall significantly during the procedure. A Cardiovascular Surgery consultation was sought for the patient, and surgery was scheduled. Following standard aortic and bicaval cannulation and initiation of total cardiopulmonary bypass, a right atriotomy was performed on the beating heart to extract the foreign body from the right atrium. The patient had an uneventful postoperative course and was discharged on the fifth day after the surgery.

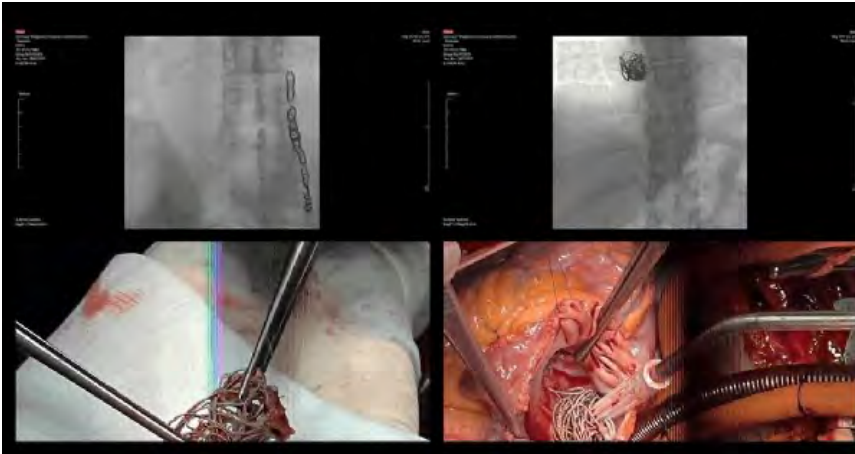
**Keywords:** Pelvic venous congestion syndrome, Embolization, Coil, Snare

### Non-invasive Imaging Methods



The TTE revealed a hyperechoic mass image causing acoustic shadowing, measuring 23\*27mm with irregular borders, located at the base of the right atrium, along with moderate mitral and tricuspid regurgitation in addition to rheumatic valves. A Transesophageal Echo (TEE) and Cardiac CT were planned for further evaluation. The TEE examination identified a hyperechoic mass image (likely metallic), causing acoustic shadowing, measuring 30\*25 mm near the inferior vena cava within the right atrium. During the cardiac CT examination, a metallic structure measuring approximately 26x25mm was identified within the right atrium, leading to extensive artifact.

### Treatment



Subsequent to the cardiac CT, fluoroscopy of the patient revealed coils within the left ovarian veins, whereas coils from the right ovarian vein were observed to have embolized into the right atrium. The original intention was to percutaneously extract the embolized coils from the right atrium using peripheral clamps (snare). However, it was observed that the coil material had adhered to the right atrium, posing a potential risk of damaging the atrial wall significantly during the procedure. A Cardiovascular Surgery consultation was sought for the patient, and surgery was scheduled. Following standard aortic and bicaval cannulation and initiation of total cardiopulmonary bypass, a right atriotomy was performed on the beating heart to extract the foreign body from the right atrium. The patient had an uneventful postoperative course and was discharged on the fifth day after the surgery.



# KARDİYOVASKÜLER AKADEMİ KONGRESİ

## & INTERNATIONAL ACADEMY OF YOUNG CARDIOLOGISTS

Elexus Hotel Girne. K.K.T.C.  
18-22 Eylül 2024

### [PP-12] Unexpanded coronary stent due to rupture of stent balloon

Adam Uf Turk, Ayşe Çolak, Hacer Uysal, Sercan Karaoğlan

*DOKUZ EYLÜL ÜNİVERSİTESİ HASTANESİ - KARDİYOLOJİ ANABİLİMDALI -İZMİR*

Rupture of coronary stent balloon is a rare complication of coronary interventions, it can lead to stent dislodgement, stent loss and can lead to serious events including cerebrovascular embolism, myocardial infarction or even death.

In this case report we present a semi-expanded stent due to rupture of the stent balloon.

A 73-year-old male patient presented to the emergency department with chest pain was diagnosed with NSTEMI, he has a history of coronary PCI performed 4 years ago.

on the angiogram there was no significant lesion in the CX and RCA and there was an in-stent %80 lesion in the distal LAD stent that was implanted before, there was a %70 lesion in the proximal portion of the stent, a % 80 lesion was observed in the first Diagonal branch.

we started the procedure by engaging a 6F Judskin guiding catheter to the LMCA ostium, after that a floppy guidewire was crossed through the first diagonal another floppy guidewire was crossed through the distal LAD stent successfully, we predilated the lesion in the first diagonal branch by using a 2x12 mm balloon and then we planned to implant a 2,5x21 mm Firehawk DES to residue lesion.

while inflating the stent balloon we recognized a dye leakage and we observed that the stent was not expanding successfully (figure 1). we performed the stent boost technique to evaluate the expansion of the stent, we observed that only the head and the end portions of the stent were inflated and the middle portion was unable to inflate correctly (figure 2).

we planned to pull the ruptured balloon of the stent and to inflate a 1,25x12 mm PTCA, 2x15mm PTCA, 2,5x15 mm NC respectively in the unexpanded part of the stent.

But while trying to pull the balloon we noticed that the struts of the stent were moving backwards with the balloon so we decided to pull the stent back from the coronary tree, because the head of the stent was expanded we could not take the stent back into the catheter and because the risk of stent loss we pulled all of the equipment back while keeping the stent struts attached to the tip of the catheter. The stent was removed from the patient without any dissection or perforation.

After that we engaged an EBU 3.5 catheter to the LMCA and we successfully implanted a 2,25x19 mm FIREHAWK DES to the first diagonal and a 2,75x13 mm FIREHAWK DES to the distal LAD and the procedure was performed with a TIMI-3 flow in the LAD and first diagonal.

Rare complications such as stent loss, stent fracture and stent deformity may occur during PCI. we experienced a rare complication of the rupture of the stent balloon and managed it properly.

a reasonable explanation of in our case is that the balloon was ruptured from the middle part as the head and end parts of the stent were expanded correctly but the middle part was unable to expand.

**Keywords:** PTCA, PCI, NSTEMI, DES, STENT LOSS

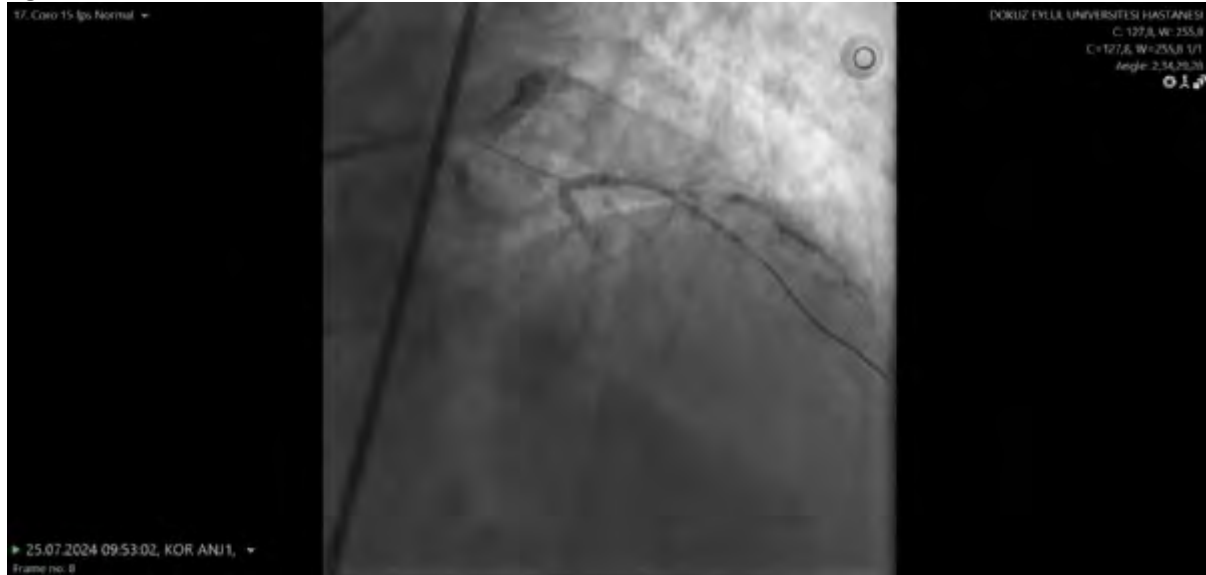

# KARDİYOVASKÜLER AKADEMİ KONGRESİ

## & INTERNATIONAL ACADEMY OF YOUNG CARDIOLOGISTS

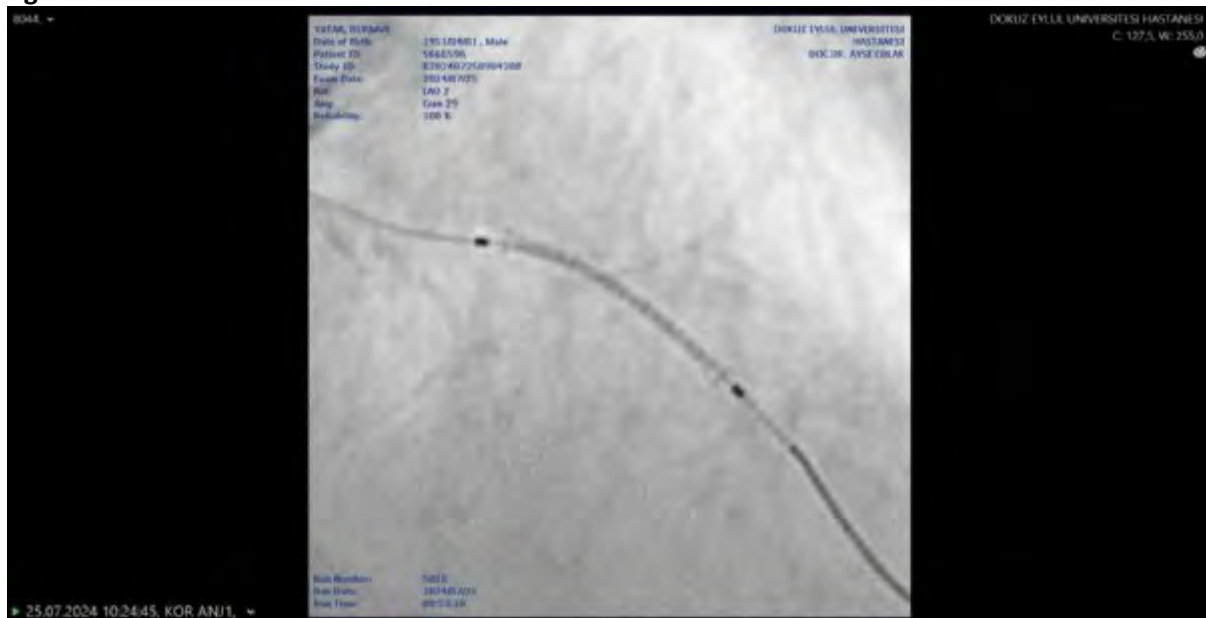Elexus Hotel Girne, K.K.T.C.  
18-22 Eylül 2024

figure 1



*dye leakage while inflating the stent balloon*

figure 2



*stent boost*





# KARDİYOVASKÜLER AKADEMİ KONGRESİ

## & INTERNATIONAL ACADEMY OF YOUNG CARDIOLOGISTS

Elexus Hotel Girne, K.K.T.C.  
18-22 Eylül 2024

### [PP-13] Aortic Dissection Complicated by Inferior Myocardial Infarction

Ayşegül Ülgen Kunak, Batuhan Topçuoğlu, Şakir Arslan

*Department of Cardiology, University of Health Sciences, Antalya Training and Research Hospital*

**Case Report:** A 48-year-old male presented to the emergency department with acute onset of severe, ripping chest pain radiating to the back and abdomen. The pain was associated with lightheadedness and dyspnea. The patient had a history of poorly controlled hypertension. The patient's blood pressure was 140/80 mmHg (right arm), 135/80 mmHg (left arm) and heart rate was 72 beats per minute. Physical examination revealed a diastolic murmur over the left sternal border suggestive of aortic regurgitation. The ECG showed ST-segment elevation in leads II, III, and aVF, indicating an inferior ST-elevation myocardial infarction. There was also evidence of reciprocal changes in leads I and aVL (Figure 1) Transthoracic echocardiography revealed an enlarged ascending aorta approximately 5,9 cm and dissection flap in ascending aorta with signs of severe aortic regurgitation (Figure 2) CT angiography confirmed a type A aortic dissection extending from the ascending aorta to the aortic arch (Figure 2). The right coronary artery (RCA) was involved in the dissection, consistent with the inferior myocardial infarction. The patient underwent emergency surgery including replacement of ascending aorta with a synthetic graft, aortic valve replacement and aorta-saphenous vein-RCA by-pass grafting. The patient experienced series of postoperative complications as persistent hemodynamic instability despite aggressive management, severe renal impairment requiring dialysis and multiorgan failure. Despite intensive care support and surgical efforts, the patient died 48 hours post-surgery.

**Discussion:** Aortic dissection can present with acute chest pain and may be complicated by myocardial infarction if the dissection involves the coronary arteries. This case emphasizes the importance of rapid diagnosis and intervention. Early identification through imaging and prompt surgical management are crucial in improving patient outcomes in such complex presentations. And also this case highlights the severe complexity and high mortality associated with aortic dissection and acute myocardial infarction.

**Conclusion:** The death of this 48-year-old male underscores the critical nature of aortic dissection and acute myocardial infarction. Despite appropriate diagnostic and therapeutic interventions, the condition's severity and postoperative complications led to a fatal outcome. This case emphasizes the need for prompt and comprehensive management of aortic dissection and myocardial infarction, as well as the importance of addressing underlying risk factors and considering the high risk of postoperative complications in similar cases.

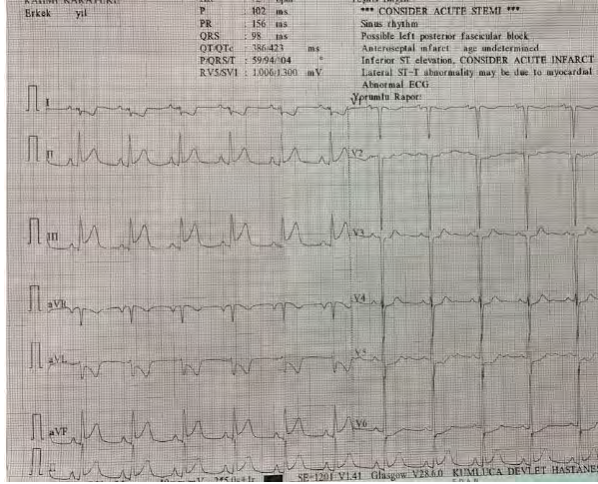
**Keywords:** aortic dissection, echocardiography, myocardial infarction

# KARDİYOVASKÜLER AKADEMİ KONGRESİ

## & INTERNATIONAL ACADEMY OF YOUNG CARDIOLOGISTS

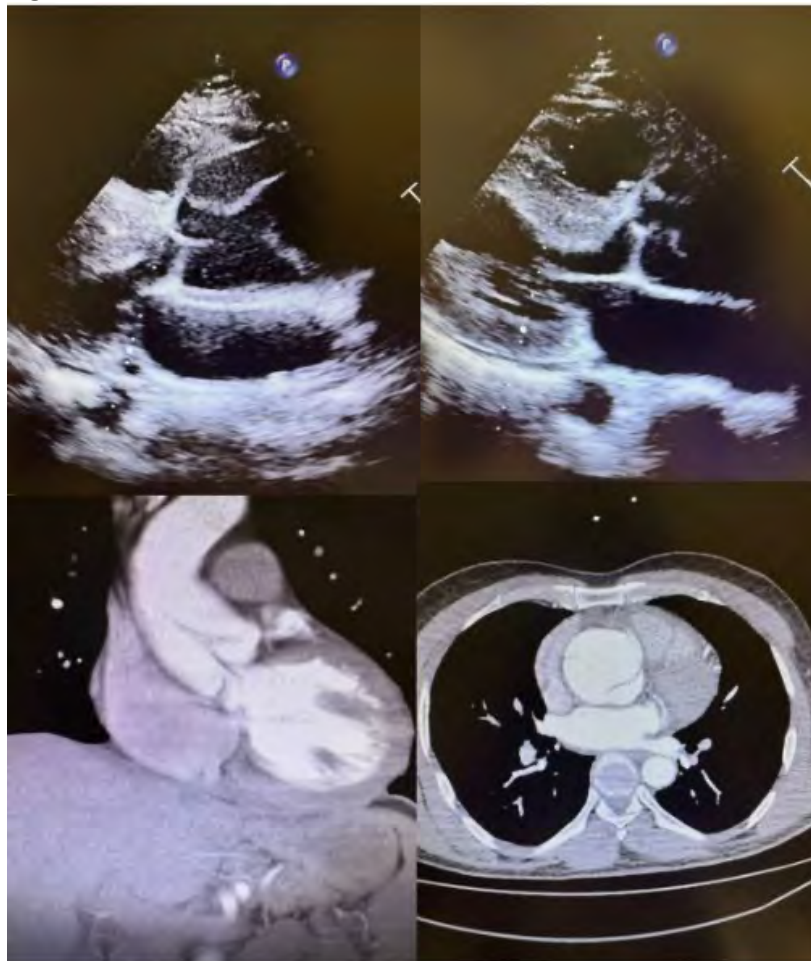
Elexus Hotel Girne, K.K.T.C.  
18-22 Eylül 2024

Figure 1



ECG indicating inferior STEMI

Figure 2



*TTE and CT angiographic findings*



**KARDİYOVASKÜLER**  
AKADEMİ DERNEĞİ

info@kvakademi.org

**GENX**  
KONGRE

GenX Turizm

İcadiye Cd No: 3 Kuzguncuk 34674 İstanbul  
Tel : +90 216 310 11 00 Faks : +90 216 310 06 00  
www.genx.com.tr - kardiyovaskuler@genx.com.tr